



# JPMMA

Journal of the  
Pakistan Medical Association (Centre)

Volume 74 No. 3 Supplement -3 March - 2024 Pages S1 - S212



## GLOBAL NEURO-ONCOLOGY (GNO)





# JPMA

Journal of the  
Pakistan Medical Association (Centre)

## Editorial Board

### Chairman

Shahid Ahmed Sami

### Editor-in-Chief

Fatema Jawad

### Associate Editor-in-Chief

Huma Qureshi

### Associate Editors

Qudsia Anjum Fasih

Sina Aziz

Syed Muhammad Mubeen

### Editor Students' Corner

Maryam Farooqui

### Statistical Reviewer

Syed Muhammad Zulfiqar Hyder Naqvi

### Managing Secretary

Anwar Ali Khawaja

### Administrative Secretary

Ahmed Abdul Majid

## MEMBERS

Aamir Raof Memon  
Aamna Hassan  
Aisha Mehnaz  
Ali Yawar Alam  
Anwar Ali Siddiqui  
Asif Khaliq  
A.R. Jamali  
Bushra Shirazi  
Farooq Azam Rathore  
Fehmina Arif  
Gulnaz Khalid  
Muhammad Iqbal Afridi  
Khalid Zafar Hashmi  
Kiran Ejaz  
Manzoor Hussain  
Masood Ali Shaikh  
Mehwish Kashif

Mirza Naqi Zafar  
Mohammad Wasay  
Muhammad Shahzad Shamim  
Syeda Nosheen Zehra Zaidi  
Ramsha Zaheer  
Rehman Siddiqui  
Rubina Naqvi  
Rumina Hasan  
Sadiah Ahsan  
Muhammad Shahid Shamim  
Syed Sharaf Ali Shah  
Sohail Akhtar  
Syed Mamun Mahmud  
Uzma Fasih  
Zakiuddin G. Oonwala  
Zubaida Masood

## INTERNATIONAL ADVISORS

Ahmed Badar (KSA)  
Amin Ali Muhammad Gadit (CANADA)  
Farhad Handjani (IRAN)  
Farrokh Habibzadeh (IRAN)  
Gerry Mugford (CANADA)  
Itrat Mehdi (OMAN)  
MEL Heyman (USA)  
Mohammad Bagher Rokni (IRAN)  
Mubeen Rafay (CANADA)

Mihnea Alexandru Gaman (ROMANIA)  
Osman Faruk Bayramlar (TURKIYE)  
Sanjay Kalra (INDIA)  
Shabih Zaidi (UK)  
Sultan Ayoub Meo (KSA)  
Tanveer Azher (CANADA)  
Tahir Masood (KSA)  
Zohra Zaidi (UK)

Articles published in JPMA do not represent the views of the Editor or Editorial Board.  
Authors are solely responsible for the opinions expressed and accuracy of the data.

The Journal of Pakistan Medical Association (JPMA) is published monthly from PMA House, Aga Khan III Road, Karachi-74400, Pakistan.

All articles published represent the opinion of the authors and do not reflect official policy of the journal. All rights reserved to the Journal of the Pakistan Medical Association. No part of the Journal may be reproduced, stored in a retrieval system, or transmitted in any form or by any other means, electronic, mechanical photocopying, recording or otherwise, without prior permission, in writing, of the Journal of the Pakistan Medical Association.

**Price:** Rs.2200/- (Single Issue)

**Annual Subscription:** 26,000/- in Pakistan and US\$500.00 for overseas countries (including air mail postage).

**Publication Office:** PMA House, Aga Khan III Road, Karachi-74400, Pakistan. Telephone: 92-21-32226443.

**E-mail:** editor@jpma.org.pk

## EDITORIAL

**Special supplement: global neuro-oncology**

Syed Ather Enam, Hafiza Fatima Aziz, Kaynat Siddiqui, Mohammad Hamza Bajwa, Faiza Urooj, Saqib Kamran Bakhshi, Ahsan Ali Khan, Kee B. Park, Tariq Khan

S-2

## OPINION ARTICLES

## RESEARCH ARTICLE

**Developing a non-cadaveric brain tumour surgery lab in resource-constrained settings**

Ahsan Ali Khan, Mohammad Hamza Bajwa, Fatima Gauhar, Saqib Kamran Bakhshi, Abdul Muqet, Saleem Sayani, Izza Tahir, Faiza Urooj, Muhammad Usman Khalid, Syed Ather Enam

S-3

## RESEARCH ARTICLE

**Protocol: revolutionizing central nervous system tumour diagnosis in low- and middle-income countries: an innovative observational study on intraoperative smear and deep learning**

Muhammad Shakir, Ahmed Altaf, Mahnoor Tariq, Ahmed Gilani, Ihsan Ullah, Faiza Urooj, Fatima Suleman, Noman Ahmed, Syed Ather Enam

S-8

## NARRATIVE REVIEW

**Global neuro-oncology: what lies ahead for low- and middle- income countries?**

Syed Ather Enam, Kee B. Park, Naureen Mushtaq, Muhammad Faraz Raghbir, Fatima Mustansir, Mashal Murad Shah, Mohammad Hamza Bajwa, Minhal Faisal, Michael C. Dewan, Tariq Khan, Jack P. Rock

S-16

**Role of neurosurgeons in strengthening paediatric neuro-oncology in low- and middle-income countries: a narrative review with case examples**

Ahsan Ali Khan, Mohammad Hamza Bajwa, Naureen Mushtaq, Muhammad Osama, Afia Arif, Saqib Kamran Bakhshi, Michael C. Dewan, Kee B Park, Eric Bouffet, Syed Ather Enam

S-24

**Serum liquid biopsy for brain tumours: a scoping analysis of practicable approaches in low- and middle-income countries**

Mohammad Hamza Bajwa, Muhammad Awais Khan, Faiza Urooj, Muhammad Usman Khalid, Syed Ather Enam, Hafiza Fatima Aziz, Kaynat Siddiqui, Mohammad Ehsan Bari, Nouman Mughal

S-30

## SCOPING REVIEW

**Use of artificial intelligence and radio genomics in neuroradiology and the future of brain tumour imaging and surgical planning in low- and middleincome countries**

Faiza Urooj, Aimen Tameezuddin, Zaira Khalid, Kiran Aftab, Mohammad Hamza Bajwa, Kaynat Siddiqui, Saqib Kamran Bakhshi, Hafiza Fatima Aziz, Syed Ather Enam

S-51

**Developing neuro-oncology clinical trials in low- and middle-income countries: a scoping review of the current literature**

Mohammad Hamza Bajwa, Faiza Urooj, Hafiza Fatima Aziz, Ahsan Ali Khan, Kaynat Siddiqui, Rabeet Tariq, Muhammad Shakir, Muhammad Ehsan Bari, Syed Ather Enam

S-64

## SPECIAL COMMUNICATION

**The need for economic evaluations for neuro-oncology in low- and middle-income countries: the Pakistan perspective**

Mashal Murad Shah, Mohammad Hamza Bajwa, Muhammad Usman Khalid, Faiza Urooj, Kaynat Siddiqui, Muhammad Waqas Saeed Baqai, Ahsan Ali Khan, Hafiza Fatima Aziz, Syed Ather Enam

S-82

**A guideline on guidelines – neuro-oncology guideline standards for low- and middle-income countries**

Mohammad Hamza Bajwa, Mashal Murad Shah, Fatima Mustansir, Fatima Gauhar, Erum Baig, Syed Nabeel Zafar, Kaynat Siddiqui, Hafiza Fatima Aziz, Syed Ather Enam

S-87

## GUIDELINE ARTICLES

## NARRATIVE REVIEW

**Consensus guidelines for the management of adult low-grade gliomas for low- and middle-income countries**

Ahsan Ali Khan, Ayesha Akbar Waheed, Ali Azan Ahmed, Asim Hafiz, Adeeba Zaki, Ahmed Gilani, Faiza Urooj, Mohammad Hamza Bajwa, Pakistan Brain Tumour Consortium: (Authors list at the end of the supplement), Syed Ather Enam

S-93

**Consensus guidelines for the management of adult high-grade gliomas for low- and middle-income countries**

Syed Ather Enam, Hafiza Fatima Aziz, Saqib Kamran Bakhshi, Ahmed Altaf, Kaynat Siddiqui, Asim Hafiz, Adeeba Zaki, Muhammad Osama, Ahmed Gilani, Pakistan Brain Tumour Consortium: Authors list at the end of the supplement

S-100

**Consensus guidelines for the management of vestibular schwannoma for low- and middle-income countries**

Syed Ather Enam, Muhammad Shakir, Ahsan Ali Khan, Muniba Tahir, Kaynat Siddiqui, Muhammad Shahzad Shamim, Mohammad Hamza Bajwa, Asim Hafiz, Ahmed Gilani, Faiza Urooj, Pakistan Brain Tumour Consortium: Authors list at the end of the supplement

S-109

**Consensus guidelines for the management of pediatric medulloblastoma in low- and middle-income countries**

Naureen Mushtaq, Syed Ather Enam, Mohammad Hamza Bajwa, Fatima Mustansir, Erum Baig, Fatima Gauhar, Afia Arif, Ahsan Ali Khan, Syed Ahmer Hamid, Gohar Javed, Fatima Mubarak, Bilal Mazhar Qureshi, Khurram Minhas, Salman Kirmani, Shahzadi Resham, Asif Bashir, Irfan Yousaf, Ahmed Gilani, Eric Bouffet, Pakistan Brain Tumour Consortium: (Authors list at the end of the supplement)

S-116

**Consensus guidelines for the management of craniopharyngioma in low- and middle-income countries**

Syed Ather Enam, Naureen Mushtaq, Muhammad Usman Khalid, Mohammad Hamza Bajwa, Ahsan Ali Khan, Sehar Salim Verani, Anam Tariq, Ahmed Gilani, Bilal Mazhar Qureshi, Pakistan Brain Tumour Consortium: Authors list at the end of the supplement

S-126

**Consensus guidelines for the management of pineal region tumours for low- and middle-income countries**

Saqib Kamran Bakhshi, Naureen Mushtaq, Rabeet Tariq, Moeez Tariq, Asim Hafiz, Ahmed Gilani, Hafiza Fatima Aziz, Muhammad Shahzad Shamim, Altaf Ali Laghari, Kaynat Siddiqui, Syed Ather Enam Pakistan Brain Tumour Consortium: Authors list at the end of the supplement

S-135

**Consensus guidelines for the management of intracranial ependymoma for low- and middle-income countries**

Ahsan Ali Khan, Muhammad Usman Khalid, Mohammad Hamza Bajwa, Izza Tahir, Shahier Paracha, Muhammad Shakir, Bilal Mazhar Qureshi, Naureen Mushtaq, Ahmed Gilani, Pakistan Brain Tumour Consortium: (Authors list at the end of the supplement), Syed Ather Enam

S-145

**Consensus guidelines for the management of intracranial meningioma for low- and middle-income countries**

Syed Ather Enam, Mehar Masroor, Saqib Kamran Bakhshi, Fatima Shaukat, Hafiza Fatima Aziz, Kaynat Siddiqui, Mohammad Hamza Bajwa, Muhammad Shakir, Rabeet Tariq, Altaf Ali Laghari, Pakistan Brain Tumour Consortium: Authors list at the end of the supplement

S-152

**Consensus guidelines for the management of brain stem and diffuse midline glioma for low- and middle-income countries**

Hafiza Fatima Aziz, Naureen Mushtaq, Fatima Suleman, Asim Hafiz, Mohammad Hamza Bajwa, Ahmed Gilani, Kaynat Siddiqui, Altaf Ali Laghari, Muhammad Usman Khalid, Saqib Kamran Bakhshi, Syed Ather Enam Pakistan Brain Tumour Consortium: (Authors list at the end of the supplement), **S-159**

**Consensus guidelines for the management of primary central nervous system lymphoma for low- and middle-income countries**

Hafiza Fatima Aziz, Saqib Kamran Bakhshi, Noman Ahmed, Mohammad Hamza Bajwa, Adnan Abdul Jabbar, Asim Hafiz, Ahmed Gilani, Muhammad Usman Khalid, Pakistan Brain Tumour Consortium: (Authors list at the end of the supplement), Syed Ather Enam **S-168**

**Consensus guidelines for the management of intracranial metastases for low- and middle-income countries**

Hafiza Fatima Aziz, Saqib Kamran Bakhshi, Zanib Javed, Asim Hafiz, Adeeba Zaki, Kaynat Siddiqui, Ahsan Ali Khan, Mohammad Hamza Bajwa, Pakistan Brain Tumour Consortium: (Authors list at the end of the supplement), Syed Ather Enam **S-177**

**Consensus guidelines for the management of posterior fossa tumour for low- and middle-income countries**

Hafiza Fatima Aziz, Mohammad Hamza Bajwa, Naureen Mushtaq, Saqib Kamran Bakhshi, Kaynat Siddiqui, Saad Akhtar Khan, Rabeet Tariq, Muhammad Shakir, Mehar Masroor, Fatima Suleman, Pakistan Brain Tumour Consortium: (Authors list at the end of the supplement), Syed Ather Enam **S-186**

**Consensus guidelines for the management of primary supra-tentorial intraventricular tumour for low- and middle-income countries**

Hafiza Fatima Aziz, Saqib Kamran Bakhshi, Rabeet Tariq, Muhammad Waqas Saeed Baqai, Mohammad Hamza Bajwa, Kaynat Siddiqui, Zanib Javed, Ahsan Ali Khan, Muhammad Shakir, Pakistan Brain Tumour Consortium: (Authors list at the end of the supplement), Syed Ather Enam **S-191**

## SCOPING REVIEW

**Judicious and evidence-based use of radiosurgery - recommendations for low- and middle income countries**

Syed Ather Enam, Faiza Urooj, Kaynat Siddiqui, Mohammad Hamza Bajwa, Hafiza Fatima Aziz, Fatima Shaukat, Muhammad Waqas Saeed Baqai, Muhammad Shakir, Ahsan Ali Khan, Pakistan Brain Tumour Consortium: Authors list at the end of the supplement **S-201**

## AUTHORS NAME

**Pakistan Brain Tumor Consortium (PBTC) **S-212****

## ACKNOWLEDGEMENT

We are delighted to present this special supplement on Global Neuro-Oncology (GNO) to our esteemed readers. This collection, comprising 23 meticulously selected articles, embodies not only a comprehensive set of guidelines for managing prevalent brain tumour types in Pakistan but also serves as a pioneering blueprint for optimizing care in low- and middle-income regions. This initiative marks a significant milestone as Pakistan's inaugural compendium for brain tumour management. The articles within this supplement are destined to become seminal references, offering an extensive array of recommendations and insights for the management of various brain tumour types.

The manuscripts in this supplement shed light on the intricate, global landscape of brain tumour management. Recognizing the multifaceted nature of the treatment, involving a spectrum of specialists including Medical Oncologists, Radiation Oncologists, Paediatric Medicine experts, Neurosurgeons, Neurologists, Palliative Care professionals, Histopathologists, Geneticists, and Neuro-radiologists, we prioritized the inclusion of diverse, expert perspectives. The dynamic and evolving field of neuro-oncology demanded inputs from multiple specialists, sometimes even multiple experts within a single speciality, including contributions from international authorities.

We, the editorial board, wish to express our profound gratitude to the members of the Pakistan Brain Tumour Consortium. The opportunity to integrate the wealth of knowledge and experience from each member is a privilege we deeply appreciate. We aim to pave the way for further national and international collaborations in the sphere of global neuro-oncology.

Our heartfelt thanks go to the dedicated GNO committee members whose relentless pursuit of excellence has culminated in the creation of publications of the highest quality and impact. This ambitious endeavour, fuelled by their unwavering perseverance and commitment, would not have been possible without the staunch support and herculean efforts of our committee members. Also, this immense undertaking would not have been possible without the managerial support of Mr. Shariff Charania. Above all, our deepest sense of gratitude is reserved for the patients grappling with neuro-oncological conditions, whose courage and resilience inspire us.

Our vision extends beyond presenting these guidelines; we aspire to elevate the standards of neuro-oncology care and research, particularly in settings constrained by resources. The collective contributions of everyone involved in this supplement are pivotal to our clinical research, igniting a spirit of relentless determination that propels us forward.

We invite you to immerse yourself in this enriching compilation.

Wishing you an insightful journey through these pages.

**With gratitude,**

Publication Committee  
Global Neuro-Oncology (GNO)

## Special Supplement: Global Neuro-Oncology

Syed Ather Enam, Hafiza Fatima Aziz, Kaynat Siddiqui, Mohammad Hamza Bajwa, Faiza Urooj, Saqib Kamran Bakhshi, Ahsan Ali Khan, Kee B. Park, Tariq Khan

In this special supplement of the Journal of Pakistan Medical Association, titled "Global Neuro-Oncology (GNO)," we expand upon the Pakistan Brain Tumour Epidemiological Study's (PBTES) foundational work.<sup>1</sup> This edition is dedicated to addressing the critical challenges in global neuro-oncology, with roots in global oncology and global surgery, as emphasized in leading publications like *The Lancet*.<sup>2</sup> It highlights the urgency of tackling brain tumours, the 10th leading cause of mortality worldwide, with a particular focus on low- and middle-income countries (LMICs) where healthcare disparities are most acute.

Our supplement enriches the dialogue initiated by the PBTES, providing a comprehensive epidemiological framework that deepens our understanding of brain tumour patterns in Pakistan. We go beyond these insights by including a series of opinion articles and 15 guideline papers that resonate with the broader issues in global oncology. These contributions not only echo the challenges discussed in leading global surgery platforms but also bridge the gap between theoretical understanding and practical healthcare implementation in LMICs.

The opinion pieces offer multifaceted perspectives on clinical, socioeconomic, and infrastructural challenges in LMICs. They serve as a conduit between the PBTES's data-driven insights and the on-ground realities of implementing effective neuro-oncology practices in resource-constrained settings.

The heart of this supplement is the guideline papers. These guidelines translate the PBTES's epidemiological data into actionable strategies for brain tumour management. They emphasize equity and accessibility in healthcare, mirroring global oncology and global surgery discussions, and provide a roadmap for overcoming barriers in neuro-oncological care, focussing on scalable and sustainable solutions. These guidelines form part of a larger narrative in global health, addressing disparities in care and outcomes and offering a holistic approach to neuro-oncology that considers the diverse needs of LMICs.

These opinion and guideline papers, informed by

comprehensive research, advocate for a holistic approach to brain tumour management that spans early detection to long-term support. They emphasize equitable access to quality care, addressing a significant challenge in global health.

The strength and credibility of these guideline papers are notably enhanced by the endorsement from members of the "Pakistan Brain Tumour Consortium (PBTC)." A group of expert panel lists from the PBTC rigorously discussed and vetted each guideline. Every aspect, including the pros and cons, was meticulously examined to achieve a consensus. This collaborative process ensures that the guidelines are not only deeply informed but also broadly representative of the field's current best practices.

Additionally, this GNO supplement paves the way for the imminent release of "Comprehensive Health Systems Policy Recommendations for the Management of Brain Tumours in LMICs." These recommendations, drawing from the latest research and clinical insights specific to brain tumour management in LMICs, aim to coalesce into a strategy that is acutely attuned to the distinct challenges faced in these regions. By integrating cutting-edge knowledge with a deep understanding of local contexts, the recommendations promise to deliver nuanced, practical approaches that effectively address the unique healthcare landscapes of LMICs.

These upcoming recommendations, currently under development, are pivotal. They acknowledge LMICs' resource and infrastructure limitations, bridging the gap between research and practical application. This ensures that the guidelines are evidence-based, realistic, and implementable in diverse settings. They also embody a collaborative spirit, drawing on expertise from various neuro-oncology, research, and healthcare backgrounds, crucial for inclusivity and reflecting diverse experiences and needs within LMICs.

This GNO supplement is more than a scholarly collection; it's a call to action for the global medical community to address neuro-oncology challenges in LMICs. Inspired by the PBTES, which was accomplished successfully due in large part to the involvement of the PBTC, and informed by ongoing global health discourse, it fosters a more

equitable and effective approach to brain tumour management worldwide. The PBTC's role is pivotal, reflecting a collaborative spirit that draws on diverse expertise in neuro-oncology, research, and healthcare. Their involvement in developing and endorsing the guidelines reinforces our message, ensuring that our approach is inclusive, evidence-based, and reflective of diverse experiences and needs within LMICs.

We acknowledge the evolving nature of brain tumour management and socioeconomic changes in LMICs. Thus, we commit to regularly updating our guidelines to align with the latest global knowledge and adapt treatments to local conditions without compromising standards. The PBTC's ongoing involvement in this process is crucial, as their expertise and insights will continue to inform and refine our strategies. This ensures that our supplement remains dynamic and responsive to the changing landscape of global neuro-oncology, ultimately leading to

better outcomes for brain tumour patients across LMICs.

In conclusion, this supplement, a collaborative effort with the PBTC, builds upon the PBTES research and aligns with broader global oncology and surgery goals. Our combined efforts aim to inform, inspire action, and improve outcomes for brain tumour patients across LMICs, showcasing the power of partnership in addressing complex health challenges.

**DOI: <https://doi.org/10.47391/JPMA.S3.GNO-01>**

### References

1. Enam SA, Shah MM, Bajwa MH, Khalid MU, Bakhshi SK, Baig E, et al. The Pakistan Brain Tumour Epidemiology Study. *J Pak Med Assoc.* 2022;72(Suppl 4)(11):S4-s11.
2. Meara JG, Leather AJ, Hagander L, Alkire BC, Alonso N, Ameh EA, et al. Global Surgery 2030: evidence and solutions for achieving health, welfare, and economic development. *The Lancet.* 2015;386:569-624.

---

#### DISCLAIMER

Articles published in JPMA and Supplements of JPMA do not represent the views of the editor or editorial Board. Authors are solely responsible for the opinions expressed and the accuracy of the data.

The contribution of each author towards the published research included in this supplement is the responsibility of the authors and their institutions. It is expected to be in accordance and compliance with the ICMJE Guidelines.

Any questions/queries raised by readers should be directed to the corresponding author.



## Developing a non-cadaveric brain tumour surgery lab in resource-constrained settings

Ahsan Ali Khan<sup>1</sup>, Mohammad Hamza Bajwa<sup>2</sup>, Fatima Gauhar<sup>3</sup>, Saqib Kamran Bakhshi<sup>4</sup>, Abdul Muqteet<sup>5</sup>, Saleem Sayani<sup>6</sup>, Izza Tahir<sup>7</sup>, Faiza Urooj<sup>8</sup>, Muhammad Usman Khalid<sup>9</sup>, Syed Ather Enam<sup>10</sup>

### Abstract

**Objective:** To develop the country's first brain tumour surgery lab in resource-constrained settings, for training young neurosurgeons and residents.

**Methods:** A workshop was developed using mixed-fidelity models for assessing and training a participant's psychomotor skills, hand-eye coordination, and teaching the principles of brain tumour surgery. Affordable non-cadaveric models were used to compare and contrast the benefit of each teaching model. Within the existing space for wet labs at our institution, 8 different dissection stations were set up with adequate space for 2 people to work at a time. Each station was equipped with an operating room-Caliber microscope, a lighting system and a camera linked to a screen and high-powered electric drills and basic surgical equipment.

**Results:** Our team was able to develop and use 3D-printed skull models and animal brain models for training in complex approaches and craniotomy.

**Conclusion:** Surgical simulation training, in a cost-effective manner, provides the benefit of training residents and students in neurosurgical techniques in a safe, controlled environment leading to improvement in skills and technique.

**Keywords:** Neurosurgery, surgical oncology, simulation training, Brain Neoplasms, Craniotomy, Skull (JPMA 74: S-3; 2024) DOI: <https://doi.org/10.47391/JPMA.S3.GNO-02>

### Introduction

The Accreditation Council for Graduate Medical Education (ACGME) tracks the progress of neurosurgical residents using the volume-outcomes model; the number of procedures performed is correlated with improved training and ultimately, patient outcomes.<sup>1</sup> Technical proficiency is imparted through real-world experience and competency-based programmes. As these skill sets mature, residents are expected to take on more responsibilities in the operating room (OR) in order to become independent surgeons.<sup>2</sup> Most neurosurgery residency programmes all over the world follow this approach.

The master-apprentice system of consultants teaching procedures newly-graduated surgical trainees on patients hampers the quality and safety standards of a healthcare centre. In the modern era of neurosurgery, there are greater limitations in place to protect patients and improve outcomes. In order to continue surgical education in line with current restrictions and standards,

.....  
<sup>1,2,4,9,10</sup>Department of Neurosurgery, The Aga Khan University, Karachi, Pakistan. <sup>3,7,8</sup>The Aga Khan Medical College and University, Karachi, Pakistan. <sup>5,6</sup>Technology Innovation Support Centre, The Aga Khan University Hospital, Karachi, Pakistan

**Correspondence:** Syed Ather Enam **Email:** [ather.enam@aku.edu](mailto:ather.enam@aku.edu)

anatomical and surgical skills labs in neurosurgery have been developed as link to the volume-outcomes model and accelerate residents through the required learning curve.<sup>3,4</sup> Residents are able to master anatomical nuances and approaches, for example through skull base and micro neurosurgery labs, in controlled environments before being given the opportunity to develop further competencies in the operating room.<sup>5,6</sup> This includes cadaveric simulations and the use of operating room tools and microscopes for near-perfect surgical simulation. Simulations allow surgical trainees to practice, make errors and learn without negatively impacting any patients. In a safe setting, this practice builds confidence as young neurosurgeons polish their psychomotor skills. Many companies have even developed non-cadaveric virtual simulators and virtual reality applications for further training in settings where ethical access to cadavers is not available.<sup>7</sup>

The transferability of the volume-outcomes model to resource-constrained settings is difficult. Within our own centre and experience, issues have been faced in residents' case numbers and developing clinical independence, as is similar in programmes across the world.<sup>8</sup> The COVID-19 pandemic has only widened this gap in resident education and digital platforms are being employed as a solution.<sup>9,10</sup> Digital didactic lectures and

conferences are not sufficient for developing hand-eye coordination and neurosurgical skills that are the cornerstone of residency. The solution is investing in neurosurgical labs in low-and middle-income countries (LMICs). Investing in Simulation-Based Training (SBT), low- or high-fidelity, permits surgical residents to perfect their abilities through milestone achievements on the learning curve. At this current time, Virtual Reality (VR) high fidelity systems are unsustainable in LMICs as the costs outweigh any foreseeable returns.<sup>10</sup> Therefore, in resource-constrained settings, we developed the country's first brain tumour surgery lab for the training of young neurosurgeons and residents. We hope to build on our current model in order to improve the quality of neurosurgical training in LMICs.

## Methods

It is with this dilemma in mind that our centre developed the country's first brain tumour surgery lab (BTSL) at the Aga Khan University Hospital, Karachi, with a pilot training module for young neurosurgical residents and aspiring medical students. Our focus was primarily non-cadaveric training with graduated levels of complexity. This ensured skills assessment, supervision, and feedback for the participant. Using the existing space for wet labs at our institution,<sup>8</sup> different dissection stations were set up with adequate space for 2 people to use at a time. Each station was equipped with ample space as shown, an operating room-Caliber microscope, and a lighting system, equipped with a camera that linked to a screen at every

station. This allowed us to teach various procedures and microscopic techniques to all members of the group. High-powered electric drills and basic surgical equipment was provided at every station (Video 1).

With a focus on brain tumour surgery, a curriculum was developed for both medical students interested in neurosurgery and neurosurgery residents, with recommended reading and references to "Getting Ready for Brain Tumour Surgery" by Michael Sabel.<sup>11</sup> The junior curriculum focused on skull anatomy, surgical techniques and approaches in neuro-oncology, orientation to surgical tools, and interpretation of CT/MRI scans for brain tumours. The senior curriculum was tailored to focus on advanced craniotomy approaches and micro neurosurgical techniques. After initial didactic sessions, groups would be advanced to dissection tables. Dissection models and sessions were developed using non-cadaveric prototypes, with the addition of our innovation: three-dimensional (3D) printed skulls, produced locally at cost-effective rates (Figure 1).

## Results

### Day 1: Coconuts as a prototype for skull craniotomy

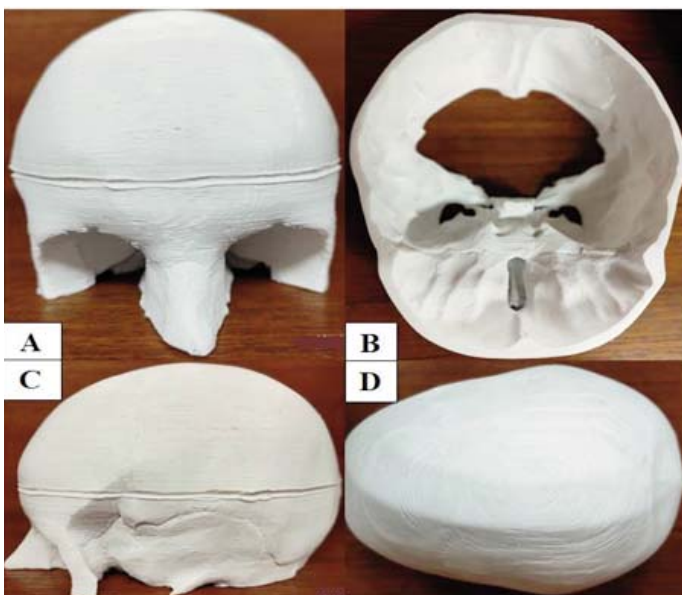
Participants were each given ample opportunities to practice and demonstrate basic burr hole procedures on the coconut followed by completion of the 'craniotomy' by use of high-powered drills, similar to the ones used on skulls. Coconuts proved to be adequate models for craniotomy training. Once the shell was pierced, the underlying soft texture would cause the drill to automatically disengage, as is seen when using these drills on real patients. However, the outer shell was more difficult to pierce than the calvarium when using high-powered drills in an OR setting. This comparable experience was incredibly useful in a low-fidelity model.

### Day 1: Capsicums as a model for microsurgical techniques

Participants were given tasks to use micro dissectors and micro-forceps on capsicums under an operating microscope. The 'operating surgeon' had to delicately dissect individual targets (capsicum seeds) from their roots without causing damage to adjacent 'tissue', and retrieve it successfully – thus simulating brain tumour resection and dissection. Microsurgical suturing was also taught and practiced on surgical gauze, under the microscope.

### Day 2: 3-Dimensional (3D) printed skulls for craniotomy

After graduating from low-definition models,



**Figure:** 3D printed skull model, (A) frontal view, (B) axial cross-section, (C) lateral view, (D) superior view.

participating students and residents were given 3D printed skull models that were developed to specifications almost perfectly similar to the human skull. Craniotomy and burr hole procedures were elaborated on in the junior curriculum, with attention to approaches in surgical neuro-oncology. Residents were instructed on more complex approaches, with complexities of craniotomy discussed. Groups were given tasks to identify and perform key approaches in craniotomy for brain tumours with evaluation of the performance.

## Day 2: Micro neurosurgery skills on animal (goat) brains

Similarly, groups were then given individual animal models using goat brains that had been kept preserved. Under microscopic vision, key anatomical structures were identified, with attention to major lobes, sulci and gyri, arterial structures, and microsurgical dissection of the brain. Neurosurgery residents were taught and performed corticectomy procedures, dissection of the Sylvian fissure, and approaches to deeper structures of the brain. Microsurgical dissection was practiced.

## Discussion

Surgical training using simulation was a necessary

inspiration from the airline industry teaching their pilots using flight simulators. A study at Yale University showed a remarkable decrease of 30% in operating time and 85% decrease in operative errors by adopting 'criterion-based simulator training'. In today's time, a surgeons' competency is determined by their patient outcomes; better only to be achieved by dedication and diligence. SBTs provide that edge to surgeons by building on their skills.<sup>12</sup>

Our SBT via the brain simulation training lab is a key step in building capacity for surgical training within an LMIC such as Pakistan. As mentioned previously, the ACGME currently requires neurosurgery residents to log 60 "craniotomy for brain tumour" adult population cases where the resident is senior resident surgeon or lead resident surgeon.<sup>1,13</sup> In order to develop the skills necessary for a resident to be able to perform at such a level, they need adequate training in controlled environments that only surgical labs can provide.<sup>14</sup> Our simulation provided gradual development of skills through the use of low-fidelity (coconuts and capsicum model) to high-fidelity (3D printed skulls, animal brains) models of training (Table 1). Residents can be taught complex approaches to cases they may not previously

**Table -1:** Cost-Benefit analysis of simulation models

Model	Cost	Skills assessed	Analysis	Limitations
Coconut	PKR400 (USD 2.48)	Hand-eye coordination with craniotome and electric saw Performing a standard craniotomy		Coconut shells are tougher to penetrate than human skulls Cannot assess if damage done to underlying structures – a key consideration in performing craniotomy
Capsicum/Bell Pepper	PKR100 (USD 0.62)	Fine-movements with hands, hand-eye coordination using instruments, and dexterity under microscope Familiarity with focusing and zooming in with the microscope Principle of the inverted pyramid in micro neurosurgery		Structures are well-defined in capsicum, whereas more difficult to differentiate grossly in cortical brain Does not assess the importance of avoiding nearby vascular structures
3D printed skull	PKR10,000 (USD 61.96)	Advanced craniotomy principles including constructing a bone flap, considerations for individual approaches Complex skull base approaches Principles of keyhole cranial surgery		Relatively higher cost than other models Time required for printing 3D printers may not be widely available at every institute
Animal brain	PKR500 (USD 3.10)	Handling brain tissue with microsurgical instruments Principles of subpial resection and sulcal anatomy		Difference in structures from human brain

have experience with, and hone their technical and surgical awareness before entering the OR. We hope to develop this programme and lab further to include complex skull base approaches and greater use of our 3D printed models.

3D printed skulls that are cost-effective as well as accurate depictions of surgical anatomy can also be used in improving surgical planning and accuracy. Anatomical 3D printed models are useful in-patient education regarding their disease, developing preoperative tactile memory for surgeons, and allowing accurate planning of surgical technique and anticipating challenges before the surgery. It has also been used in surgery as an anatomical reference in avoiding perioperative complications, guiding surgical manoeuvres, and improving patient outcomes.<sup>15</sup>

Participants were given an evaluation form at the end of our workshop for feedback on the organization, execution, and areas needing improvement of our training lab. Pre- and post-workshop skills analysis forms can be used to further objectively identify the benefit of this workshop, strengthening the evidence of setting up more of such workshops at a higher frequency and a bigger level. The use of a modified Objective Structured Assessment of Technical Skills (mOSATS) for neurosurgery skills workshops has been justified in the literature.<sup>16</sup> Our next step will be to establish the benefit of the BTSL through quantitative analysis of participants' skills before and after a workshop.

We hope this will serve as a model for further development of surgical labs in LMICs. Analysing our costs, we can see that the major cost will be in buying a functioning operating microscope. This can be done on a budget as we were able to use older models that have been retired from use. Refurbished drills can be used and can usually be obtained at reduced prices or donated from companies for laboratory use. Drill bits that have been lightly used before can be used as well. Microsurgical instruments for laboratory are generally available at low prices from surgical instrument companies. Coconuts and capsicums were available at market rates. Animal brains were similarly procured from local butcheries and stored in fridges. Our model is more affordable than what is currently used in surgical labs in HICs (higher-income countries). Cadaveric specimen can cost upwards of USD 2500 per specimen with additional shipping costs.<sup>1</sup> Our 3D-printed skull model was also comparatively cheaper to produce in comparison with available models from local companies and online-based producers.

**Table-2:** Summary of recommendations.

- 
- ▶ Low-cost surgical simulations can accentuate the training of neurosurgical residents in basic and advanced skills – these are a major 'link' in developing the independent surgeon in times of greater quality control and patient safety in LMICs.
  - ▶ In resource-constrained settings, there is a dearth of complexity in surgical training which is often difficult to teach and overcome without compromising patient care – residents can have a first-hand, free-hand experience in brain tumour surgery in order to 'jumpstart' the learning curve and get ahead.
  - ▶ 3D-printed skull models are a gateway in developing tactile memory and psychomotor skills for the young neurosurgeon in particular. Surgical strategy of approaches that can be repeated numerous times on an accurate model, as we have shown, can be a key factor in ensuring safe and precise surgical techniques.
  - ▶ Ultimately, our patients will benefit in the developing world – training can move away from 'practice on the patient' models towards controlled-environment, graduated surgical training with a near-perfect simulation allowing transference of skills learnt in the lab to the OR.
- 

## Conclusion

One of the pillars of building neurosurgical capacity in LMICs is training programmes. As studied previously, neurosurgical residencies in resource-constrained settings need a jump-start in order to improve patient outcomes and train the surgeons of tomorrow. We believe that pioneering training approaches such as the brain tumour surgery lab at our institution is the way forward.

**Recommendations:** Summary is shown in Table-2

**Disclaimer:** None.

**Conflict of Interest:** None.

**Funding Disclosure:** None.

## References

1. Agarwal N, White MD, Cohen J, Lunsford LD, Hamilton DK. Longitudinal survey of cranial case log entries during neurological surgery residency training. *J Neurosurg* 2018. doi: 10.3171/2018.2.JNS172734. [ahead of print]
2. Boudourakis LD, Wang TS, Roman SA, Desai R, Sosa JA. Evolution of the surgeon-volume, patient-outcome relationship. *Ann Surg* 2009;250:159-65. doi: 10.1097/SLA.0b013e3181a77cb3.
3. Roberti F, Wind JJ, Perez R, Caputy AJ. The translabyrinthine approach in residency training. "Step by step" surgical anatomy from the dissection laboratory to the operative room. *J Otol* 2021;16:99-108. doi: 10.1016/j.joto.2020.09.002.
4. Oliveira LM, Figueiredo EG. Simulation Training Methods in Neurological Surgery. *Asian J Neurosurg* 2019;14:364-70. doi: 10.4103/ajns.AJNS\_269\_18.
5. Bernardo A. Establishment of Next-Generation Neurosurgery Research and Training Laboratory with Integrated Human Performance Monitoring. *World Neurosurg* 2017;106:991-100. doi: 10.1016/j.wneu.2017.06.160.

6. Pojskić M, Čustović O, Erwin KH, Dunn IF, Eisenberg M, Gienapp AJ, et al. Microscopic and Endoscopic Skull Base Approaches Hands-On Cadaver Course at 30: Historical Vignette. *World Neurosurg* 2020;142:434-40. doi: 10.1016/j.wneu.2020.07.064.
7. Nicolosi F, Spena G. Three-Dimensional Virtual Intraoperative Reconstruction: A Novel Method to Explore a Virtual Neurosurgical Field. *World Neurosurg* 2020;137:e189-93. doi: 10.1016/j.wneu.2020.01.112.
8. Kim DH, Dacey RG, Zipfel GJ, Berger MS, McDermott M, Barbaro NM, et al. Neurosurgical Education in a Changing Healthcare and Regulatory Environment: A Consensus Statement from 6 Programs. *Neurosurgery* 2017;80:s75-82. doi: 10.1093/neuros/nyw146.
9. Bambakidis NC, Tomei KL. Impact of COVID-19 on neurosurgery resident training and education. *J Neurosurg* 2020. doi: 10.3171/2020.3.JNS20965. [ahead of print]
10. Haji FA. Simulation in Neurosurgical Education During the COVID-19 Pandemic and Beyond. *Can J Neurol Sci* 2021;48:152-4. doi: 10.1017/cjn.2020.234.
11. Sabel M. *Getting Ready for Brain Tumour Surgery*, 1st ed. Leipzig, Germany: Thieme; 2017.
12. Coelho G, Zanon N, Warf B. The role of simulation in neurosurgery. *Childs Nerv Syst* 2014;30:1997-2000. doi: 10.1007/s00381-014-2548-7.
13. Accreditation Council for Graduate Medical Education (ACGME). *Neurological Surgery Case Log Defined Case Categories and Required Minimum Numbers*. [Online] 2019 [Cited 2024 March 21]. Available for URL: [https://www.acgme.org/globalassets/pfassets/programresources/160\\_neurological\\_surgery\\_defined\\_case\\_categories\\_and\\_required\\_minimum\\_numbers.pdf](https://www.acgme.org/globalassets/pfassets/programresources/160_neurological_surgery_defined_case_categories_and_required_minimum_numbers.pdf)
14. Liu JK, Kshetry VR, Recinos PF, Kamian K, Schlenk RP, Benzel EC. Establishing a surgical skills laboratory and dissection curriculum for neurosurgical residency training. *J Neurosurg* 2015;123:1331-8. doi: 10.3171/2014.11.JNS14902.
15. Texeira da Silva LEC, Cuéllar DJ, Campos de Barros AG, Khan AA. Three-dimensional biomodel use in the surgical management of basilar invagination with congenital cervical scoliosis; correction by unilateral C1-C2 facet distraction. *J Craniovertebr Junction Spine* 2020;11:347-50. doi: 10.4103/jcvjs.JCVJS\_131\_20.
16. Gough M, Solomou G, Khan DZ, Kamel M, Fountain D, Kumaria A, et al. The evolution of an SBNS-accredited NANSIG simulated skills workshop for aspiring neurosurgical trainees: an analysis of qualitative and quantitative data. *Acta Neurochir* 2020;162:2323-34. doi: 10.1007/s00701-020-04325-6..

---

#### DISCLAIMER

Articles published in JPMA and Supplements of JPMA do not represent the views of the editor or editorial Board. Authors are solely responsible for the opinions expressed and the accuracy of the data.

The contribution of each author towards the published research included in this supplement is the responsibility of the authors and their institutions. It is expected to be in accordance and compliance with the ICMJE Guidelines.

Any questions/queries raised by readers should be directed to the corresponding author.

## RESEARCH ARTICLE

## Protocol: revolutionizing central nervous system tumour diagnosis in low- and middle-income countries: an innovative observational study on intraoperative smear and deep learning

Muhammad Shakir<sup>1</sup>, Ahmed Altaf<sup>2</sup>, Mahnoor Tariq<sup>3</sup>, Ahmed Gilani<sup>4</sup>, Ihsan Ullah<sup>5</sup>, Faiza Urooj<sup>6</sup>, Fatima Suleman<sup>7</sup>, Noman Ahmed<sup>8</sup>  
Syed Ather Enam<sup>9</sup>

### Abstract

**Objective:** : The aim of this study is to assess the feasibility and implementation of a novel approach for intraoperative brain smears within the operating room, which is augmented with deep learning technology.

**Materials and methods:** This study is designed as an observational to evaluate the feasibility and implementation of using an innovative approach to intraoperative brain smears within the operating room, augmented with deep learning technology. The study will be conducted at Aga Khan University Hospital in Karachi, Pakistan, from May 2024 to July 2026, with an estimated sample size of 258. A neurosurgical trainee, trained by the study neuropathologist, will prepare and examine the smears under a microscope in the operating room. The findings of the trainee will be documented and compared to routine intraoperative consultations (smear and/or frozen section) and final histopathology results obtained from the pathology department. Additionally, the study will incorporate artificial intelligence tools to assist with the interpretation of smear and a telepathology interface to enable consultation from an off-site neuropathologist.

**Conclusion:** The results of this study will hold significant potential to revolutionise neurosurgery practices in low- and middle-income countries by introducing a cost-effective, efficient, and high-quality intraoperative consultation method to settings that currently lack the necessary infrastructure and expertise. The implementation of this innovative approach has the potential to improve patient outcomes and increase access to intraoperative diagnosis, thereby addressing a significant unmet need in LMICs.

**Keywords:** Artificial Intelligence, Neuropathology, Neurosurgery, Telepathology, Brain, tumour  
(JPMA 74: S-8 2024) **DOI:** <https://doi.org/10.47391/JPMA.S3.GNO-03>

### Introduction

Brain tumours are the 10th most common cause of mortality accounting for a quarter of a million deaths in 2019, globally. Although there have been substantial advancements in the biological and molecular understanding of brain tumours, and in their clinical management and neurosurgical techniques, low- and middle-income countries (LMICs) have not benefitted much from these developments. Age-standardized death rates for brain tumours in LMICs are much higher than in developed countries. Multiple factors contribute to the higher mortality rate associated with brain tumours in LMICs, including late and inappropriate diagnosis and lack of access to specialized neuro-oncological facilities.<sup>1,2</sup>

Histopathology is crucial for the diagnosis, prognosis, and therapy of disease. Intraoperative histopathology

.....  
<sup>1,2,3,6-8</sup>Department of Neurosurgery, The Aga Khan University, Karachi, Pakistan.<sup>4</sup>Department of Pathology, University of Colorado, Children's Hospital, Colorado, USA. <sup>5</sup>School of Computer Science, University of Galway, Galway, Ireland.

**Correspondence:** Syed Ather Enam. **Email:** [ather.enam@aku.edu](mailto:ather.enam@aku.edu)

consultation is an integral component of the management of brain tumours that provides assessment of the adequacy of the material and preliminary diagnosis to help neurosurgeons decide the extent and type of surgical resection.<sup>3-5</sup> Three most commonly used intraoperative diagnostic methods include frozen sections (FS), imprint cytology, and squash cytology. The choice of method depends on personal preference and experience of both the neurosurgeon as well as the pathologist, but overall FS is the most common and widely used technique.<sup>6,7</sup> A frozen section (FS) requires a cryostat, an expensive equipment to maintain freezing temperatures while processing the sample; therefore, limiting widespread use of FS diagnosis in a resource-limited setting. Wide availability of FS in routine neurosurgical practice is further limited due to the absence of skilled histotechnologist and pathologists.<sup>8,9</sup>

Neurosurgical practice in LMICs requires an accurate and rapid, yet simple and cost-effective method for intraoperative diagnosis. A brain smear preparation during surgical procedures offers a rapid, precise, and cost-effective alternative with a diagnostic accuracy of

94.9%<sup>3</sup>, compared to the frozen section which has a diagnostic accuracy of 88.8%.<sup>10</sup> Smear preparations, variants of which are also referred to as "squash" or "wet-film" preparations, are currently performed by pathologists in the histopathology laboratory. Smear preparations typically require less tissue than a frozen section and are safer in case an infectious etiology is encountered in the case.<sup>11</sup>

Here, we propose a modified smear preparation protocol that can be performed and interpreted by neurosurgical team within the operating room with the help of artificial intelligence and an optional tele-pathology consultation with an off-site pathologist. A smear preparation that is conducted in the operating room and read by neurosurgical team can bridge the gap in delayed intraoperative diagnosis, lack of access to trained neuropathologists who are usually available only in specialized neuro-oncological centers.

There are several advantages to training neurosurgical trainees in the preparation and interpretation of brain tumour smear slides, particularly in terms of cost-effectiveness and infrastructure. First, it can reduce the need to send tissue samples to a histopathology laboratory, which can save time and resources, especially in settings where there may be limited access to laboratories or where transportation of tissue samples may be challenging. Second, it can reduce the need for additional surgeries to obtain tissue samples for diagnosis, which not only reduces morbidity but can also lower the overall cost of patient care. Third, it can improve the efficiency of the surgical procedure by allowing the trainees to make a diagnosis or identify any abnormalities in real-time during surgery, which can potentially reduce the length of the surgery and the need for additional interventions. Fourth, it can be more cost-effective to train neurosurgical trainees in histopathology compared to hiring additional histopathologists or sending tissue samples to external laboratories. Fifth, the use of virtual and online training can reduce the need for costly infrastructure, such as physical classrooms or specialized laboratory equipment, and can make the training more accessible to trainees in remote or underserved areas.

Machine learning (ML) and more specifically deep learning (DL) have recently shown huge potential in analysing images for a range of applications. A groundbreaking work reported in ImageNet Large-Scale Visual Recognition Challenge (ILSVRC) 2012<sup>12</sup>, where a Convolutional Neural Network (CNN) almost halved the second-best error rate (from 26.2% to 15.3%), bringing a revolution in imaging domain. For the domain of medical image processing and analysis, applications to which DL

have been successfully applied include radiology<sup>13</sup>, brain segmentation<sup>14</sup>, intraoperative brain tumour diagnosis<sup>15</sup>, chest imaging<sup>16</sup> and the segmentation of organs<sup>17</sup>; however, this list is far from extensive. Using deep learning to automate the process of reading brain smear slides has several advantages in low- and middle-income countries (LMICs). First, it has the potential to improve the accuracy of brain tumour diagnosis, which is important in LMICs where access to trained pathologists may be limited and the workload may be high. Second, it can significantly increase the efficiency of the diagnosis process, reducing the workload of trained pathologists and reducing the time that patients have to wait for a diagnosis. DL models are time consuming while training; however, once trained and deployed they can process an image in a fraction of a second to a few seconds. Third, it can lead to cost savings for healthcare systems in LMICs by reducing the need for trained pathologists and the resources required for the diagnosis process. In addition, the recent explainable artificial techniques can help in highlighting the region of interest based on which the image is categorised into certain category that helps in augmenting the decision power of medical professionals. Finally, it can improve access to care for patients in LMICs by increasing the accuracy and efficiency of brain tumour diagnosis, particularly in areas where access to medical professionals and diagnostic facilities may be limited.

The aim of this study is to assess the feasibility and implementation of intra-operative brain smear technique for brain tumour diagnosis by comparing it with frozen section and histopathology report in a LMIC. Additionally, we aim to train neurosurgical trainees and incorporate artificial intelligence in brain smear preparation and interpretation.

## Objectives

### Primary

- To assess the feasibility of preparing and interpreting intraoperative brain smears within the operating room.
- To determine the sensitivity, specificity, and positive and negative predictive values of intraoperative smear technique in comparison with gold standard final histopathology and conventional frozen section.
- To evaluate the time it takes to interpret the smear technique and its impact on the overall surgical duration and outcome.
- To determine the cost-benefit relative to the frozen section.

## Secondary

- To train neurosurgical trainees in the interpretation of common brain tumour smears.
- To incorporate artificial intelligence (AI) based methods in brain smear prep interpretation.
- To design a telepathology interface for consultation with a neuropathologist in challenging cases

## Materials and methods

The study has the design of an observational study. The study will be conducted over a period of two years, from May 2024 to July 2026, during which time the sample collection will take place. The analysis of the collected data is expected to take two weeks. In addition to the sample collection, the study will also include a training component that will span 3 months from July to September 2024 at section of neurosurgery department, Aga Khan University Hospital Karachi, Pakistan (AKUH).

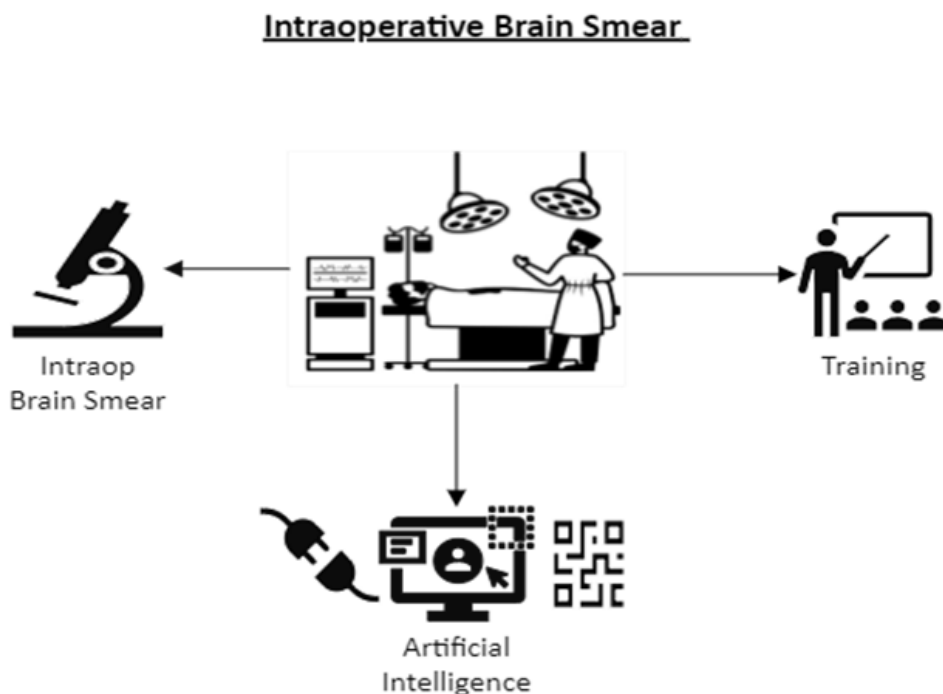
Sampling technique used is non-probability consecutive. The required sample size of this study was calculated using OpenEpi software.<sup>18</sup> The minimum sample size that will be required for the principal study is 258 patients with inflation of 10% for loss to follow-up or missing data. Based on the anticipated sensitivity of 98% and specificity of 100% of intraoperative brain smear<sup>3</sup> and a 1.3%

prevalence of brain tumours 7 along with a 5% level of significance and precision of 5%.

**Inclusion criteria:** All patients, both gender and all age groups, who will present to section of neurosurgery and undergo surgery (open craniotomies or stereotactic biopsies) for brain tumours (primary or metastatic) at AKUH will be included. The patients or parents/guardians (in case of paediatrics, ages <18 years) will be provided with written informed consent and confidentiality assurances. The decision to perform the surgery will be based on clinical need and not for the sake of participation in the study.

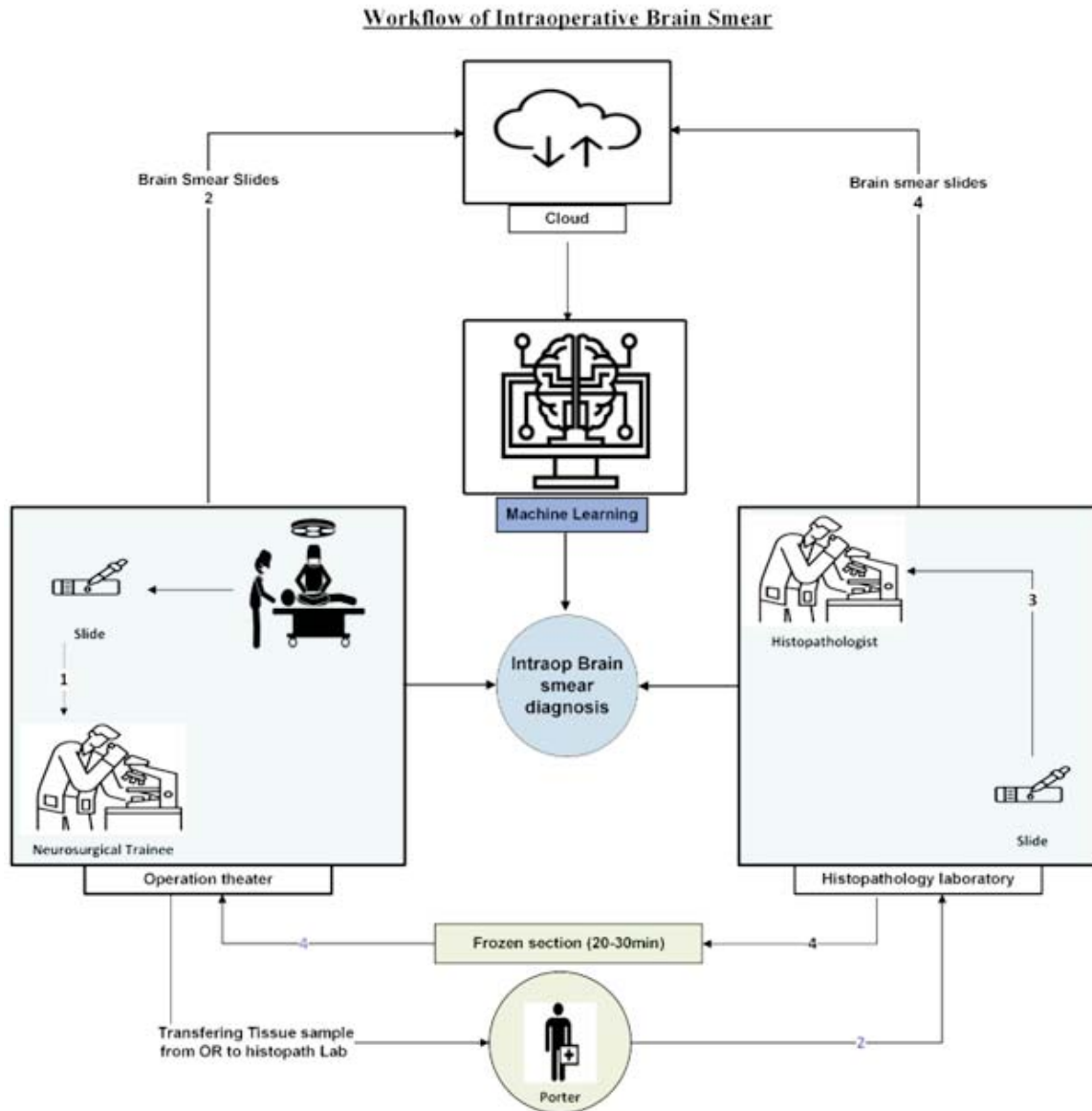
**Exclusion criteria:** Since the use of tissue for rapid diagnosis reduces the amount of material available for subsequent permanent section analysis, patients in which limited tumour sample is available (especially midline brain, brainstem and spinal cord cases), traumatic brain injuries (TBI), and CNS aneurysms will be excluded. Those who present or are referred to with a brain tumour confirmed by a biopsy will be excluded. Patients undergoing surgery for masses or lesions other than suspected neoplasms will be excluded.

This study involves a three-armed approach, consisting of (i) obtaining brain smear samples during surgical procedures, (ii) training neurosurgical trainees, and (iii)



**Figure-1:** Depicting the three arms of the study.





**Figure-2:** Showing the workflow of intraoperative brain smear and deep learning.

integrating deep learning techniques for interpreting brain smear data, as depicted in (Fig 1). The three arms are interconnected and their workflow is illustrated in (Fig 2).

### Intra-operative procedure

Prior to the surgical procedure, a comprehensive explanation of the procedure will be provided to patients who meet the inclusion criteria. In the case of minors under 18 years of age, their parents or legal guardians will also be informed. After the explanation of the procedure, written informed consent will be obtained. The researcher will follow the case during the operative procedure. Surgical team members will allocate the resected tumour sample for routine clinical histopathology and the

remaining material will be given to the investigator for the study. According to the size of the specimen and surgical biopsy protocol, the specimen will be dissected into slices after being cut open. The smear will be prepared using two to three tissue bits, each measuring 0.1–0.2 cm, from different sites of the specimen. The slides will be examined independently under a microscope inside the operating room by a neurosurgical trainee previously trained by the study neuropathologist. The neurosurgical trainee involved in the study will be actively participating in the surgery. The smear findings of the neurosurgical trainee will be documented and later compared to the results of routine intraoperative consult (smear and or frozen section) and final histopathology

result obtained from the pathology department. The study histopathologist will not necessarily be involved in reading and signing out the final pathology report.

### **Touch imprint smear and staining**

Two slides will be prepared for the touch imprint smear by lightly touching the brain specimen on a glass slide that has been labeled. Both slides will be fixed in 100% alcohol and subsequently stained with hematoxylin and eosin (H&E). The tissue used for the touch imprint will subsequently be used for smear preparation.

### **Squash smear and staining**

Three squash preparations will be made for each case. A small volume of brain tumour tissue (1-2 mm in largest dimension) will be placed onto a clean, dry, and labelled glass slide. The slide will then be covered with another slide with just enough pressure to spread the tissue into a thin film. Once a thin film of cells has formed, the two slides will be pulled apart. The slides will be immediately immersed in a 95% alcohol solution, and one of the slides will be stained with haematoxylin and eosin (H&E) and the other with Giemsa stain. The third slide will be fixed in alcohol and left unstained to be used if needed.

### **Microscopic examination**

All slides will be stained together and following cover slipping will be examined by neurosurgical team members trained in intraoperative histology analysis. The light microscope for this purpose will be available on a pushcart for easy transport to the operating room. The study pathologist will be consulted by sharing digital images on dedicated telepathology interface developed as part of this study, in case a confident diagnosis is not reached in the operating room. These two results will be compared with the AI based results and a final diagnosis will be reached by the investigators and these results along with the time needed will be documented. After the surgery, the intraoperative diagnosis reached by the investigators (neuropathology trainee) will be compared with the final histologic diagnosis based on routine histology and immunohistochemical techniques.

### **Artificial intelligence arm of the study**

This arm of the study aims to use deep learning to automate the process of reading brain smear slides for the detection of brain tumours. To do this, we will first collect a large dataset of brain tumour smear slides that have been accurately labelled by a pathologist. This dataset will consist of archived pathology cases at AKUH as well as any freely available online datasets. The microscopic images will be preprocessed by resizing or cropping and normalising the pixel values as needed. The dataset will

then be split into a training set and a test set.

We will use a convolutional neural network (CNN) as the deep learning model architecture, and will configure the model for training. The model will be trained on the training set and we will monitor its performance on the test set. If needed, we will fine-tune the model to improve its performance on the test set.

Once the model is performing well on the test set, we will use it to classify new brain smear slides and identify any pathologies present on the slides. We will evaluate the model's performance on the new slides using metrics such as accuracy, precision, and recall. Finally, we will document the results of the study, including any limitations or potential sources of error. To evaluate the inter- and intra-observer variability, we will utilize Cohen-kappa (where only two labellers) and Fleiss-kappa coefficient metrics which measures the degree of agreement between/among labellers. This often deals with data that are the result of a judgment, not a measurement. Similarly, its variations will be considered to further validate inter and intra labelling. On the other hand, in the scenario of having less data for training and testing the DL model, we will use k-fold cross-validation. This method involves dividing the data into k equal parts or folds. The model will be trained on k-1 folds and evaluated on the remaining one. This process is repeated k times, with each fold serving as the test set once. The average performance of the model across all k iterations will be calculated and used to predict its performance on new, unseen data.

### **Training neurosurgical trainees**

This arm of the study aims to train neurosurgical trainees in how to prepare and interpret brain tumour smear slides inside the operating room. The training will be conducted through a series of virtual and in-person workshops, and online courses led by the study neuropathologist. The workshops and courses will cover topics such as the indications for preparing brain smear slides, the proper technique for preparing the slides, the interpretation of the slides, and the reporting and communication protocols for the tissue sample.

The virtual workshops will be conducted via videoconferencing software and will allow trainees to participate from any location with an internet connection. The in-person workshops will be held at various locations across the country, and trainees will be responsible for their own travel and accommodation arrangements. The online courses will be self-paced and will be accessible through a learning management system. Lectures/workshops will be recorded and available on the web as

future reference. To evaluate the level of understanding of brain smear analysis among neurosurgical trainees, a questionnaire consisting of basic neuropathology questions will be administered before and after the training session. The questionnaire will be designed by a trained neuropathologist and the improvement in performance will be determined through a comparison of the pre- and post-session assessments.

### Data collection

Data collection for this study will be performed through a pre-formed, password-protected questionnaire for neurosurgical trainees and by a trained neuropathologist. To streamline data collection and reduce the amount of time required, the data will be recorded using a digital questionnaire and later imported to an Excel spreadsheet. This data will include demographics, preoperative diagnosis, location of the tumour, size of the tumour, surgical approach, duration of smear preparation and interpretation, challenges encountered during the preparation and interpretation of the slides, comparison of smear results with final histopathology and frozen section results. Cases will be categorized into three groups: 1) concordant cases when diagnosis of the smear preparation was same as the final histopathological diagnosis; 2) partially concordant when the smear and the final differ in tumour grade or specificity of diagnosis; and, 3) discordant cases - when the final histopathologic diagnosis differed from the smear preparation diagnosis.

### Data management/Plan of statistical analysis

The collected data will be cleaned and given value labels in the Excel. The data will be imported and analyzed using SPSS software version 26.0. The qualitative variables will be reported as frequencies and percentages, and the quantitative variables will be reported as mean  $\pm$  SD. The study will consider a p-value of less than 0.05 to be significant. The feasibility of brain smear will be based on key factors like the time it takes to perform, any challenges encountered during preparation and interpretation, cost, and the perspectives of neurosurgical trainees as rated using a Likert scale. The diagnostic precision of the procedure will be assessed by computing metrics like the area under the curve, sensitivity, specificity, positive predictive value, and negative predictive value. The impact of the procedure's duration on the total duration of the surgery will be analyzed by calculating the mean  $\pm$  standard deviation (SD) / median (IQR). The cost of each procedure will be calculated by considering factors like the number of smear slides utilized, the cost of the stains, and the expenses associated with the microscope. These factors will be

combined to determine the overall cost, which will then be compared to the cost of standard frozen section procedure. To evaluate the inter- and intra-observer variability, kappa statistics will be applied.

### Ethical consideration

The participants of the study will be fully informed of the study's objectives, procedures, and their rights as participants. They will have the opportunity to address any concerns arising and they will provide written informed consent. In case of minors under the age of 18 years, their parents or legal guardians will receive a comprehensive explanation of the purpose and procedures of the study and will be asked to provide written informed consent. Participation in the study is voluntary, and participants may withdraw at any time without any negative repercussions or compromise in their treatment plan in anyway. All data will be kept secure in a password-protected (cloud based) database. A unique ID will be assigned to patients to maintain confidentiality. De-identified data will be analysed and presented to the scientific community through publications. The study has received approval (#2024-8527-27676), dated 30th January, 2024, from the Ethical Committee at Aga Khan University Hospital, Karachi.

### Risk/benefit assessment

There is neither known health risk nor any specific clinical benefits to the research participant. Additionally, the research participant will not be provided any financial or other incentives. The clinical decision making on study cases will rely exclusively on routine procedures including standard histopathologic diagnosis obtained through routine diagnostic techniques including frozen section and smear preparations performed and read by certified histopathologists as per routine. The results of the intraoperative smear conducted within the operating room will be documented but not communicated to the neurosurgery team, so as not to influence clinical decision making during the procedure.

### Costs to the subject

This additional intraoperative research technique will not cost the patient any extra charges.

### Expert opinion

Expert opinion was solicited from a panel of experts comprising a neurosurgeon, a neuropathologist, and an artificial intelligence consultant regarding the feasibility and implementation of brain smear in LMIC operating rooms. The panel's insights were informed by their expertise, experience, and working background in LMIC healthcare structures and the constraints of healthcare

care delivery in these settings. The expert opinions of the panelists are presented below.

### **Neurosurgeon perspective**

Brain tumours pose a significant burden on the health outcomes of individuals in (LMICs), where the current state of neurosurgical care is concerning due to a rise in incidence and inadequate resources. The unmet demand for essential neurosurgical interventions in LMICs is estimated to be five million cases, underscoring the issue of unequal healthcare allocation and resource distribution across regions.<sup>19</sup> This inequity is further highlighted by the fact that many LMICs have a ratio of only 0.01-0.1 neurosurgeons per 100,000 populations<sup>2</sup>, despite 80% of approximately 13.8 million neurosurgical cases occurring in these developing regions with limited resources.<sup>20</sup>

Intraoperative diagnosis is one aspect of a multifaceted process of brain tumour management. It plays a pivotal role in achieving safe and maximal resection of brain tumours, and the accuracy of such diagnosis is paramount to favourable patient outcomes. Frozen section is a widely used intraoperative technique for diagnosing brain tumours, and is considered to be one of the most accurate methods. Nevertheless, frozen section has significant limitations in resource-limited settings, particularly in (LMICs).

The financial, logistical, and human resource demands of frozen section limit its feasibility and implementation in LMICs. These limitations include the expense and need for sophisticated equipment, the labour-intensive and time-consuming nature of the technique, the demand for specialized training, and a shortage of skilled personnel, particularly neuropathologists, which is particularly acute in LMICs. In light of these limitations, there is need for innovative, cost-effective, and accurate techniques for intraoperative brain tumour diagnosis.

One such technique is the intraoperative brain smear, which entails the preparation and interpretation of brain smears in the operating room by a trained neurosurgical trainee. Intraoperative brain smear has significant advantages over frozen section, including its simplicity, rapidity, and ease of implementation. Additionally, intraoperative brain smear can expedite intraoperative procedures and reduce the need for specialized personnel, equipment, and infrastructure.

A feasibility study can test the practicality of intraoperative brain smear and its potential for implementation in LMICs. Such a study can evaluate the accuracy, efficiency, and cost-effectiveness of the

technique and provide the foundation for broader implementation in other settings. In conclusion, the intraoperative brain smear technique shows promise as a viable and cost-effective alternative to frozen section in LMICs, and its utilization has the potential to improve the standard of care for neuro-oncology patients in these settings.

### **Neuropathologist perspective**

Intraoperative consultation when used judiciously can be a crucial component of surgical management of CNS tumours. While many methodologies have been used for tissue preparation for intraoperative consultation, smear preparations and frozen sections remain the mainstay all over the world. Smear preparations have proven to be highly sensitive and specific and have the inherent benefit of being rapid, low-cost and economical in terms of tissue volume requirement. This study will investigate the feasibility of bringing intraoperative smear preparation interpretation to the operating room by enabling neurosurgery team members to prepare and read the smears without the help of on-site pathologists. Another innovative aspect of this study is the integration of artificial intelligence tools to facilitate the interpretation of smear preparations and the development of a telepathology interface to elicit consultation from an off-site neuropathologist. The results from this study have the potential of transforming neurosurgery practice in the LMIC by bringing quality intraoperative consultation to places that currently lack infrastructure and expertise.

### **Artificial intelligence consultant perspective**

Medical image processing has been essential for detection, classification, and understanding of numerous diseases. According to a report in 2002 from Department of Radiology at the University Hospital of Geneva, between 12,000 and 15,000 images are produced daily. Furthermore, in last decade, many imaging techniques such as X-ray, Magnetoencephalography (MEG), Computed Tomography (CT), Ultrasonography, Single-Photon Emission Computed Tomography (SPECT), Magnetic Resonance Imaging (MRI), etc. have emerged which increased the speed of medical image acquisitions to exhibit the detailed and complete facets of brain tumours but also help doctors to accurately diagnose the tumour and determine the correct treatment mechanism.

Histopathology is considered gold standard for tissue assessment in clinical decision making and in research. However, conventional histological preparation and analysis is known to be time consuming and labour intensive and misclassification can result in major

consequences such as reduce the patient's survivability. However, an efficient computer based diagnostic system can overcome the manual evaluation of medical imaging which is a time-consuming and not perfect as it is prone to human error and dependent on radiologist's skills and knowledge. Recently, DL has demonstrated promising results as a decision support system to assist in the detection of diseases and the establishment of precise medical diagnoses. Such a system can help in not only improving the accuracy of brain tumour diagnosis but also important in LMICs where access to trained pathologists may be limited and the workload may be high. These DL models are fast at runtime i.e.; these can process an image in a fraction of a second to a few seconds for example recently researchers in John Hopkin proposed a model that can classify a brain tumour within 150 seconds.<sup>15</sup> The proposed system with AI/DL in the background and its advance features of explainability in front end within telepathology system having a user-friendly graphical user interface can greatly help LMICs by reducing the need for trained pathologists and the resources required for the diagnosis process. The XAI part will augment the decision power of medical professionals.

## Conclusion

In conclusion, considering the above benefits, a feasibility study is required to check the practicality of such an AI based system that will use the histopathological images of intraoperative brain smear, to see the potential for its implementation in LMICs.

**Disclaimer:** None.

**Conflict of Interest:** None.

**Funding Disclosure:** None.

## References

- Sharma R. A Systematic Examination of Burden of Childhood Cancers in 183 Countries: Estimates from GLOBOCAN 2018. *Eur J Cancer Care (Engl)* 2021;30:e13438. doi: 10.1111/ecc.13438
- Gupta T, Achari R, Chatterjee A, Chen ZP, Mehta M, Bouffet E, et al. Comparison of Epidemiology and Outcomes in Neuro-Oncology Between the East and the West: Challenges and Opportunities. *Clin Oncol (R Coll Radiol)* 2019;31:539-48. doi: 10.1016/j.clon.2019.05.018
- Krishnani N, Kumari N, Behari S, Rana C, Gupta P. Intraoperative squash cytology: accuracy and impact on immediate surgical management of central nervous system tumours. *Cytopathology* 2012;23:308-14. doi: 10.1111/j.1365-2303.2011.00905.x
- Folkerth RD. Smears and frozen sections in the intraoperative diagnosis of central nervous system lesions. *Neurosurg Clin N Am* 1994;5:1-. PMID: 8124086.
- Powell SZ. Intraoperative consultation, cytologic preparations, and frozen section in the central nervous system. *Arch Pathol Lab Med* 2005;129:1635-52. doi: 10.5858/2005-129-1635-ICCPAF
- Agrawal M, Chandrakar SK, Lokwani D, Purohit MR. Squash cytology in neurosurgical practice: a useful method in resource-limited setting with lack of frozen section facility. *J Clin Diagn Res* 2014;8:FC09-12. doi: 10.7860/JCDR/2014/10142.4921
- Khattak T, Javaid K, Haque AU, Azam F, Khan T. Diagnostic Accuracy of Touch Cytology of Central Nervous System Lesions. *Int J Pathol* 2020;18:3-10.
- Jain S, Kaushal M, Choudhary A, Bhardwaj M. Comparative evaluation of squash smear and frozen section in the intraoperative diagnosis of central nervous system tumours. *Cytopathology* 2022;33:107-13. doi: 10.1111/cyt.13049
- Olasode BJ, Ironside JW. The brain smear, a rapid affordable intraoperative diagnostic technique for brain tumours appropriate for Africa. *Trop Doct* 2004;34:223-5.
- Obeidat FN, Awad HA, Mansour AT, Hajeer MH, Al-Jalabi MA, Abudalu LE. Accuracy of Frozen-Section Diagnosis of Brain Tumors: An 11-Year Experience from a Tertiary Care Center. *Turk Neurosurg* 2019;29:242-6. doi: 10.5137/1019-5149.JTN.23220-18.2
- Firlik KS, Martinez AJ, Lunsford LD. Use of cytological preparations for the intraoperative diagnosis of stereotactically obtained brain biopsies: a 19-year experience and survey of neuropathologists. *J Neurosurg* 1999;91:454-8. doi: 10.3171/jns.1999.91.3.0454
- Krizhevsky A, Sutskever I, Hinton GE. ImageNet classification with deep convolutional neural networks. [Online] 2017 [Cited 2024 March 04]. Available from URL: <https://doi.org/10.1145/3065386>
- Yamashita R, Nishio M, Do RKG, Togashi K. Convolutional neural networks: an overview and application in radiology. *Insights Imaging* 2018;9:611-29. doi: 10.1007/s13244-018-0639-9
- Akkus Z, Galimzianova A, Hoogi A, Rubin DL, Erickson BJ. Deep Learning for Brain MRI Segmentation: State of the Art and Future Directions. *J Digit Imaging* 2017;30:449-5.
- Hollon TC, Pandian B, Adapa AR, Urias E, Save AV, Khalsa SSS, et al. Near real-time intraoperative brain tumor diagnosis using stimulated Raman histology and deep neural networks. *Nat Med* 2020;26:52-8. doi: 10.1038/s41591-019-0715-9
- van Ginneken B. Fifty years of computer analysis in chest imaging: rule-based, machine learning, deep learning. *Radiol Phys Technol* 2017;10:23-32. doi: 10.1007/s12194-017-0394-5
- Cha KH, Hadjiiski L, Samala RK, Chan HP, Caoili EM, Cohan RH. Urinary bladder segmentation in CT urography using deep-learning convolutional neural network and level sets. *Med Phys* 2016;43:1882. doi: 10.1118/1.4944498
- Dean AG, Sullivan KM, Soe MM. OpenEpi: Open Source Epidemiologic Statistics for Public Health, Version: 3.01. [Online] 2013 [Cited 2024 March 04]. Available from URL: [https://www.openepi.com/Menu/OE\\_Menu.htm](https://www.openepi.com/Menu/OE_Menu.htm)
- Dewan MC, Rattani A, Fieggen G, Arraez MA, Servadei F, Boop FA, et al. Global neurosurgery: the current capacity and deficit in the provision of essential neurosurgical care. Executive Summary of the Global Neurosurgery Initiative at the Program in Global Surgery and Social Change. *J Neurosurg* 2018;130:1055-64. doi: 10.3171/2017.11.JNS171500.
- Mukhopadhyay S, Punchak M, Rattani A, Hung YC, Dahm J, Faruque S, et al. The global neurosurgical workforce: a mixed-methods assessment of density and growth. *J Neurosurg* 2019;130:1142-8. doi: 10.3171/2018.10.JNS171723.

### DISCLAIMER

Articles published in JPMA and Supplements of JPMA do not represent the views of the editor or editorial Board. Authors are solely responsible for the opinions expressed and the accuracy of the data.

The contribution of each author towards the published research included in this supplement is the responsibility of the authors and their institutions. It is expected to be in accordance and compliance with the ICMJE Guidelines.

Any questions/queries raised by readers should be directed to the corresponding author.

## NARRATIVE REVIEW

**Global neuro-oncology: what lies ahead for low- and middle-income countries?**

Syed Ather Enam<sup>1</sup>, Kee B. Park<sup>2</sup>, Naureen Mushtaq<sup>3</sup>, Muhammad Faraz Raghbi<sup>4</sup>, Fatima Mustansir<sup>5</sup>, Mashal Murad Shah<sup>6</sup>, Mohammad Hamza Bajwa<sup>7</sup>, Minhal Faisal<sup>8</sup>, Michael C. Dewan<sup>9</sup>, Tariq Khan<sup>10</sup>, Jack P. Rock<sup>11</sup>

**Abstract**

Over the past few decades, the global healthcare community has achieved remarkable success in controlling many communicable diseases across various regions. However, non-communicable diseases now constitute a significant portion of disease morbidity and mortality, particularly in low- and middle-income countries (LMICs). Among these, cancer, in particular, is witnessing a notable increase in incidence in many LMICs. Among cancers, neurological tumours bear significant impact in terms of long-term disability, escalating costs of comprehensive multidisciplinary care, and often encounter resource-related and systemic delays in care leading to worse outcomes. This opinion paper discusses key concepts in developing global neuro-oncology care, with specific case examples from Pakistan to illustrate methods for improving care in these underserved regions. Additionally, it outlines strategic approaches and potential solutions to address these challenges, aiming to provide a roadmap for enhancing neuro-oncology care in LMICs.

**Keywords:** Ursidae, Incidence, Noncommunicable Diseases, Communicable Diseases, Health Care, Neoplasms, neurosurgery

**DOI:** <https://doi.org/10.47391/JPMA.S3.GNO-04>

**Introduction**

Neurosurgery in the context of global surgery has previously taken a backseat to more pressing concerns for general surgical, obstetric, anaesthesia, and orthopaedic

<sup>1,7</sup>Department of Neurosurgery, The Aga Khan University, Karachi, Pakistan.

<sup>2</sup>Department of Global Health and Social Medicine, Harvard Medical School, Boston, USA. <sup>3</sup>Department of Paediatric Oncology, The Aga Khan University, Karachi, Pakistan. <sup>4</sup>Wayne State University, Michigan, USA. <sup>5</sup>Department of Surgery, Washington University School of Medicine, Missouri, USA.

<sup>6</sup>Department of Surgery, The Aga Khan University, Karachi, Pakistan. <sup>8</sup>The Aga Khan Medical College and University, Karachi, Pakistan. <sup>9</sup>Department of Neurosurgery, Vanderbilt University Medical Centre, Nashville, USA.

<sup>10</sup>Department of Neurosurgery Northwest General Hospital and Research Centre, Peshawar, Pakistan. <sup>11</sup>Department of Neurological Surgery, Henry Ford Hospital, Detroit, Michigan, USA.

**Correspondence:** Syed Ather Enam **Email:** [ather.enam@aku.edu](mailto:ather.enam@aku.edu)

capacity; possibly due to a perceived higher cost, complexity, and expertise required for neurosurgical capacity and public health buy-in. Low- and middle-income countries (LMICs) are acutely affected by the shortage in neurosurgeons and access to care; recent data from LMICs shows that general surgeon density (0.13-1.57 per 100,000 population), obstetrician density (0.042-12.5 per 100,000) and anaesthesiologist density (0-4.9 per 100,000) outmatches neurosurgeon density in Pakistan (0.139 per 100,000 people).<sup>1</sup> Dewan et al. estimate an unmet deficit in neurosurgical care of more than 5 million neurosurgical operations globally, requiring an additional 23,000 neurosurgeons in LMICs.<sup>2</sup> Overall, surgery, and in particular neurosurgery, is viewed as expensive, complex, and difficult to maintain quality control in South Asia leading to a large, unmet burden.

It is estimated that by 2030, there will be a cumulative GDP loss of USD 7 trillion incurred by neglecting care for individuals affected by cancer, who could otherwise undergo surgical treatment.<sup>3</sup> Almost half of new cancer cases reported in the world in 2018 were from Asia.<sup>4</sup> While disability adjusted life years (DALYs) decreased in high- and upper-middle income countries (HICs and UMICs), they increased over time in low income regions.<sup>3</sup> Further compounding the situation is extremely low GDP and GNI per capita for LMICs. For Pakistan, the estimated GDP per capita figure for the year 2023 is USD 1,471.<sup>5</sup>

Central nervous system (CNS) (i.e., brain and spinal) tumours are among the top ten conditions that constitute the foundation of essential neurosurgical care.<sup>2</sup> While CNS tumours represent a subset of neurosurgical disease burden in the already niche field of global neurosurgery, we aim to make a case for global neuro-oncology that is, the area for study, research, practice, and advocacy that places priority on improving health outcomes and achieving health equity for all people worldwide who are affected by CNS tumours.

CNS tumours significantly impact global morbidity and mortality. The Global Burden of Disease study estimated 330,000 new cases and 227,000 deaths in 2016, with a 17.3% increase in incidence from 1990 to 2016, notably in South Asia.<sup>6</sup> Stark disparities exist between high-income

countries (HICs) and low- and middle-income countries (LMICs) in management quality and access. For instance, a UK survey of 136 patients highlighted surgery as the primary treatment, but identified gaps in post-discharge support and research involvement.<sup>7</sup> Contrastingly, in Sudan, only 8 out of 62 paediatric patients underwent complete tumour resection, with a 11% treatment abandonment rate and low 2-year (33%) and 5-year (13%) survival rates, attributed to late-stage diagnosis, lack of multidisciplinary care, and limited neurosurgical access.<sup>8</sup> Similarly, Pakistan demonstrates disparities in surgical access, gender biases, and referral challenges for postoperative adjuvant treatment.<sup>9-12</sup>

### Management of CNS tumours

CNS tumour management, though advanced, remains a challenge, especially in LMICs where many technologies are inaccessible. MRI is the primary modality for brain tumour evaluation, with surgical resection being the main treatment, particularly for high-grade gliomas where resection extent influences survival outcomes.<sup>13</sup> Standard care for glioblastoma multiforme (GBM) includes post-resection chemo-radiotherapy with temozolomide.

MRI, craniotomy, chemotherapy, and radiotherapy form the baseline standard in CNS tumour management. Additional tools like magnetic resonance spectroscopy (MRS) help identify high-grade tumours, but are not routinely used. Advanced MRI techniques, intraoperative neuro-navigation, and fluorescence technologies enhance surgical precision, while intraoperative ultrasounds offer a cost-effective imaging alternative. Intraoperative neuromonitoring and neuro-endoscopes,

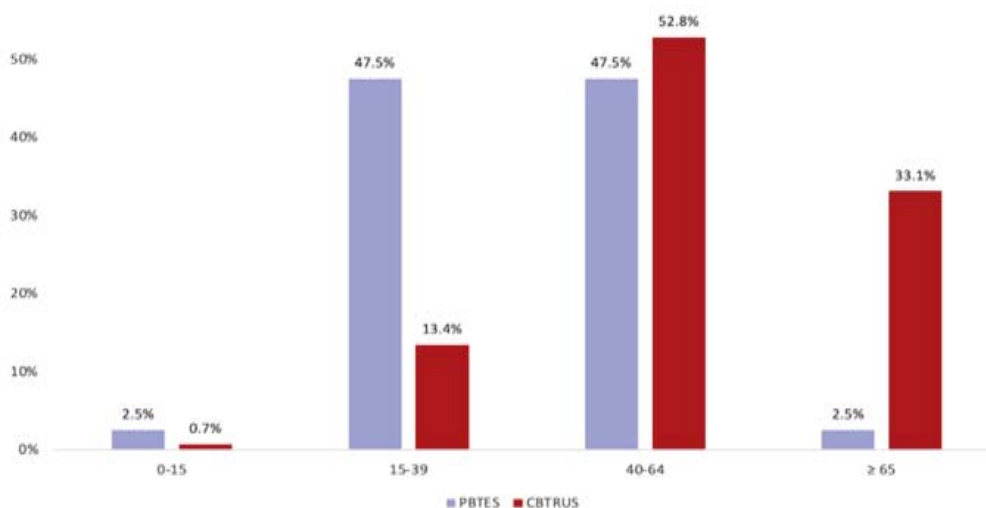
along with newer tools like cavitating ultrasonic aspirators (CUSA), further expand neurosurgical capabilities.<sup>14</sup>

For recurrent GBM, options include nitrosoureas and bevacizumab, with implantable carmustine wafers emerging as a promising alternative.<sup>15</sup> Stereotactic surgery and whole brain radiation therapy are standard for brain metastases management.

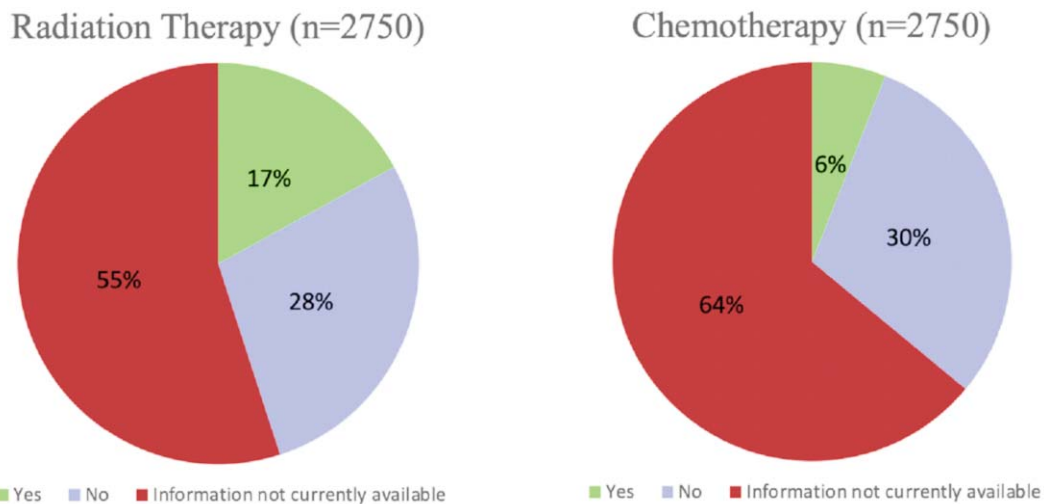
The feasibility of advanced neurosurgical tools in LMICs is questionable due to fundamental equipment shortages. For example, neurosurgeons at Alexandria University Hospital in Egypt frequently depend on limited MRI studies and improvise with basic tools under resource constraints.<sup>16</sup> In Pakistan, neuron navigation and ultrasonic aspirators are rare, and although one hospital offers fluorescent microscopy with 5-ALA, its high cost prohibits its use, significantly adding to the total bill. Meanwhile, awake craniotomy is increasingly considered in LMICs for its potential to enhance outcomes affordably.<sup>17-20</sup>

### Pakistan brain tumour epidemiological study

Epidemiological studies reveal significant differences in the incidence of brain tumours between HICs and LMICs, variations that can be attributed to disparities in diagnosis, pathology reporting, treatment modalities, and overall healthcare availability. For example, in Pakistan, hospital records often lack postoperative treatment details, and CNS tumours tend to present earlier in life compared to typical adult-onset patterns. Figure 1 shows



**Figure-1:** Incidence of brain tumours among different age groups between Pakistan Brain Tumour Epidemiology Study (blue) and Central Brain Tumour Registry of the United States (red).



**Figure-2:** Distribution of postoperative treatment among Central Nervous System tumour patients in a study in Pakistan. Green: treatment received, blue: treatment not received, green: no data available.

the difference in distribution of patients according to age group between Pakistan brain tumour epidemiology study (PBTES) and central brain tumour registry of the United States (CBTRUS).

The accessibility gap for immediate neurosurgery emergency care is exacerbated by the unequal distribution of neurosurgeons and facilities, which are concentrated in urban regions. Additionally, demographic and surgical data on CNS tumours in LMICs remain sparse. Figure 2 illustrates that, in Pakistan, 55–64% of patients lack information on postoperative radiation or chemotherapy. Moreover, the gender gap in brain tumour cases highlights the urgent need to implement targeted awareness initiatives for women, particularly in rural settings.

### Financing CNS tumour care

Brain tumour management is notably expensive worldwide. In the United States, it has the highest initial per-patient cost among cancers, averaging nearly \$150,000, and leads in last-year-of-life costs, ranging from \$135,000 to \$210,000 per patient.<sup>21</sup> While precise cost

data for Pakistan is lacking and varies between public and private sectors, understanding and prioritizing these costs is crucial.<sup>22</sup> In Pakistan, over 50 hospitals offer chemotherapy, but high import costs for drugs pose financial challenges. Tebha et al. suggest policy reforms for LMICs managing GBM, including cost regulation for chemotherapy and radiation therapy, integrating neuro-oncological care into universal health coverage, and increasing health expenditure.<sup>23</sup>

### Barriers in neuro-oncology affordability

Brain tumour treatment in LMICs imposes heavy financial burdens on patients, as they often bear most treatment costs due to insufficient financial risk protection mechanisms. This financial toxicity, characterised by high out-of-pocket expenses, limited household financial capacity, and a lack of insurance or prepayment systems, drives about 100 million people into poverty annually. A 2019 study revealed that 48% of brain tumour patients in Pakistan were from lower socioeconomic backgrounds, with 37% from the middle class.<sup>9</sup> The significant patient costs at both private and public tertiary care hospitals in

**Table-1:** The table highlights the disparity in costs for surgical resection, Intensive Care Unit stay, 3- Dimensional Radiotherapy (30 cycles), and Temozolomide (for 6 months) between private and public hospitals in Pakistan.

	Private Tertiary Care Hospital Costs (USD 2023)	Public Tertiary Care Hospital Costs (USD 2023)
Surgical Resection	4449	390
ICU Stay	683.32	156
3- Dimensional Radiotherapy (30 cycles)	2413	234
Temozolomide (with radiation and for 6 subsequent months)	4645	

USD 1.00 = PKR 280 (2023)



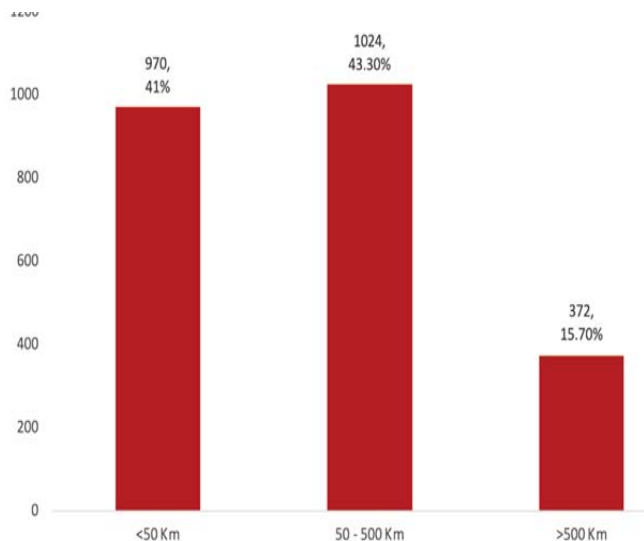
Pakistan are detailed in Table 1 from Abdullah et al.<sup>24</sup>

Additionally, regular follow-up imaging, essential for monitoring disease progression, further escalates expenses. A study on follow-up attrition found that within one year, 5.67% of patients were lost to follow-up (LTFU) post-diagnosis, 37.5% post-primary surgery, and 31.7% without receiving any adjuvant treatment.<sup>25</sup>

### Accessibility

In Pakistan and similar LMICs, barriers to surgical care for brain tumour patients extend beyond cost to include geographical accessibility (Fig.1). Approximately 40% of Pakistan's population lacks access to neurosurgical services within a 2-hour radius. Access diminishes further for advanced micro neurosurgery, with only 28.2% of South Asia's population having access compared to 52.8% for basic services.<sup>26</sup> A 2022 survey reports only 0.14 neurosurgeons per 100,000 people in Pakistan, predominantly in Punjab and Sindh, compelling patients from regions like Khyber Pakhtunkhwa and Baluchistan to travel significant distances for care.<sup>10,27</sup> Moreover, 75% of neurosurgical centres are in urban areas, disadvantaging rural residents. Figure 3 illustrates these travel distances, with only 41% having surgery access within 50 km, and over 15% traveling more than 500 km.

The shortage of specialized professionals like neuro-oncologists and radiation oncologists exacerbates the situation. While private hospitals offer better facilities and expertise, their high costs limit accessibility for most. Conversely, public hospitals, burdened by patient volume, suffer from long waiting times.<sup>28</sup> Only four hospitals in Pakistan are accredited by the Joint



**Figure-3:** The bars show the number (and percentage) of the patients who had to travel <50 Km, 50-500 Km, and >500 Km respectively.

Commission International (JCI), reflecting a scarcity of internationally recognized healthcare standards.<sup>29</sup> Additionally, while CT scan availability is high at 97% of centres, MRI and angiography suites are present in only 72% and 49% of centres, respectively.<sup>27</sup> This lack of advanced technology underscores the challenges in CNS tumour care in LMICs.

### The way forward

The increasing recognition of equitable surgical care over the past decade has encouraged healthcare professionals (HCPs) to address disparities in specialized fields like neurosurgery. In Pakistan, while comprehensive CNS tumour management is limited to a few hospitals, broader access to neuro-oncological care is achievable through strategic implementations. Insights from the 2019 epidemiological survey have laid the foundation for understanding the national landscape of brain tumour care and disease burden. The next steps include establishing prospective data registries, developing cost-estimation models, and assessing the healthcare economy's infrastructure needs. We advocate for strategies that optimize and redirect existing resources within the country in a manner that aligns with our socioeconomic context, ensuring cost-effectiveness and accessibility.

### Tele-medicine

Telemedicine, using information and communication technologies for healthcare service delivery, is vital in settings where distance is a barrier (WHO). While it has been established in developed countries, its adoption in developing nations has been slower.<sup>30</sup> However, the COVID-19 pandemic's disruption of in-person services accelerated its use in LMICs, including Pakistan. In 2020, a tertiary care hospital in Pakistan launched a tele-ICU service to offer free professional advice nationwide for COVID-19 management.<sup>31</sup>

In Turkey, telemedicine proved successful for breast cancer patient consultations at a tertiary care hospital, with physicians finding that one-third of these patients required no further intervention.<sup>32</sup> Neurosurgery outpatient visits via telehealth have also been well-received by patients and providers,<sup>33</sup> and Daggubati et al. have even proposed a model for outpatient neuro-oncological care.<sup>34</sup> Adapting this model could enhance the efficiency of consultations for CNS tumour patients in LMICs. This approach is particularly beneficial for those needing follow-up care post-surgery, potentially reducing the issue of follow-up patient attrition.

## Artificial intelligence

Artificial intelligence (AI) and machine learning are poised to significantly impact brain tumour diagnosis and survival prediction. Currently, CNS tumour diagnosis and prognosis typically rely on surgical resection followed by histopathological analysis. However, neuro-oncology radiomics, powered by AI algorithms, offers a promising alternative. This field focusses on detecting complex patterns in advanced MRI scans, facilitating diagnosis, prognosis, and treatment planning. With AI, a 'virtual biopsy' becomes possible by quantitatively analysing a tumour's radiographic characteristics, thus potentially eliminating the need for certain surgical diagnoses. This approach involves aggregating diverse data sets, including radiographic, clinical, pathologic, and physiologic patient data. By reducing reliance on surgical procedures for diagnosis, this method can save both time and costs, nudging neuro-oncology towards precision medicine.

## Training of personnel

To address the shortage of HCPs skilled in CNS tumour management, a dual strategy is necessary. First, training neurosurgeons in cost-effective approaches is crucial, emphasizing functional neuroanatomy and minimizing reliance on expensive technologies like neuron navigation and tractography. Instead, we propose focusing on the widespread use of essential tools like microscopes and instruments for basic craniotomy. Additionally, techniques like simple deep white matter stimulation during awake craniotomies can be a cost-effective substitute for tractography and fMRI.

Concurrently, it's vital to promote further specialization among HCPs, including neurosurgeons, neuro-oncologists, neuropathologists, and radiation oncologists. This can be achieved through establishing residency and fellowship programmes across Pakistan. While this ambitious initiative demands more resources than basic neurosurgical training, it is essential for the progress and sustainability of neuro-oncology in the country. Through such programmes, we aim to cultivate HCPs who will become national leaders in neuro-oncology.

## Local cancer registries consortium

The incidence of malignant brain tumours is reported as 6.29 per 100,000 person-years in HICs and 4.81 in LMICs.<sup>35</sup> However, these figures likely underestimate the true burden in LMICs due to limited access to diagnostic technology and surgical care. Incomplete case ascertainment in LMICs is a significant issue, as highlighted by International Agency for Cancer Research

(IARC) data showing that only 15% of the global population was covered by high-quality cancer registries around 2010, with particularly low coverage in South America (7.5%), Asia (6.5%), and Africa (1%).<sup>4</sup>

Population-based registries are crucial for accurately representing brain tumour epidemiology, informing policy, guiding decision-making, and elucidating causal links between behaviour and diagnosis. For example, Figure 3 compares the age distribution of brain tumour patients in Pakistan and the US. Additionally, establishing brain tumour biorepositories at individual centres is valuable for studying molecular epidemiology in LMICs. Initiatives like the Pakistan Brain tumour Epidemiology Study underscore the increasing burden of brain tumours in LMICs. Continued efforts are needed to ensure cancer registries which are comprehensive and maintain high standards for brain tumour care.

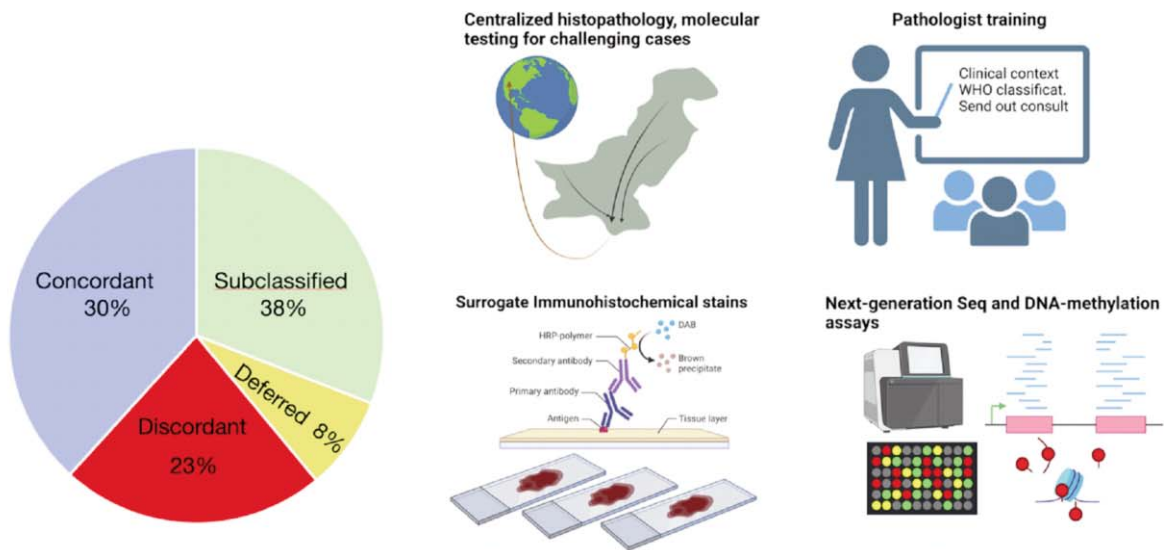
## Local brain tumour management guidelines

Customizing brain tumour treatment guidelines to fit local contexts is crucial, particularly in resource-constrained settings like Pakistan, where advanced therapeutic options are limited. For instance, adapting existing guidelines to local conditions has been demonstrated by the Indian Society of Neuro-oncology, which tailored WHO recommendations for adult diffuse gliomas diagnosis to their setting, optimizing the use of molecular tests.<sup>36</sup> Similarly, a group of prostate cancer experts modified the National Comprehensive Cancer Network (NCCN) guidelines for prostate cancer for the Middle East and North Africa region in 2010.<sup>37</sup> Such initiatives show the feasibility of localising pre-existing evidence-based guidelines to better serve the Pakistani population.

Given the shared healthcare infrastructure challenges and resource limitations between neighbouring countries like India and Pakistan, international collaboration in managing CNS cancer can be highly beneficial. The establishment of the Pakistan Society of Neuro-oncology (PASNO) is a step forward in this direction, aiming to unify intellectual and material resources for the development of neuro-oncological care in the region.

The development of local guidelines in LMICs is a critical component in advancing brain tumour care. These guidelines must be tailored to reflect the specific limitations and challenges of each region, such as the scarcity of resources, limited access to state-of-the-art medical technology, and the shortage of specialized healthcare professionals. For example, in Pakistan, guidelines could be designed to suggest alternative, more cost-effective diagnostic tools, propose the use of

### Recommendations to Improve Histopathology Diagnosis in Pakistan



**Figure-4:** Twinning experience between High Income Countries and Low Middle Income Countries to form an alliance. Different aspects of the twinning process are represented.

telemedicine to extend the reach of neuro-oncology specialists, and emphasize community-based care strategies to alleviate the pressure on centralized healthcare facilities. The formulation of these guidelines requires an inclusive and multidisciplinary approach, engaging neuro-oncologists, healthcare policymakers, patient representatives, and international collaborators. Such a comprehensive strategy ensures that the guidelines are not only practical and resource-sensitive but also adhere to a standard that does not compromise the quality of patient care. The goal is to create a

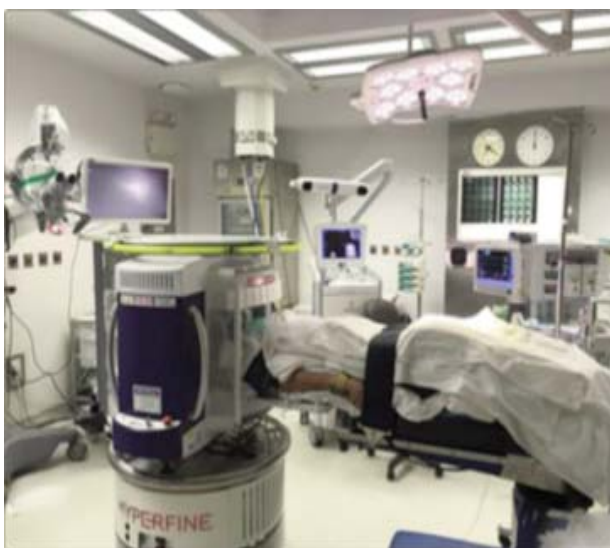framework that is both adaptable and sustainable, enabling healthcare providers in LMICs like Pakistan to deliver the best possible care to brain tumour patients within the confines of their unique healthcare landscapes.

### Multidisciplinary tumours boards and twinning programmes

Twinning programmes, formal collaborations between medical institutions in HICs and LMICs, significantly enhance cancer care in LMICs. These programmes involve sharing expertise, facilitating fundraising, and providing diagnostic services from HIC institutions to their LMIC counterparts. For example, a paediatric neuro-oncology twinning programme between a tertiary care hospital in Pakistan and a Canadian institute has been successful for over seven years (Fig. 3). This initiative has supported over 400 children with CNS cancers, offering them critical diagnostic and therapeutic services. The programme's expansion to other hospitals aims to create local twinning partnerships between advanced tertiary care centres and rural hospitals. Additionally, it has fostered the development of multidisciplinary tumour boards for CNS cancer patient management.<sup>38</sup>

### Role of pathology analysis

Accurate diagnosis is essential for the effective surgical and oncologic treatment of CNS tumours, but histopathology, a key component, is often overlooked in LMICs. Histopathology labs are typically underdeveloped, and pathologists frequently lack specialized training. Our 7-year twinning programme between Sick Kids, Canada,



**Figure-5:** Image of an Ultra-low Field Magnetic Resonance Imaging being used in a standard size operating room.

and AKUH, Pakistan, highlighted these issues. In this programme, 135 challenging paediatric CNS tumour cases were reviewed, revealing a 23% discordance rate in diagnoses. Specifically, 8% of cases were undiagnosed at AKUH and received their diagnoses through expert consultation, while an additional 40% had their diagnoses refined with molecular subclassification, achievable only with specialized molecular or immunohistochemical staining (Figure 4, panel A).

This study underscores the necessity of establishing national or regional referral centres with subspecialty-trained neuropathologists, validating brain tumour-specific immunohistochemical stains, and enabling next-generation sequencing and DNA methylation studies for cases unclassifiable by conventional histopathology (Figure 4, panel B). Figure 4 illustrates the twinning experience and its outcomes: concordant cases had no diagnostic change, discordant cases experienced major or minor diagnostic changes, deferred cases lacked initial diagnoses, and sub-classified cases received refined diagnoses with molecular subtypes after advanced testing.

### Ultra-low field mobile MRI

The integration of ultra-low field (ULF) MRI in global neuro-oncology, especially in LMICs, offers a cost-effective and accessible solution for managing CNS tumours. Its affordability and ease of operation make it ideal for use in remote medical centres, significantly reducing the need for expensive setups and specialized personnel. By enabling junior doctors to acquire quality images, ULF MRI addresses the scarcity of resources and reduces patients' travel burdens for routine follow-ups. This advancement not only improves patient compliance but also extends quality neuro-oncological care to underserved areas, marking a crucial step towards equitable healthcare in neuro-oncology.<sup>39</sup>

### Conclusion

Tackling neuro-oncology care disparities in LMICs requires a multifaceted approach that integrates innovative technologies, such as telemedicine and artificial intelligence, with traditional healthcare strategies. Strengthening training programmes for healthcare professionals, developing local guidelines tailored to resource constraints, and establishing comprehensive cancer registries are essential steps toward enhancing the management and treatment of CNS tumours in these regions. Collaborative efforts, both within countries and internationally, are crucial in sharing knowledge, resources, and expertise to overcome existing barriers. By adopting sustainable healthcare

solutions, LMICs can also advance neuro-oncology care quality, providing hope for CNS tumour patients and contributing to global health equity in neuro-oncology.

**Disclaimer:** None.

**Conflict of Interest:** None.

**Funding Disclosure:** None.

### References

1. Hoyle M, Finlayson SR, McClain CD, Meara JG, Hagander L. Shortage of doctors, shortage of data: a review of the global surgery, obstetrics, and anesthesia workforce literature. *World J Surg* 2014;38:269-80. doi: 10.1007/s00268-013-2324-y.
2. Dewan MC, Rattani A, Fieggen G, Arraez MA, Servadei F, Boop FA, et al. Global neurosurgery: the current capacity and deficit in the provision of essential neurosurgical care. Executive Summary of the Global Neurosurgery Initiative at the Program in Global Surgery and Social Change. *J Neurosurg* 2018;130:1055-64. doi: 10.3171/2017.11.JNS171500.
3. Meara JG, Leather AJ, Hagander L, Alkire BC, Alonso N, Ameh EA, et al. Global Surgery 2030: evidence and solutions for achieving health, welfare, and economic development. *Lancet* 2015;386:569-624. doi: 10.1016/S0140-6736(15)60160-X.
4. Bray F, Ferlay J, Soerjomataram I, Siegel RL, Torre LA, Jemal A. Global cancer statistics 2018: GLOBOCAN estimates of incidence and mortality worldwide for 36 cancers in 185 countries. *CA Cancer J Clin* 2018;68:394-42. doi: 10.3322/caac.21492.
5. O'Neill A. Gross domestic product (GDP) per capita in Pakistan 2023. [Online] 2023 [Cited 2024 March 21]. Available from URL: <https://www.statista.com/statistics/383750/gross-domestic-product-gdp-per-capita-in-pakistan/>.
6. GBD 2016 Brain and Other CNS Cancer Collaborators. Global, regional, and national burden of brain and other CNS cancer, 1990-2016: a systematic analysis for the Global Burden of Disease Study 2016. *Lancet Neurol* 2019;18:376-93. doi: 10.1016/S1474-4422(18)30468-X.
7. Sage W, Fernández-Méndez R, Crofton A, Gifford MJ, Bannikh A, Chrysaphinis C, et al. Defining unmet clinical need across the pathway of brain tumor care: a patient and carer perspective. *Cancer Manag Res* 2019;11:2189-202. doi: 10.2147/CMAR.S175886.
8. Elhassan MMA, Mohamedani AA, Osman HHM, Yousif NO, Elhaj NM, Qaddoumi I. Patterns, treatments, and outcomes of pediatric central nervous system tumors in Sudan: a single institution experience. *Childs Nerv Syst* 2019;35:437-44. doi: 10.1007/s00381-018-04032-9.
9. Enam SA, Shah MM, Bajwa MH, Khalid MU, Bakhshi SK, Baig E, et al. The Pakistan Brain Tumour Epidemiology Study. *J Pak Med Assoc* 2022;72(Suppl 4):s4-11. doi: 10.47391/JPMA.11-S4-AKUB01.
10. Bajwa MH, Shah MM, Khalid MU, Khan AA, Zahid N, Anis SB, et al. Distance travelled for brain tumour surgery: An Low and Middle Income Country's perspective. *J Pak Med Assoc* 2022;72(Suppl 4):s25-33. doi: 10.47391/JPMA.11-S4-AKUB04.
11. Bajwa MH, Khalid MU, Shah MM, Shamim MS, Laghari AA, Akhuzada NZ, et al. Treatment patterns of glioma in Pakistan: An epidemiological perspective. *J Pak Med Assoc* 2022;72(Suppl 4):s34-9. doi: 10.47391/JPMA.11-S4-AKUB05.
12. Shah MM, Khalid MU, Bajwa MH, Mirza FA, Anis SB, Akhuzada NZ, et al. Gender disparities in brain tumours: A Pakistan brain tumour epidemiology study analysis. *J Pak Med Assoc* 2022;72(Suppl 4):s79-84. doi: 10.47391/JPMA.11-S4-AKUB13.
13. Oppenlander ME, Wolf AB, Snyder LA, Bina R, Wilson JR, Coons SW,

- et al. An extent of resection threshold for recurrent glioblastoma and its risk for neurological morbidity. *J Neurosurg* 2014;120:846-53. doi: 10.3171/2013.12.JNS13184.
14. Zebian B, Vergani F, Lavrador JP, Mukherjee S, Kitchen WJ, Stagno V, et al. Recent technological advances in pediatric brain tumor surgery. *CNS Oncol* 2017;6:71-82. doi: 10.2217/cns-2016-0022.
  15. Khan MK, Hunter GK, Vogelbaum M, Suh JH, Chao ST. Evidence-based adjuvant therapy for gliomas: current concepts and newer developments. *Indian J Cancer* 2009;46:96-107. doi: 10.4103/0019-509x.49147.
  16. Helal AE, Abouzahra H, Fayed AA, Rayan T, Abbassy M. Socioeconomic restraints and brain tumor surgery in low-income countries. *Neurosurg Focus* 2018;45:E11. doi: 10.3171/2018.7.FOCUS18258.
  17. Khan SA, Nathani KR, Ujjan BU, Barakzai MD, Enam SA, Shafiq F. Awake craniotomy for brain tumours in Pakistan: An initial case series from a developing country. *J Pak Med Assoc* 2016;66(Suppl 3):s68-71.
  18. Bakhshi SK, Jawed N, Shafiq F, Enam SA. Awake Craniotomy for Resection of Intracranial Meningioma: First Case Series From a Low- and Middle-Income Country. *Cureus* 2021;13:e18716. doi: 10.7759/cureus.18716.
  19. Mofatteh M, Mashayekhi MS, Arfaie S, Adeleye AO, Jolayemi EO, Ghoms NC, et al. Awake Craniotomy in Africa: A Scoping Review of Literature and Proposed Solutions to Tackle Challenges. *Neurosurgery* 2023;93:274-91. doi: 10.1227/neu.0000000000002453.
  20. Figueredo LF, Shelton WJ, Tagle-Vega U, Sanchez E, de Macedo Filho L, Salazar AF, et al. The state of art of awake craniotomy in Latin American countries: a scoping review. *J Neurooncol* 2023;164:287-98. doi: 10.1007/s11060-023-04433-0.
  21. Mariotto AB, Yabroff KR, Shao Y, Feuer EJ, Brown ML. Projections of the cost of cancer care in the United States: 2010-2020. *J Natl Cancer Inst* 2011;103:117-28. doi: 10.1093/jnci/djq495.
  22. Pierson L, Verguet S. When should global health actors prioritise more uncertain interventions? *Lancet Glob Health* 2023;11:e615-22. doi: 10.1016/S2214-109X(23)00055-4.
  23. Tebha SS, Ali Memon S, Mehmood Q, Mukherjee D, Abdi H, Negida A. Glioblastoma management in low and middle-income countries; existing challenges and policy recommendations. *Brain Spine* 2023;3:101775. doi: 10.1016/j.bas.2023.101775.
  24. Abdullah UEH, Laghari AA, Khalid MU, Rashid HB, Jabbar AA, Mubarak F, et al. Current management of glioma in Pakistan. *Glioma* 2019;2:139-44. DOI: 10.4103/glioma.glioma\_15\_19.
  25. Khalid MU, Bajwa MH, Shah MM, Zafar SN, Laghari AA, Akhunzada NZ, et al. Factors associated with lost to follow up in patients with brain tumours: A multi-centre study in Pakistan. *J Pak Med Assoc* 2022;72(Suppl 4):s16-24. doi: 10.47391/JPMA.11-S4-AKUB03.
  26. Punchak M, Mukhopadhyay S, Sachdev S, Hung YC, Peeters S, Rattani A, et al. Neurosurgical Care: Availability and Access in Low-Income and Middle-Income Countries. *World Neurosurg* 2018;112:e240-54. doi: 10.1016/j.wneu.2018.01.029.
  27. Bakhshi SK, Shah Z, Khalil M, Khan Mughal MA, Kazi AM, Virani QU, et al. Geographical Distribution of Neurosurgeons and Emergency Neurosurgical Services in Pakistan. *World Neurosurg* 2023;179:e515-22. doi: 10.1016/j.wneu.2023.08.133.
  28. Bajwa MH, Shah MM, Khalid MU, Shamim MS, Baig E, Akhunzada NZ, et al. Time to surgery after radiological diagnosis of brain tumours in Pakistan: A nationwide cross-sectional study. *J Pak Med Assoc* 2022;72(Suppl 4):s93-7. doi: 10.47391/JPMA.11-S4-AKUB15.
  29. Awan MM, Qureshi S, Khushnood K. Joint commission international accreditation: a breakthrough in Pakistan. *J Shifa Tameer-e-Millat Univ* 2020;3:136-7.
  30. Combi C, Pozzani G, Pozzi G. Telemedicine for Developing Countries. A Survey and Some Design Issues. *Appl Clin Inform* 2016;7:1025-50. doi: 10.4338/ACI-2016-06-R-0089.
  31. Latif A, Hussain SA, Atiq H, Zaki M, Khan H, Sami K, et al. 166: Clinical outcomes of critically ill covid-19 patients seen through tele-icu services in Pakistan. *Crit Care Med* 2022;50:67. DOI: 10.1097/01.ccm.0000806988.53685.19
  32. Yildiz F, Oksuzoglu B. Teleoncology or telemedicine for oncology patients during the COVID-19 pandemic: the new normal for breast cancer survivors? *Future Oncol* 2020;16:2191-5. doi: 10.2217/fo-2020-0714.
  33. Mohanty A, Srinivasan VM, Burkhardt JK, Johnson J, Patel AJ, Sheth SA, et al. Ambulatory neurosurgery in the COVID-19 era: patient and provider satisfaction with telemedicine. *Neurosurg Focus* 2020;49:E13. doi: 10.3171/2020.9.FOCUS20596.
  34. Daggubati LC, Eichberg DG, Ivan ME, Hanft S, Mansouri A, Komotar RJ, et al. Telemedicine for Outpatient Neurosurgical Oncology Care: Lessons Learned for the Future During the COVID-19 Pandemic. *World Neurosurg* 2020;139:e859-63. doi: 10.1016/j.wneu.2020.05.140.
  35. Bell JS, Koffie RM, Rattani A, Dewan MC, Baticulon RE, Qureshi MM, et al. Global incidence of brain and spinal tumors by geographic region and income level based on cancer registry data. *J Clin Neurosci* 2019;66:121-7. doi: 10.1016/j.jocn.2019.05.003.
  36. Santosh V, Sravya P, Gupta T, Muzumdar D, Chacko G, Suri V, et al. ISNO consensus guidelines for practical adaptation of the WHO 2016 classification of adult diffuse gliomas. *Neurol India* 2019;67:173-82. doi: 10.4103/0028-3886.253572.
  37. Hassen WA, Karsan FA, Abbas F, Beduk Y, El-Khodary A, Ghosn M, et al. Modification and implementation of NCCN guidelines on prostate cancer in the Middle East and North Africa region. *J Natl Compr Canc Netw* 2010;8(Suppl 3):s26-8. doi: 10.6004/jnccn.2010.0121.
  38. Mushtaq N, Mustansir F, Minhas K, Usman S, Qureshi BM, Mubarak F, et al. Building the ecosystem for pediatric neuro-oncology care in Pakistan: Results of a 7-year long twinning program between Canada and Pakistan. *Pediatr Blood Cancer* 2022;69:e29726. doi: 10.1002/pbc.29726.
  39. Altaf A, Baqai MWS, Urooj F, Alam MS, Aziz HF, Mubarak F, et al. Utilization of an ultra-low-field, portable magnetic resonance imaging for brain tumor assessment in lower middle-income countries. *Surg Neurol Int* 2023;14:260. doi: 10.25259/SNI\_123\_2023.

**DISCLAIMER**

Articles published in JPMA and Supplements of JPMA do not represent the views of the editor or editorial Board. Authors are solely responsible for the opinions expressed and the accuracy of the data.

The contribution of each author towards the published research included in this supplement is the responsibility of the authors and their institutions.

It is expected to be in accordance and compliance with the ICMJE Guidelines.

Any questions/queries raised by readers should be directed to the corresponding author.

## NARRATIVE REVIEW

## Role of neurosurgeons In strengthening paediatric neuro-oncology In low- and middle-income countries: a narrative review with case examples

Ahsan Ali Khan<sup>1</sup>, Mohammad Hamza Bajwa<sup>2</sup>, Naureen Mushtaq<sup>3</sup>, Muhammad Osama<sup>4</sup>, Afia Arif<sup>5</sup>, Saqib Kamran Bakhshi<sup>6</sup>, Michael C. Dewan<sup>7</sup>, Kee B Park<sup>8</sup>, Eric Bouffet<sup>9</sup>, Syed Ather Enam<sup>10</sup>

### Abstract

Paediatric neuro-oncology in low- and middle-income countries (LMICs) accounts for a significant proportion of cancer-related mortalities in this age group. The current dearth of structured paediatric neurosurgery training programmes in LMICs requires multidisciplinary coordination; neurosurgeons play certain key roles, as discussed in this article, in ensuring safe and effective care for paediatric neuro-oncology patients. This document intends to elaborate through illustrative cases of the technical and structural nuances required by neurosurgeons in LMICs to provide appropriate surgical care.

**Keywords:** Neuro-oncology, neurosurgery, Neoplasms

**DOI:** <https://doi.org/10.47391/JPMA.S3.GNO-05>

### Introduction

Paediatric central nervous system tumours (CNSTs) are 15-20% of all paediatric population tumours and are the second most common neoplasm within children after leukaemia.<sup>1</sup> These are the first cause of mortality in paediatric patients with cancer. Within high-income countries (HICs), advances in neurosurgical interventions, neuro-imaging, and histopathological classifications have guided treatment algorithms and improved 5 year progression free survival rates for children with CNSTs to rates as high as 70 - 80%.<sup>2</sup> Unfortunately, more than 80% of the world's children live in low- and middle-income countries (LMICs) where the 5 year progression-free survival for such patients is often between 0 - 40%.<sup>3,4</sup> Studies have identified causes of this to include lack of multimodal infrastructure in paediatric care, evidence-

based treatments, and interdisciplinary collaborations with a focus on neuro-oncology.<sup>5</sup> Training in neuro-oncology is also severely lacking.<sup>6</sup> Ultimately, this demands a multidisciplinary approach with involvement of experienced paediatric neurosurgeons, neuro-radiologists, neuro-oncologists, radiation oncologists, and neuro-pathologists; there is a dearth of such specialists in most LMICs.<sup>7</sup>

In 2014, it was reported that there were only 35 neurosurgical centres in Pakistan, and only one neurosurgeon per 1.37 million people within the country. As the population is expected to grow rapidly, this already insufficient neurosurgical capacity will be further burdened.<sup>8</sup> A similar case can be seen in Africa where an approximately one billion people are covered by an estimated 1200 neurosurgeons. Only 142 are located in sub-Saharan Africa (excluding South Africa) which means for every five million people there is one neurosurgeon catering to their needs.<sup>9</sup> If we look to Southeast Asia, the WHO estimates that there is approximately one neurosurgeon per three million people, and for Eastern Europe and the Western Pacific there is approximately one neurosurgeon per 250,000.<sup>10</sup> We can contrast this with more equitable ratios seen within Europe (1:121,000) and North America (1:81,000); overall the ratio of neurosurgeons to the world population is 1:230,000.<sup>11</sup>

**Table-1:** Summary of recommendations.

#### Roles of neurosurgeons in paediatric neuro-oncology in LMICs

Role in appropriate acute management  
*definitive surgery was indicated with a focus on improving patient outcomes*  
 Developing training programmes  
*dedicated paediatric neurosurgical experience and training programmes*  
 Twinning programs  
*collaborations with international centres of excellence in diagnosis and treatment of cases*  
 Paediatric neuro-oncology tumour boards  
*multi-disciplinary, holistic care and following up patients after surgery*  
 Communication and counselling  
*considering situations of patients and their families to tailor care*  
 Research and development  
*research infrastructure for generating evidence for best-practice guidelines in LMICs*

---

LMICs-Low and Middle Income Countries.

<sup>1,2,6,10</sup>Department of Neurosurgery, The Aga Khan University, Karachi, Pakistan. <sup>3,5</sup>Department of Paediatric Oncology, The Aga Khan University, Karachi, Pakistan. <sup>4</sup>Dr Ruth K. M. Pfau, Civil Hospital Karachi, Pakistan. <sup>7</sup>Department of Neurosurgery, Vanderbilt University Medical Centre, Nashville, USA. <sup>8</sup>Department of Global Health and Social Medicine, Harvard Medical School, Boston, USA. <sup>9</sup>Division of Haematology Oncology, The Hospital for Sick Children, Toronto, Canada.

**Correspondence:** Syed Ather Enam **Email:** [ather.enam@aku.edu](mailto:ather.enam@aku.edu)

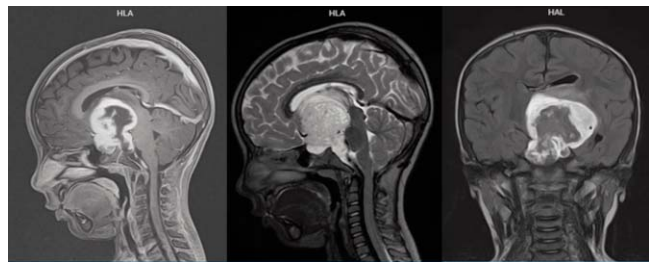
In this paper, we intend to highlight and address the important roles of a neurosurgeon as a key member of a multidisciplinary approach towards paediatric neuro-oncology and the role of neurosurgeons in strengthening this challenging area in LMICs (Table 1).

### Role in appropriate acute management

Decision making by neurosurgeons is crucial in the management of paediatric brain tumours. Hydrocephalus is a common presentation in children with brain tumours and it is common for neurosurgeons without an understanding of paediatric brain tumours' management to immediately place a Ventriculo-peritoneal shunt (VPS) for symptomatic relief. While a shunt can ameliorate the acute symptoms, it does not address the underlying cause and makes definitive surgery technically challenging. Families of patients with no understanding of the disease and necessary repeat interventions are often lost to follow-up once they see symptomatic improvement. The majority of paediatric tumours causing hydrocephalus reside in the posterior fossa. Only a third of patients who undergo posterior fossa tumour resection ultimately develop persistent hydrocephalus requiring permanent cerebrospinal fluid diversion.<sup>12</sup> Thus, shunting up-front unnecessarily exposes most patients not only to an additional, superfluous surgery, but also commits such patients to the life-long morbidity associated with VPS. In other circumstances, neurosurgeons lacking skills and training can deny an intervention when the tumour can be removed safely. Knowing when to operate and when not to operate can change the whole picture. Unnecessary interventions not only lead to increased morbidity rather they also overburden the system which is quite inadequate. Similarly, not being able to operate when it is indicated, results in disastrous outcomes as well.

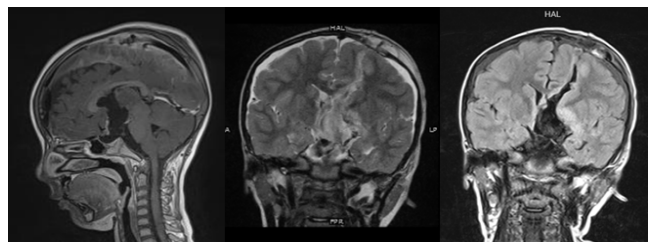
### Case example

A 5 ½ year old boy presented to The Aga Khan University neurosurgery clinic, Karachi with the complaints of drowsiness and progressively worsening vision in his right eye for the past 1 month. He was initially taken to a public-sector hospital, where after being diagnosed with hydrocephalus secondary to a suprasellar mass, his team decided against surgical resection due to the complexity of the case. A VPS was inserted in January 2021. Afterwards, his drowsiness improved and was discharged from the hospital with no intent for further surgical intervention, despite the present tumour. At our clinic, he had difficulty seeing with his right eye with no other focal neurological deficits. An MRI scan of brain showed a large, heterogeneous, partially circumscribed, multilobulated lesion with its epicentre in the suprasellar region (Figure



**Figure-1:** A 5 ½ year-old boy with a large lesion showing extension into the sella with suprasellar expansion, with compression of the midbrain. Histopathology reported this as pilocytic astrocytoma (WHO Grade I).

1). The lesion also showed extension into the sella with suprasellar expansion, with effacement of the pituitary gland, superior extension along the floor of the third ventricle and significant mass effect on the brainstem and left thalamus. The mass was encasing both common carotid arteries and abutting the basilar artery. In comparison to previous scans, there was progression of the disease. He was admitted for surgery for a presumed suprasellar pilocytic astrocytoma. Chemotherapy as an alternative to surgery was discussed, however, the multidisciplinary team decided to opt for surgical resection. Initially, there was a plan for endoscopic resection of the tumour; however due to decompression by the shunt, this was deemed too difficult. He thus underwent neuro-navigation guided supratentorial craniotomy and maximum safe resection of the sellar and parasellar tumour (Figure 2). Postoperatively, he developed right upper and limb weakness of 1/5 and mild right sided facial nerve palsy. However, these gradually improved with physiotherapy and time. After a prolonged hospital stay, he was eventually discharged in a neurologically stable condition. Final histopathology report showed pilocytic astrocytoma WHO grade I. In the follow-up multidisciplinary tumour board, it was decided that he would be continued on surveillance MRI scans.



**Figure-2:** Immediate postoperative MRI scan showing near-total resection of the tumour.

This proved to be an excellent case for highlighting the importance of decision-making by the neurosurgeon in resection of a difficult pathology, with great postoperative outcomes for a young patient, rather than

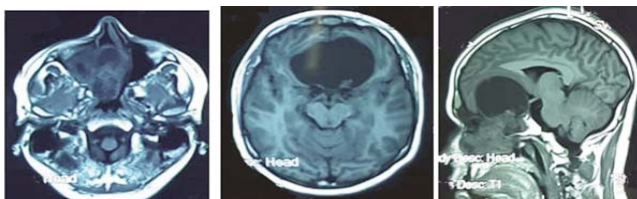
leaving him with a shunt and waiting for disease progression.

### Twinning programmes

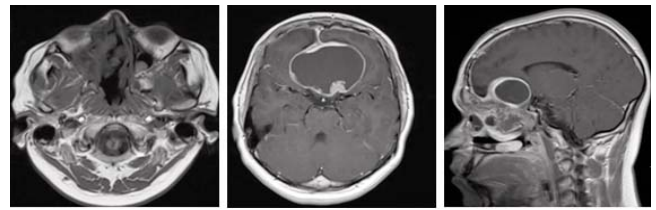
Twinning programmes between hospitals in HIC and LMIC have improved outcomes in the paediatric brain tumours management in LMICs.<sup>1</sup> Such collaborations are also helpful in capacity building of the facilities in LMIC. However, there is a need of similar collaborations between the hospitals within the LMICs. Tertiary care hospitals providing care to paediatric brain tumour patients should have collaborations with hospitals lacking such facilities. Paediatric patients are first seen by paediatricians and it is important for paediatric hospitals to have access to consult and refer their patients to more sophisticated hospitals where definitive treatment can be done. A peer-to-peer training can also be part of such collaborations of hospitals in LMICs. In such settings, neurosurgeons working in limited resources and having limited experience of paediatric neuro-oncology can be invited to the centres where they can attend workshops, seminars, observe surgeries, communicate with trained paediatric neurosurgeons and experts of the other areas involved in paediatric neuro-oncology. Such training programmes can also play a part in filling the gaps, capacity building and improving the overall management in limited resource settings. By developing capacity through virtual presence technology, satellite centres across the country can be linked with high-volume, academic centres and conduct remote training modules emphasizing paediatric neurosurgical procedures.

### Case example

An 18 year-old male presented with history of right eye visual deterioration and hyposmia for 3 months associated with sneezing and snoring. On examination there was finger counting in left eye only and in right eye there was only light perception. His MRI brain with contrast (Figure 3) showed a solid-cystic lesion with calcification involving right maxillary sinus extending superiorly into anterior cranial fossa up to nasopharynx, sellar and supra sellar region resulting in bony erosion and destruction leading to superior displacement of both

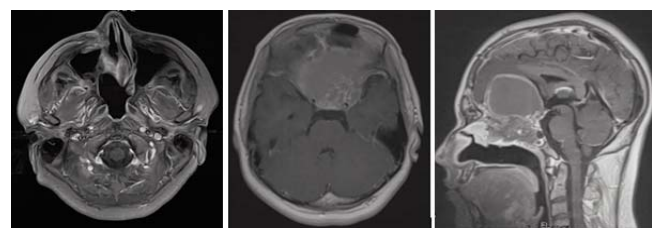


**Figure-3:** An 18-year-old patient with a large, heterogeneous, solid-cystic lesion. This was an adamantinoma Tous craniopharyngioma (BRAF V600E negative).



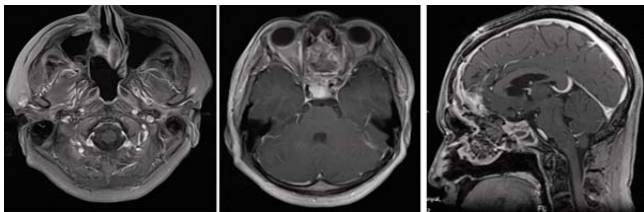
**Figure-4:** Post-op MRI (6-months post-op) shows debulking of the nasal component of the lesion. There is a large intracranial and paranasal sinus residual disease which appears grossly unchanged.

anterior cerebral arteries and bilateral thalamic arteries. He underwent bi-frontal craniotomy and excision of extra-axial skull base lesion and right lateral rhinotomy plus excision of nasal lesion. Vision improved post-operatively in both eyes. Histopathology demonstrated adamantinoma Tous craniopharyngioma WHO grade I. His first post-operative scan (Figure 4) was done after 6 months due to the COVID-19 pandemic and showed significant progression of the disease. There was interval increase in size of infiltrative solid-cystic neoplastic lesion at the floor of anterior cranial fossa that increased from 68 x 53 mm to 76 x 60 mm in maximum trans-axial dimensions. There was interval development of haemorrhage/accumulation of proteinaceous material within the cystic component of the lesion (Figure 5). Clinically, there was weight gain and visual deterioration in this time span. The case was discussed in our monthly Paediatric Neuro-oncology tumour board with international faculty of SickKids hospital, Toronto, Canada. Tumour board recommended careful safe surgical resection and histopathology review with BRAF V600E. Intracystic treatment may have been discussed as an alternative therapy, however, was not discussed further. In our centre, immunohistochemical staining of BRAF V600E is not available. Therefore, the sample was sent to SickKids hospital and it turned out to be negative. Re-resection of the lesion was done. Neuro-navigation guided bi-frontal craniotomy and extradural resection of anterior skull base lesion was done via lateral rhinotomy approach along with ethmoidectomy and resection and reconstruction of sphenoid. Post-operatively patient



**Figure-5:** Follow-up post-op MRI showing interval increase in size of infiltrative solid cum cystic neoplastic lesion at the floor of anterior cranial fossa.





**Figure-6:** After the second surgery, the patient was followed for residual disease (abnormal cystic area) in left parasellar region with an abnormal enhancing lesion along the antero-inferior aspect of the sella.

remained stable and there were no complications related to surgery. Follow-up MRI scans after second surgery showed some residual disease (Figure 6) and this patient is on regular follow up, doing well with a normal endocrine profile. His vision has also improved.

This case is an example of how international twinning programmes between two hospitals can help in tailoring the management plan with favourable outcomes. Such collaborations can be done within LMICs as well for capacity building.

### Paediatric neuro-oncology multidisciplinary tumour boards (PNTBs)

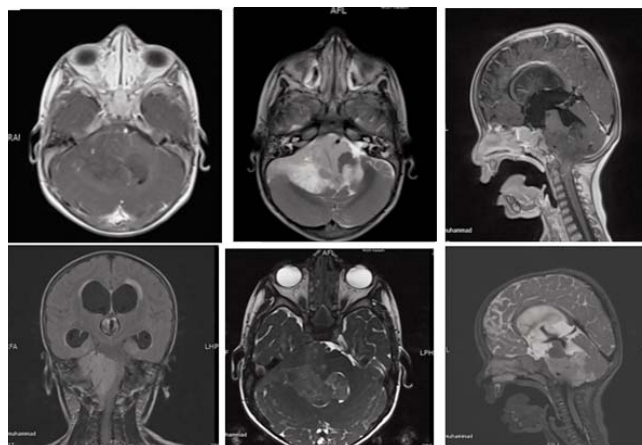The management of paediatric brain tumours is a highly demanding task in LMICs as it requires a multi-disciplinary approach. A team of well-trained neurosurgeons, neuropathologists, medical and radiation oncologists, well-trained nursing staff, psychiatrists, rehabilitants, and physiotherapists are needed for a comprehensive management of the malignancy.<sup>5</sup> Despite the recent developments of various tumour programmes in LMICs, the mortality of children has failed to improve significantly because of the non-implementation of this multi-disciplinary approach, primarily because of lack of trained doctors and staff, infrastructural short-comings, and management inefficiency at public sector hospitals in LMICs. Lack of experts in paediatric cancer is a modifiable factor in the establishment of a multi-disciplinary system for paediatrics tumour management.

Regular multidisciplinary tumour board meetings play an important and crucial role in deciding the best management plan. A majority of the hospitals in LMICs lack such board meetings and there is extremely limited communication between neurosurgeons and other experts. An aggressive approach to include maximum number of centres lacking tumour boards can be taken. In this way, different centres in LMICs providing care to the paediatric brain tumour patients can be part of virtual multidisciplinary meetings of more sophisticated hospitals where tumour board is being done regularly

and experts from these well-established centres can provide consultancy to the other less developed facilities

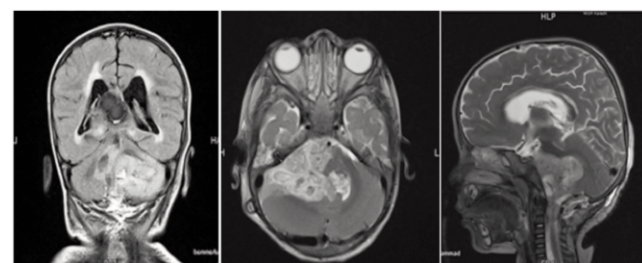
### Case example

A 3 ½ years-old boy presented initially at the age of 18 months with history of excessive cry, neck stiffness for 3 months and difficulty in walking, and vomiting for 15 days. There was no history of seizures or drowsiness. On examination, he was conscious, irritable, and vitally stable

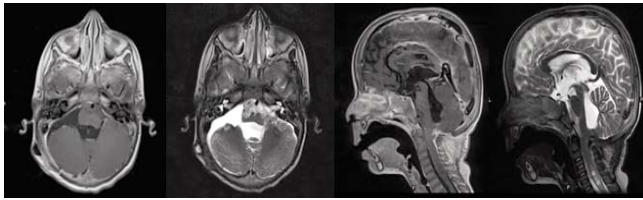


**Figure-7:** A 3.4-year-old boy with a large abnormal signal lesion in the posterior fossa likely arising from the floor of fourth ventricle, encasing basilar artery and extending up to pre-pontine cistern. Histopathology reported this as an Anaplastic Ependymoma, with loss of H2K27me3 molecular subgroup PF A subtype.

with no neurologic deficit. MRI brain (Figure 7) revealed a large posterior fossa lesion extending to pre-pontine cistern and up to C-2 level of spine. Rest of the spine was normal. He underwent a suboccipital craniotomy for tumour resection and insertion of VPS in December 2018. Post-op MRI brain and whole spine showed significant residual disease (Figure 8). Histopathology was consistent with Anaplastic Ependymoma with loss of H2K27me3 molecular subgroup PFA subtype. He underwent another surgical resection (right retro sigmoid craniotomy and tumour resection) in January 2019. Post-operative scan after second surgery (Figure 9) showed some residual



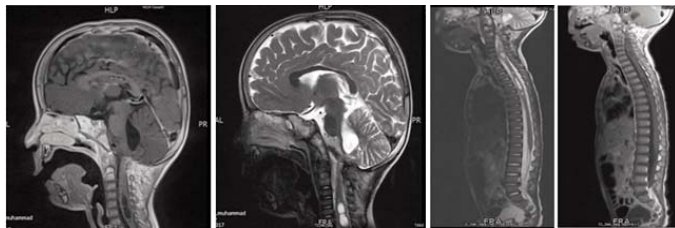**Figure-8:** Post-operative MRI brain shows large posterior fossa mass extending into the cervical spinal canal up to the C2 vertebral body level.



**Figure-9:** Post-op MRI brain after second surgery. Residual tumour can be seen in front of medulla oblongata and upper cervical cord starting from dens and to level of clivus suggestive of residual tumour.

disease and after discussing this case in the neuro-oncology tumour board with AKUH, Karachi and Sickkids Hospital, Toronto, Canada, it was decided to proceed with focal radiation. He received focal radiation, under general anaesthesia, in a dose of 59.4Gy in 33 fractions @1.8 Gy per fraction. Since then, he is on regular follow ups for the last 2.5 years and recent MRI showed no disease progression (Figure 10).

This case is an example of how complex cases can be handled efficiently with multidisciplinary approach.



**Figure-10:** Post-radiation follow-up MRI.

## Communication and counselling

Clear communication between neurosurgeons, experts of other disciplines and the families of patients is extremely important in paediatric neuro-oncology. This is due to two reasons: the exorbitant cost of care, and a need for families to understand risks, options, and prognosis of patients in order to make informed decisions.<sup>13</sup> The treatment of paediatric brain tumours is a financially draining process particularly in countries lacking universal health insurance and full coverage for childhood cancer services<sup>3</sup>. A study reported that 50% of the families having a patient of paediatric brain tumours had such a drastic decrease in the total house-hold income that it resulted in the family's socioeconomic status falling into the poverty line.<sup>13</sup> Furthermore, almost 1/3<sup>rd</sup> of the parents and family members reported that they felt they were not fully involved in their child's care during the treatment process,<sup>14</sup> and many were reluctant to discuss end-of-life and palliative care topics with their health care provider due to a conservative family background.<sup>15</sup>

Neurosurgeons have the advantage of experience with such patients and their outcomes and spending considerable time with patients' families with clear outlines and expectations can improve the overall experience they have with the healthcare system. Especially with palliative care, it helps for families to be able to question and hear reliable data from the neurosurgeon handling their child, and thus help come to terms with such realities.

## Research and development

There a large disparity between HICs and LMICs in the number of clinical trials and clinical guidelines developed, especially with regards to paediatric neuro-oncology.<sup>13</sup> Making decisions within LMICs settings requires a different understanding of the various socioeconomic and infrastructural differences present as well as a different evidence base. Ultimately, it is researchers and institutions based within LMICs that would have the best vantage point for investigating and researching LMICs paediatric neuro-oncology patients.

Most paediatric neuro-oncology guidelines are developed in HICs and practitioners in LMICs struggle to format these recommendations to their contexts. Neurosurgeons should take charge and develop research protocols that will investigate patient populations within LMICs.<sup>15</sup> With consensus from other specialists in the multidisciplinary team, we can develop guidelines that are geared towards the context and infrastructural capabilities of LMICs. Data from LMICs will provide a new perspective to the concept of global neurosurgery and neuro-oncology and provide us with the best-practice guidelines for paediatric neuro-oncology patients.

Grants for the development of paediatric neuro-oncology capacity within LMICs, such as the My Child Matters initiative taken by the Sanofi Espoir Foundation, help to reduce disparities in access to care and lack of clinical guidelines. Through regional collaborations, this initiative has been able to create networks for helping paediatric patients' access quality care and develop clinical guidelines for resource-constrained settings. Training programmes in the paediatric neuro-oncology can then further help establish the next generation of paediatric neurosurgeons in LMICs, poised to expertly handle paediatric brain tumours and deliver the care our patients ultimately deserve.

## Conclusion

These guidelines have been designed to assist physicians operating in settings with limited resources. They offer a practical framework drawn from extensive experience

and have the potential to bring about notable improvements in specific outcomes. The objective is to foster a greater emphasis on multidisciplinary care within low- and middle-income countries (LMICs), such as Pakistan, by providing a valuable roadmap for implementation

**Disclaimer:** None.

**Conflict of Interest:** None.

**Funding Disclosure:** None.

## References

- Aristizabal P, Burns LP, Kumar NV, Perdomo BP, Rivera-Gomez R, Ornelas MA, et al. Improving Pediatric Neuro-Oncology Survival Disparities in the United States-Mexico Border Region: A Cross-Border Initiative Between San Diego, California, and Tijuana, Mexico. *JCO Glob Oncol* 2020;6:1791-802. doi: 10.1200/GO.20.00377
- Gupta T, Achari R, Chatterjee A, Chen ZP, Mehta M, Bouffet E, et al. Comparison of Epidemiology and Outcomes in Neuro-Oncology Between the East and the West: Challenges and Opportunities. *Clin Oncol (R Coll Radiol)* 2019;31:539-48. doi: 10.1016/j.clon.2019.05.018
- Helal AE, Abouzahra H, Fayed AA, Rayan T, Abbassy M. Socioeconomic restraints and brain tumor surgery in low-income countries. *Neurosurg Focus* 2018;45:E11. doi: 10.3171/2018.7.FOCUS18258
- Ribeiro RC, Steliarova-Foucher E, Magrath I, Lemerle J, Eden T, Forget C, et al. Baseline status of paediatric oncology care in ten low-income or mid-income countries receiving My Child Matters support: a descriptive study. *Lancet Oncol* 2008;9:721-9. doi: 10.1016/S1470-2045(08)70194-3
- Chan MH, Boop F, Qaddoumi I. Challenges and opportunities to advance pediatric neuro-oncology care in the developing world. *Childs Nerv Syst* 2015;31:1227-3. doi: 10.1007/s00381-015-2771-x
- Bailey S, Parkes J, Davidson A. Global Challenges in Pediatric Neuro-Oncology. In: Gajjar A, Reaman GH, Racadio JM, Smith FO, eds. *Brain Tumors in Children*. Cham, Switzerland: Springer International Publishing AG, 2018; pp 403-26. Doi: 10.1007/978-3-319-43205-2
- Friedrich P, Ortiz R, Fuentes S, Gamboa Y, Ah Chu-Sanchez MS, Arambú IC, et al. Barriers to effective treatment of pediatric solid tumors in middle-income countries: can we make sense of the spectrum of nonbiologic factors that influence outcomes? *Cancer* 2014;120:112-25. doi: 10.1002/cncr.28339
- Khan MB, Kumar R, Irfan FB, Irfan AB, Bari ME. Civilian craniocerebral gunshot injuries in a developing country: presentation, injury characteristics, prognostic indicators, and complications. *World Neurosurg* 2014;82:14-9. doi: 10.1016/j.wneu.2013.01.026
- Albright AL, Ferson SS. Developing pediatric neurosurgery in a developing country. *J Child Neurol* 2012;27:1559-64. doi: 10.1177/0883073812460586
- Bergen DC. IN17-MO-01 WHO/WFN Atlas of country resources for Neurological disorders. *J Neurol Sci* 2009;285(Suppl 1):s16. doi: 10.1016/S0022-510X(09)70078-4
- Kalangu KK. Pediatric neurosurgery in Africa--present and future. *Childs Nerv Syst* 2000;16:770-5. doi: 10.1007/s003810000343
- Riva-Cambrin J, Detsky AS, Lamberti-Pasculli M, Sargent MA, Armstrong D, Moineddin R, et al. Predicting postresection hydrocephalus in pediatric patients with posterior fossa tumors. *J Neurosurg Pediatr* 2009;3:378-85. doi: 10.3171/2009.1.PEDS08298
- Griswold DP, Khan AA, Chao TE, Clark DJ, Budohoski K, Devi BI, et al. Neurosurgical Randomized Trials in Low- and Middle-Income Countries. *Neurosurgery* 2020;87:476-83. doi: 10.1093/neuros/nyaa049
- Waqas M, Siddiqui UT, Shamim MS. Follow-Up Bibliometric Analysis of Neurosurgical Publications from Pakistan and Institutional Comparison with other Countries Using h-Index and i-10 Index. *Asian J Neurosurg* 2019;14:126-30. doi: 10.4103/ajns.AJNS\_286\_17
- Black PM. Challenges in contemporary academic neurosurgery. *Neurosurgery* 2006;58:419-25. doi: 10.1227/01.NEU.0000197139.61412.36

### DISCLAIMER

Articles published in JPMA and Supplements of JPMA do not represent the views of the editor or editorial Board. Authors are solely responsible for the opinions expressed and the accuracy of the data.

The contribution of each author towards the published research included in this supplement is the responsibility of the authors and their institutions. It is expected to be in accordance and compliance with the ICMJE Guidelines.

Any questions/queries raised by readers should be directed to the corresponding author.

## Serum liquid biopsy for brain tumours: a scoping analysis of practicable approaches in low- and middle-income countries

Mohammad Hamza Bajwa<sup>1</sup>, Muhammad Awais Khan<sup>2</sup>, Faiza Urooj<sup>3</sup>, Muhammad Usman Khalid<sup>4</sup>, Syed Ather Enam<sup>5</sup>, Hafiza Fatima Aziz<sup>6</sup>, Kaynat Siddiqui<sup>7</sup>, Muhammad Ehsan Bari<sup>8</sup>, Nouman Mughal<sup>9</sup>

### Abstract

Approaches to brain tumour diagnosis and detecting recurrence after treatment are costly and significantly invasive. Developing peripheral-sample liquid biopsy tools is the key to enhancing our ability to prognosticate brain tumour subtypes and molecular heterogeneity. The present scoping review was designed to discuss current updates in liquid biopsy tools for diagnosis and guiding clinical management of brain tumours; we evaluated the literature within the context of low-and-middle-income country challenges. Circulating tumour cells (CTCs), circulating tumour DNA (ctDNA), cell-free DNA (cfDNA), extracellular vesicle-associated biomarkers, protein biomarkers, microRNAs, and serum metabolites are discussed with the collation of current data supporting their utility in liquid biopsy. Further challenges to implanting liquid biopsy tools at a systematic level are highlighted.

**Keywords:** Tumour, DNA, Neoplastic Cells, Liquid Biopsy, Brain Neoplasms, MicroRNAs, Extracellular Vesicles

**DOI:** <https://doi.org/10.47391/JPMA.S3.GNO-06>

### Introduction

Brain tumours are a burgeoning healthcare issue within low-and-middle-income countries (LMICs) due to costs associated with treatment, response assessment, and follow-ups.<sup>1</sup> These tumours are genetically heterogenous and require precise molecular characterisation for targeted therapy. Many resource-constrained healthcare systems cannot afford to provide adequate and continued care to patients, many of whom live in the global south. Data from South Asia shows many patients abandon post-surgical chemotherapy and radiation

.....

<sup>1,3-8</sup>Department of Neurosurgery, The Aga Khan University, Karachi, Pakistan.<sup>2</sup>Khyber Medical College, Peshawar, Pakistan. <sup>9</sup>Department of Biological and Biomedical Sciences, The Aga Khan University, Karachi, Pakistan.

**Correspondence:** Nouman Mughal

**Email:** [muhammad.nouman@aku.edu](mailto:muhammad.nouman@aku.edu)

treatment and are lost-to-follow-up, adding to the overall morbidity and mortality.<sup>2-4</sup> A significant barrier to follow-up is the considerable distance from neurosurgical access within LMICs; a recent study from Pakistan indicated that 59% of patients had to travel over 50 km for neuro-oncological surgery, with 15.7% travelling over 500 km.<sup>4</sup> Radiological imaging can be used for diagnosing based on tumour location, morphology, and signal intensity; however, there is limited information about molecular features, which are essential for treatment. Currently, molecular characteristics can be identified after surgery based on brain tissue which can prolong and significantly impact the initiation of adjuvant treatment.

Moreover, postoperative radiology cannot definitively quantify tumour recurrence and differentiate it from pseudo-progression.<sup>5,6</sup> The high cost of imaging results in treatment delays in many parts of the world.<sup>7</sup> The brain is a difficult-to-access organ for tissue diagnosis; repeat biopsies and molecular assessment of the evolving tumour and peri-tumoral region are not feasible.

Through the detection of materials shed by tumours, including circulating tumour cells (CTCs) and genomic specimens in bio-fluids (e.g., blood and cerebrospinal fluid), we can identify biomarkers that reflect tumour microenvironment and dynamic evolution in real-time.<sup>8</sup> The high specificity and sensitivity of this liquid biopsy (LB) can potentially reduce the financial burden and aid the expanding the role of molecular characterisation in prognosticating brain tumours. LB is a robust and minimally invasive screening tool allowing early tumour detection and reliable follow-up, whether this assessed treatment response, recurrence, or evolution of tumour biology. In CNS neoplasms, CSF is a source of molecular markers and can be used to track the evolution of gliomas.<sup>9,10</sup> However, the procedure to obtain CSF is invasive and risky in patients harbouring CNS tumours, which limits its use for serial assessment of the disease. In contrast, a liquid blood biopsy is minimally invasive, quick, and can be performed longitudinally within low-cost collection centres worldwide.

The use of blood-derived liquid biopsy is limited by the

minimal concentration of CNS tumour products due to the presence of the blood-brain barrier. Moreover, storage, and shipping can compromise the integrity of the biomolecule or biomarker, producing varying results. For example, the Ethylenediaminetetraacetate (EDTA) used to maintain blood longevity may cause genomic DNA contamination if stored for a long time. Due to prevalent issues in LMICs, such as poor transport facilities and limited standardized diagnostic facilities which can run genetic tests, the sample is unlikely to reach the diagnostic facility in good condition.

This review highlights the utility of liquid biopsy in diagnosing and guiding brain tumour treatment through a systematic review with scoping synthesis. We discuss the practicality from the standpoint of LMICs with the suggestion for further implementation.

## Methodology

To explore potential challenges in implementation of liquid biopsy for brain tumours, we aimed to conduct a scoping review of current literature with relevant exploration of current methods as well. This allows us to provide updated evidence on multiple facets of LB in brain tumours while exploring the systemic issues with implementation. A systematic literature search was conducted on 18/11/2022 using permutations of keywords, and similar terms, including “liquid biopsy”, “brain tumour” and “neuro-oncology”, using Scopus and PubMed (MEDLINE) databases – after removal of duplicates, a total of 706 articles were identified for title and abstract screening. This process was conducted in duplicate, leading to the inclusion of 46 articles for the present scoping review. Articles in non-English languages, reviews, other systematic review and meta-analyses, and articles that did not specify method of liquid biopsy used were not included in the review. Only data collected from human subjects was included. Data were collated and an expert review was made regarding utility and challenges faced by scientists in LMICs for implementing LB in neuro-oncology by the senior author.

## Liquid biopsy in the management of brain tumours

Genetic profile studies of tumour tissues have led to the discovery of biomarkers specific to tumour types. These include circulating tumour cells (CTCs), circulating tumour DNA (ctDNA), cell-free DNA (cfDNA), circulating proteins, extracellular vesicles and exosomes, long non-coding RNA (lncRNA), micro-RNA (miRNA) and other genetic alterations. LB methods intend to detect these genetic markers in peripheral bio-fluids to provide an alternative to the current gold standard of tissue biopsy and capture

the heterogeneity within the tumour.<sup>11</sup> Collated results are presented in Tables 1-3, discussing study design and outcomes presented.

## Circulating tumour cells

Serial tumour cells are routinely detected in CSF cytology for staging certain brain tumour types. Circulating tumour cells in the body fluids might indicate tumour metastasis and may be helpful in diagnosis, progression, and prognosis.<sup>12,13</sup> An essential advantage of CTCs over cfDNA or ctDNA is their longer half-life ranging from 1 - 2.4 hours if taken from the patient’s blood or CSF.<sup>14</sup> Besides pre-analytical pitfalls in handling the sample of body fluids, as described later, CTCs are present in low concentrations in the liquid biopsy samples, especially in early-stage tumours.<sup>15</sup> For example, in one study, only 29 (20%) of the cohort, including 141 GBM, had detectable CTCs, and in many cases, only one cell was found per 10 mL of blood per patient.<sup>16</sup> The discovery of new devices, such as the Cell Collector from GILUPI (GMBH, Potsdam, Germany), enables the isolation of circulating tumour cells directly from the arm vein of the patient may increase the concentration of CTCs achieved.<sup>17</sup>

## Ctdna and Cfdna

DNA is released from cells into body fluids by physiological and pathological cell death and is called (cfDNA).<sup>18,19</sup> Parts of cfDNA derived from the tumour cell are called circulating tumour DNA (ctDNA). The size of ctDNA ranges from 70 to 200 base pairs, a longer DNA fragment than normal cfDNA. They are also released randomly in micro-vesicles or exosomes and carried to other cells. Bagley et al. reported that cfDNA could be a prognostic tool in GBM patients and later confirmed it in another study with a larger independent patient cohort.<sup>20,21</sup>

Moreover, it has also been determined that an increase in cfDNA concentration from before surgery to post-adjuvant treatment is associated with worse progression-free survival (PFS) and overall survival (OS), suggesting that cfDNA dynamics during the treatment phase may have a role in determining therapeutic response in GBM.<sup>21</sup> García-Romero et al. isolated ctDNA, including EV-derived DNA, from 29 paediatric patients diagnosed with CNS tumours from serum, plasma, and CSF and showed that ctDNA found in serum and plasma could determine genetic characteristics of the tumour. They identified BRAF V600E mutations in both liquid biopsy sources.<sup>22</sup>

Diffuse midline gliomas are one of the most lethal due to their location, making it difficult to obtain tissue samples for biopsy with significant morbidity associated with surgical intervention. Cantor et al. demonstrated

**Table 1:** Studies regarding microRNA use as liquid biopsy tools.

First Author	Publish Year	Cancer Type	Controls	Patients / Controls	miRNAs	Detected Sample	Method Used	Summary
Hallal S. et al. <sup>47</sup>	2020	GBM	Astrocytoma II-III	12/5	miR-486-3p miR-106b-3p miR-378a-3p miR-21-5p miR-146b-5p miR-196b-5p miR-574-5p miR-222-3p miR-16-2-3p miR-193a-5p miR-5100 miR-335-5p (↑) miR-1306-3p (↓)	CUSA-EVs	NGS	Functional pathway analysis of mRNAs targeted by CUSA-EV miRNAs (212 species DE in GBM relative to GII-III; $p \leq 0.05$ ) shows clear associations to the GBM signaling pathway and more broadly, 'molecular mechanisms of cancer.'
Iannó M. F. et al. <sup>30</sup>	2022	Diffuse Intrinsic Pontine Glioma		47	miR-4714-3p miR-551b miR-4505 miR-6090 miR-6089 miR-3960 miR-936 miR-1207-5p miR-202-3p miR-3676-5p miR-4634 miR-4539 miR-4299 ((↑))	Serum		This study provides Class II evidence that a signature based on 13 circulating miRNAs is associated with the risk of disease progression.
Morokoff A. et al. <sup>31</sup>	2020	Glioma	Healthy controls	91/17	miR320e miR-223 miR-16-5p miR-484 miR520a miR-532 miR-630 miR651 miR-761	Serum exosomes and non-exosomes	ddPCR	This study reports the first systematic longitudinal study of serum microRNA biomarkers in glioma, finding that levels of miR-320e, miR-223 and miR-21 are correlated with tumor burden based on MRI.
Olioso D. et al. <sup>32</sup>	2021	GBM, Anaplastic Astrocytoma		57	miR-21 miR-222 miR-124-3p (↑)	Serum exosomes		No correlation found between exosomal miRNA expression and PFS or OS at the beginning of the study or after RT and first cycle of TMZ. Data reported in the study shows that exosomal miRNAs may predict response to therapy during follow-up in HGG patients.
Sippl C. et al. <sup>33</sup>	2022	GBM	Healthy Controls	60/30	miRNA-181d (↑)	Plasma	RT-qPCR	miRNA-181d plasma expressions has no significant impact on

Continued on next page...

Continued from previous page...

Swellam M. et al. <sup>34</sup>	2021	GBM	Healthy controls	25/20	miR-17-5p miR-125b miR-221 (↑)	Serum	RT-qPCR	survival or prognosis. However, some previous work shows that it has an impact on survival if local carmustine wafer therapy is applied.(48) An increase in serum miR-17-5p, miR-125b, and miR-221 levels in GBM patients is related to worse progression-free survival and overall survival.
Tomeva E. et al. <sup>49</sup>	2021	Brain cancer	Healthy controls (n=15), non-brain cancers (n=188)	9/203	miR-133a-3p miR-23a-3p (↑)	Serum	RT-qPCR	This study analyzed cell-free DNA (cfDNA) mutations and methylation, as well as circulating miRNAs (miRNAs) in plasma samples from 97 patients with cancer (bladder, brain, breast, colorectal, lung, ovarian, pancreas, prostate, stomach) and healthy controls.
Zhang H. et al. <sup>50</sup>	2019	GBM	Healthy controls	95/60	miRNA-100 (↑)	Serum	RT-qPCR	miR-100 expression levels is down-regulated in GBM compared to the healthy controls and closely correlated with shorter survival. Their levels is significantly increased following treatment indicating sensitivity to treatment response.

**Table-2:** EV as liquid biopsy.

First Author	Publish Year	Cancer Type	Patients	Control group	EV-associated biomarker	Alteration	Biological Sample	Methods of biomarker discovery	EV isolation Method	Summary
Batool SM. et al. <sup>25</sup>	2022	GBM	54	Healthy controls; EGFR mRNA wt patients	EGFRvIII		Plasma	ddPCR	ExoRNeasy	Establishes a sensitive plasma-based droplet digital PCR (ddPCR) assay for the detection of the EGFRvIII mutation in EV-derived RNA.
Bukva M. et al. <sup>51</sup>	2021	GBM	46	Lumber disc herniation patients; Other brain	Raman measurement		Serum	Raman spectroscopy	Differential Centrifugation	Results support that Raman spectroscopic

Continued on next page...

Continued from previous page...

tumors										
Cilibrasi C. et al. <sup>52</sup>	2022	GBM	15	Healthy controls	VWF; C3; FCGBP; PROS1; SERPINA1	Overexpression	Plasma	Mass spectrometry	Differential Ultracentrifugation	analysis of circulating sEV-enriched isolates is a promising method that could be used in the diagnosis of CNS tumors. Describes an inflammatory biomarker signature was in sEVs from GB patients.
Garcia L. et al. <sup>53</sup>	2019	GBM	19	Healthy controls	IFN- $\gamma$ ; IL-10; IL-3; CD80, CD86; ICOSL	Underexpression	Plasma	Cytokine assay, ELISA	Density gradient Ultracentrifugation	Highlights differences in size and frequency in plasma EVs between GBM patients and normal donors, and presents evidence for decreased expression of inflammatory markers in GBM patients' exosomes.
Ebrahimkhani S. et al. <sup>54</sup>	2018	GBM	12	Healthy Controls; Grade II-III glioma	miR-182-5p; miR-328-3p; miR-339-5p; miR-340-5p; miR-485-3p; miR-486-5p; miR-543	Differential expression	Serum	smallRNA sequencing	Size exclusion chromatography	Identifies distinct and superior miRNA signatures from previously reported "free-circulating" miRNA studies in GBM patients

Continued on next page...



Continued from previous page...

Dobra G. et al. <sup>55</sup>	2020	GBM	24	Lumber disc herniation patients; Other brain tumors	PF4; S100A14; Differential HSPA8; HBG1; expression CASP14; HSPB1; CCCT; SBSN; S100A7; FLG2; IGLL1; SPRR2E; ANPEP; MMP9; FN1; FGB; MMRN1		Serum	LC-MS	Ultracentrifugation	Shows that even a low-efficacy sEV enrichment method may be appropriate to enhance the analytical applicability of serum samples for CNS cancer monitoring
García-Romero N. et al. <sup>56</sup>	2017	Glioma	21		IDH1G395A gDNA	Overexpression	Plasma; Serum	Fast Cold-PCR	Differential Ultracentrifugation	Supports the idea that EVs secreted by brain tumor cells can cross the BBB, whether intact or disrupted, and enters the bloodstream. Therefore, the analysis of their cargo might be useful as a biomarker.
Graziano F. et al. <sup>57</sup>	2021	Glioma; Meningioma	34	Healthy controls	Hsp60; miR-1; miR-206; miR-663	Differential expression	Plasma	qRT-PCR	Differential Ultracentrifugation	Reveals that EVs with Hsp60 and related miRNAs increase in patients' blood in a manner that reflects disease status
Hallal S. et al. <sup>58</sup>	2020	Glioma	41	Healthy controls	AIDA; ARHGEF10; BNIP3L; FYB1; KMT2D; MAP7; MAST4;	Differential expression	Plasma	SWATH-MS; LC-MS/MS	qEV	Highlights the potential for SWATH-MS to define circulating-EV biomarkers

Continued on next page...

Continued from previous page...

					PDE8A; POLR2D; RENBP; SLC25A17; CDC40; TPST2CETN3; PPP1R11; SYT7					for objective blood-based measurements of glioma activity using plasma-EV derived proteome profiles.
Chandran I. et al. <sup>59</sup>	2019	GBM	65	Low Grade Glioma	SDC1	Overexpression	Plasma	LC-MS/MS; ELISA	Size exclusion chromatography	Identifies SDC1 as a plasma derived-EV constituent for noninvasive differentiation between GBM and LGG
Jones P. et al. <sup>60</sup>	2019	GBM	6		PplX	Overexpression	Plasma	Imaging flow cytometry	ExoEasy	Highlights the potential of plasma-derived PplX-positive EV using IFC based diagnostics for malignant gliomas.
Li P. et al. <sup>61</sup>	2022	High Grade Astro-cytoma	30	Healthy controls	circ-0075828; circ-0002976; circ-0003828	Expression	Serum	circRNA Sequencing (qRT-PCR)		Shows that the serum exosome circRNA is potentially useful for HGA liquid biopsy and prognosis monitoring.
Maas S. et al. <sup>42</sup>	2020	GBM	30	Healthy controls	PplX	Expression	Plasma	High-resolution flow cytometry	Ultracentrifugation	Assesses whether PplX accumulates in GB-derived EVs and whether these EVs could be isolated and characterized to enable a

Continued on next page...

Continued from previous page...

Piazza A. et al. <sup>62</sup>	2022	Glioma	14	Non-specific cephalgia patients	exoDNA levels	Variation	Plasma	Fluorometry	ExoEasy	liquid biopsy in GBM Shows the variation of the concentration of exoDNA in the plasma across the different stages of tumor growth
Ricklefs F. et al. <sup>63</sup>	2020	Glioma	29	Healthy controls	FASN	Overexpression	Plasma	Imaging flow cytometry	Ultracentrifugation	Shows that combined marker profiling is more sensitive at detecting subtle shifts in EV subpopulations than considering only single markers and that elevated FASN+/CD63+ as well as FASN+/CD81+ EVs are characteristic of glioma patients
Rosa P. et al. <sup>64</sup>	2022	GBM	26	Non-specific cephalgia patients	NF1; exoDNA levels	Mutation; Decreased levels of exoDNA	Plasma	NGS	ExoEasy	Demonstrates the technical feasibility of the mutational analysis of the genomic cargo in circulating EVs
Wang H. et al. <sup>65</sup>	2019	Glioma	23	Healthy controls	EGFR; PTTG1; NLGN3	Overexpression	Serum	Flow cytometry; qRT-PCR	Ultracentrifugation	Shows the potential of EGFR, NLGN3 and PTTG1 in EVs for

Continued on next page...

Continued from previous page...

detecting glioma using optimized flow cytometry.

**Table 3: cfDNA as liquid biopsy.**

First Author	Publish Year	Cancer Type	Patients	Detected Alteration	Frequency of detection	Sample Used	Methods	Sensitivity	Specificity	Summary
Bagley S. et al. <sup>66</sup>	2021	GBM	62	cfDNA levels		Plasma	qPCR			Increased cfDNA concentration from pre-operative to post-chemoradiotherapy is associated with worse subsequent PFS and OS, suggesting that on-therapy cfDNA dynamics may have a role in assessing therapeutic response in patients with GBM.
Cantor E. et al. <sup>24</sup>	2022	DMG	28	H3.3K27M mutation	53/62 (plasma samples); 28/29 (CSF samples)	Plasma; CSF	ddPCR	85.4% (plasma); 96,5% (CSF)		Patterns of change in H3K27M VAF over time demonstrate clinical utility in terms of predicting progression and sustained response and possible differentiation of pseudoprogression and pseudo-response.

Continued on next page...

Continued from previous page...

Fontanillies M. et al. <sup>67</sup>	2020	GBM, Gliosarcoma	52	TERT promoter mutation	2 out of 46 patients	Plasma	ddPCR			In contrast to ctDNA using TERTp mutation detection, the cfDNA concentration varies significantly over the course of treatment and may be a biomarker of PD during the TMZ phase
Garcia-Romero N. et al. <sup>23</sup>	2019	Pediatric CNS tumors	29	BRAF V600E	29/29	Serum;Plasma ; CSF	ddPCR	25% (plasma); 50% (serum)	77.8% (plasma); 100% (serum)	The first study to compare the different sources of liquid biopsies in pediatric cancers
Husain A. et al. <sup>68</sup>	2022	ADG	50	cfDNA levels		Serum	qPCR			High baseline cfDNA concentration predicted worse treatment response independent of other prognostic factors. The study also compares the pre-operative and postoperative serum cfDNA mutations in matched tissue from ADG patients
Izquierdo E. et al. <sup>69</sup>	2021	HGG; DMG	27	H3F3A, IDH1, BRAF, ACVR1, PI3KCA mutations;	7/27 (plasma samples ); 6/9 (CSF samples); 2/6 ( serum	Plasma; Serum; CSF; Cystic Fluid	ddPCR	10%		This study describes the validation of a number of

Continued on next page...

Continued from previous page...

				MYCN amplification	samples); 1/1 (cystic fluid sample)						ddPCR assays for the detection of point mutations in cfDNA.
Kang K. et al. <sup>70</sup>	2021	Glioma; CNS metastasis	9	BRAF V600E	4 out of 5 patients	Plasma	ddPCR	80%	100%		Demonstrate technical development a droplet digital PCR assay for the detection of BRAF V600E in plasma of patients with primary and metastatic brain tumors
Koga T. et al. <sup>71</sup>	2022	GBM	29	EGFRvIII breakpoints		Plasma; CSF	qPCR; PCR mapping; sWGS				EGFRvIII- derived PCR amplicons were not obtained from either cfDNA or evDNA derived from plasma, even with modifications to enhance sensitivity, such as preamplificati on and heparinase I treatment.
Li D. et al. <sup>72</sup>	2021	DMG		H3.3K27M mutation		CSF; Plasma	ddPCR				Employs vacuum- concentration of pre- amplified ctDNA, which increased test sensitivity without decreasing specificity), enabling

Continued on next page...

Continued from previous page...

										target mutation detection in patient-matched tumor tissue, CSF and blood specimens
Mouliere F. et al. <sup>73</sup>	2021	Glioma	35	Mutation in multiple genes; cfDNA fragmentation	10/16 (urine sample); 10/12 (plasma samples); 7/8 (CSF samples)	CSF; Plasma; Urine	patient-specific hybrid-capture panels; sWGS	59%	92%	Reveals possible difference in the fragment sizes of urine cfdDNA in cancer patients as compared to healthy individuals
Nassiri F. et al. <sup>74</sup>	2021	Intracranial tumors	220	Glioma-specific DNA methylation-based signatures		Plasma	Whole genome cfMeDIP-seq			Distinguishes gliomas from intracranial metastasis and healthy controls without relying on information obtained from a tumor tissue biopsy
Muralidharan K. et al. <sup>75</sup>	2021	Glioma	157	TERT promoter mutation	33 out of 46 plasma samples	Plasma	ddPCR	62.50%	90%	Demonstrates a TERT promoter mutation assay utilizing high affinity LNA enhanced probes and an additive 7dG for detection and monitoring of the mutations in tumor tissue and cfdNA of matched

Continued on next page...

Continued from previous page...

Nørøxe D. et al. <sup>76</sup>	2019	Glioma	8	cfDNA levels		Plasma	Fluorimetry	plasma of patients Shows good tendency between cfDNA and treatment course and -response, respectively with the highest levels at progression.
Okamura R. et al. <sup>77</sup>	2020	Glioma	135	CH-associated genes: ATM, BRAF, BRCA1, EGFR, FBXW7, GNAS, IDH1, JAK2, MET, NF1, PDGFRA, and TP53	29/135 (characterized alteration); 27/135 (VUSs in cfDNA)	Plasma	NGS	CH-type cfDNA mutations is an independent prognostic factor for shorter survival
Pages M. et al. <sup>78</sup>	2022	Pediatric Brain tumors	258	Copy number alteration and mutation in multiple genes	78/132 (at least one CNA at a chromosome arm level)	Blood; Urine; CSF	ULP-WGS	Systematically evaluates the feasibility of profiling pediatric brain tumours using ctDNA obtained various biomes. Most samples had insufficient somatic mutations discoverable by the sequencing panel to provide sufficient power to detect tumor fractions.

Continued on next page...



Continued from previous page...

Palande V. et al. <sup>41</sup>	2022	GBM	25	cfDNA levels; TP53, EGFR, NF1, LRP1B, IRS4 mutations; KDR-PDGFR $\alpha$ , NCDN-PDGFR $\alpha$ , COL1A1-PDGFB, NIN-PDGFRB, FGFR1-BCR, CEP85L-ROS1 and GOPC-ROS1 gene-gene fusions		Blood	Fluorimetry; NGS	80%	95%	Suggests that integrated analysis of cfDNA plasma concentration, gene mutations, and gene-gene fusions can serve as a diagnostic modality for distinguishing GBM patients who may benefit from targeted therapy.
Panditharatna E. et al. <sup>79</sup>	2018	pDMG	48	H3.3K27M mutation	20/23 subjects (CSF samples); 18/20 subjects (plasma samples)	Plasma; CSF	ddPCR	88%		Shows that CSF and plasma ctDNA analysis of children with DMG is feasible, shows promise for detecting mutational load and provides an additional means for molecular disease characterization
Piccioni D. et al. <sup>80</sup>	2019	Primary Brain Tumors	419	Copy number alteration, Variant allele fraction and mutation of multiple genes	211/ 419 patients	Plasma	NGS	55%		Contrary to other cfDNA studies which postulated that ctDNA would not cross the BBB, this study found that half of the patients with primary brain

Continued on next page...

Continued from previous page...

										tumours had detectable cfDNA alterations with 48.9% of these having a potentially genomically targetable alteration
Sabedot T. et al. <sup>81</sup>	2021	Glioma	149	Glioma-specific DNA methylation-based signatures		Serum	Genome-wide Methylation array	100%	97.78%	Developed and verified a score metric (the "glioma-epigenetic liquid biopsy score" or GelB) that optimally distinguished patients with or without glioma
Szadkowska P. et al. <sup>40</sup>	2022	Brain Tumors	84	Mutation in multiple genes; Copy number alteration	8/84 patients (tumor specific alteration); 32/84 patients (potentially pathogenic alteration)	Plasma	NGS			Shows that slight improvements in isolation, library preparation, and mutational analyses of ccfDNA lead to better detection of tumour-specific genetic alterations
Tuna G. et al. <sup>82</sup>	2022	Glioma	49	IDH1 R123H mutation	12/19 patients (CSF samples); 1/4 patients (plasma samples)	CSF; Plasma	ddPCR			Provides evidence that the analysis of CSF ctDNA may complement the diagnosis of IDH1 R123H

Continued on next page...

Continued from previous page...

mutation at a rate of 63.2%. Also shows D-2-HG concentrations in CSF can distinguish between IDH1 wild-type and mutant individuals with acceptable sensitivity and specificity.

CUSA-EV: cavitron ultrasonic surgical aspirate extracellular vesicles; NGS: next-generation sequencing; ddPCR: Droplet Digital PCR; PFS: progression-free survival; OS: overall survival; RT: radiation therapy; RT-PCR: reverse-transcription PCR; EV: extracellular vesicles; BBB: blood-brain barrier; qRT-PCR: Quantitative Reverse Transcription PCR; SWATH-MS: Sequential Window Acquisition of All Theoretical Mass Spectra; LC-MS: Liquid Chromatography Mass Spectrometry; IFC: Intraoperative flow cytometry; sWGS: shallow whole genome sequencing; ULP-WGS: ultra-low-pass whole-genome sequencing.

feasibility and clinical efficacy of serial cf-t DNA in plasma and CSF of DMG in addition to serial monitoring through imaging. The pattern of changes in VAF values over time demonstrates utility in correlating with a sustained response, predicting progression, and identifying pseudo-progression and pseudo-response,<sup>23</sup> including extremely low abundance in serum compared to CSF limits the use of cfDNA for liquid biopsies. Moreover, they degrade readily as compared to CTCs. Although the studies above demonstrate that cfDNA can be used to screen for brain tumours, additional investigations sometimes add to the total cost, thus making it inapplicable for use in a resource-limited setting.

### Extracellular vesicles and exosomes

Exosomes are extracellular vesicles that contain cell contents such as DNA, RNA, proteins, and metabolites. They are incredibly stable outside cells and have the potential to be a perfect liquid biopsy tool. Using RNA derived from extracellular plasma vesicles, Batool et al. demonstrated the presence of EGFRvIII mutations in glioma patients. The same mutation was also detected in the tumour tissue of the patient. The sensitivity and specificity for the detected mutation in plasma compared with tumour tissue analysis were reported to be 72.8% and 97.7%, respectively.<sup>24</sup> In another study, Hallal S. et al. reported significant changes in miRNA and piRNA expression in GBM-EVs compared to GII-III EVs, several of which play essential roles in glioma genesis. Their results showed that CUSA-EV miRNAs could elucidate and

validate potential prognostic biomarkers for GBM. A key example is the detection of IDH-1 transcripts within circulating EVs, allowing classification of glioblastoma through non-invasive methods.<sup>25</sup>

Indeed, there are problems with the clean filtration and isolation of exosomes. Liu et al. highlighted that serum might not be the perfect choice for a representative sampling of circulating EVs, as a high fraction of EVs may be lost during coagulation.<sup>26</sup> Furthermore, blood components (e.g., platelets) may release micro-vesicles (MV) during clotting, altering the original MV content of blood samples. Besides, they are incredibly adhesive to standard laboratory plastic, reducing the isolated concentration.<sup>27</sup>

### Micronas

MicroRNAs, small RNA molecules devoid of coding functions, circulate within the bloodstream in highly stable forms, offering potential applications in liquid biopsy.<sup>28</sup> Various miRNAs, notably miR-21, miR-15b, miR-125b, and miR-223, have been identified in the cerebrospinal fluid (CSF) of adult brain tumour patients. These particular markers exhibit notable specificity and sensitivity for detecting gliomas and medulloblastomas. Iannó MF. et al. outlined a distinctive profile comprising 13 circulating miRNAs, where increased expression of miR-4714-3p, miR-551b, and miR-4505 correlated with improved prognosis.<sup>29</sup> Conversely, higher expression of the remaining ten miRNAs in the signature (miR-6090, miR-6089, miR-3960, miR-936, miR-1207-5p, miR-202-3p,

miR-3676-5p, miR-4634, miR-4539, and miR-4299) was associated with a poorer prognosis. Markoff et al. identified a 9-gene miRNA pattern that could accurately discern between glioma and healthy individuals with a precision rate of 99.8%. Among these, miR-223 and miR-320e exhibited dynamic fluctuations closely correlating with tumour volume in low-grade gliomas (LGG) and glioblastomas (GBM), respectively. Notably, levels of miRNAs remained unchanged in instances of pseudo-progression, showcasing the potential of this test in steering treatment decisions.<sup>30</sup> Olisio et al. demonstrated that high-grade glioma (HGG) progression coincided with escalated expression of serum exosomal miR-21, miR-222, and miR-124-3p during postoperative monitoring.<sup>31</sup> In the context of GBM, Sippl et al. identified miRNA-181d as a promising molecular marker reliably detectable in blood samples.<sup>32</sup> Conversely, Swellam M. et al. established a correlation between increased serum levels of miR-17-5p, miR-125b, and miR-221 in GBM patients and poorer progression-free survival, as well as worse overall survival.<sup>33</sup>

### Metabolites and proteins

Tumour-associated proteins i.e. 'onco-metabolite' accumulation may be a promising approach to evaluating the consequences of brain tumour-associated mutations. Small molecules such as 2HG (D-2-hydroxyglutarate) have been shown to accumulate in glioma with IDH-1 mutations and can be detected within serum samples. A study of 84 patients comparing 2HG with mass spectrometry showed plasma and urine levels to be correlated with treatment response and disease recurrence.<sup>34</sup> This can further be validated through MR spectroscopy detection of 2HG within the brain as a non-invasive radiomics marker; however, further utility may be limited within many LMIC centres.<sup>35</sup> Other potential proteomic targets suggested have been haptoglobin  $\alpha_2$ , YKL-40, and AHSR serum levels as strong correlates for tumour grade and prognosis.<sup>36</sup> ELISA and mass spectrometry are the most commonly used methods to quantify serum proteins; ELISA is easily available and accessible in limited resources, although inferior to mass spectrometry in protein discovery.<sup>37</sup>

### Challenges in utilising liquid biopsy for brain tumour management in LMICs

Significant progress has been made in liquid biopsies for brain tumours; however, its application in LMICs is a considerable challenge. The methodologies employed to look for the components of tumours subject to liquid biopsy face certain obstacles that hamper their optimal functioning. Here we highlight the problems faced in the pre-analytical, analytical, and post-analytical phases of

liquid biopsy processing.

### Pre-analytical phase

This phase starts with collecting the bio-fluid sample and ends with isolating the component under investigation. Most errors in the sample evaluation and workflow occur in this phase and can limit the integrity of the sample and the data quality.

Due to limited equipped facilities, samples must be transported over considerable distances for analysis. This makes it necessary to store the sample in optimized conditions so quality is not compromised. Collection devices must be calibrated for reliable results. Various collection tools incorporating preservative reagents are currently accessible, with cell-free DNA BCT tubes (manufactured by Streck, located in La Vista, Nebraska, USA) proving effective in safeguarding against genomic DNA contamination when storing samples at room temperature (RT) for a duration of up to 14 days.<sup>38</sup> The K2EDTA-containing tubes, typically used, show massive release of DNA under the same conditions.

Multiple studies have demonstrated that the quality of the collected ctDNA/ cfDNA is impacted by the time-lapse between sample collection and sample processing. Szadkowska P. et al. confirmed that processing blood within 24 h after collection significantly increased the yield of isolated cfDNA.<sup>39</sup> Similarly, Palande V. et al. showed improved ctDNA detection rates upon instantaneous plasma separation (within two hours after blood collection) and freezing (at  $-80^{\circ}\text{C}$ ) prior to cfDNA isolation.<sup>40</sup>

Sample pre-processing requires protocols to extract or isolate the desired component. Maas SL. et al. showed that after administration of 5-ALA, PpIX accumulates in glioma-derived EVs both in the media of cell cultures and in the plasma of GB patients. Using high-resolution flow cytometry, they could detect and isolate PpIX-positive, GB-derived EVs and then further analyse their content.<sup>41</sup> All pre-analytical variables need to be standardized so that consistent results can be obtained and made cost-effective so they can be applied in a resource-limited setting.

### Analytical processing phase and methods

Various methodologies are implied to analyse the sample to produce high-quality data. Different laboratories use different means and thus may contradict the clinical data interpretations. Because the cost of technologies for LB processing is high, LMICs like Pakistan, while trying to optimize the cost of sample analysis, may use sub-optimal technologies that produce false results, thus putting

patients at risk of an incorrect management plan for a brain tumour.

### Next generation sequencing (NGS)

Next-generation sequencing (NGS) technologies provide high-throughput screening of biopsy samples and improve accuracy for mutation allele frequency (MAF), gene fusions, or DNA amplification. These methods can be applied to targeted panel systems to detect targeted ctDNA mutations and indels. However, complete tumour heterogeneity cannot be detected by the targeted panel and require whole-genome or whole-exome sequencing, which are both pricey and less sensitive. They also require extensive sample input, which may not be possible in the case of CSF.

### Digital polymerase chain reaction (dPCR) and digital droplet PCR (ddPCR)

Digital PCR (dPCR) and droplet digital PCR (ddPCR) represent highly sensitive and cost-effective PCR-based techniques relevant to sequencing analysis. These methods excel in identifying allele variants or targets present in samples with minimal abundance, surpassing the limitations of conventional quantitative PCR (qPCR) approaches. Li et al. introduced an optimized ddPCR workflow, validated with tissue, to detect and measure H3.3K27M-mutant circulating tumour DNA (ctDNA) in clinically accessible cerebrospinal fluid (CSF) and plasma samples obtained from patients with diffuse midline gliomas (DMG). Addressing the challenge posed by low levels of ctDNA commonly found in brain tumours, they employed vacuum concentration of pre-amplified ctDNA, enhancing test sensitivity without compromising specificity.<sup>42</sup>

Nano String analysis is a novel molecular assay technique with certain benefits over PCR-based analysis as it does not require amplification with minimal risk of contamination.<sup>43</sup> Up to 800 molecular probes can be run simultaneously in single reactions however, it still requires normalisation of expression levels via a reference gene. FFPE can be readily used with Nano String analysis to obtain mRNA levels comparable with fresh frozen tissue samples, superior to the yield from RT-PCR. Recent experiments in its utility with liquid biopsy in lung cancers showed lower requirement for DNA compared to NGS for routine mutation testing, with strong correlations with evolution of disease.<sup>44</sup>

### Post-processing phase

The post-processing phase is equally important. People with expertise in molecular and computational biology, genetics, and specialised clinicians are required to

optimize the molecular data analyses, thus increasing the reproducibility of the results. However, their cost adds to the total cost, making liquid biopsy challenging.

### Overall cost

Cost of analysis and identification of brain tumour-related serum markers is significantly hampered by lack of specificity with most markers. Various other inflammatory, autoimmune, and other cancer conditions can cause aberrations in baseline levels of these metabolites, RNA, and DNA, making specific identification of brain tumour sub-types difficult. High throughput sequencing is needed and ultimately inflates the cost of analysis per sample. A routine, affordable liquid biopsy can be achieved once specific panels of markers can be designed and implemented, allowing standardized materials to be reproduced in clinical settings.<sup>45-47</sup>

### Conclusion

Liquid biopsy can potentially push the frontiers of personalised medicine for brain tumours. The shift towards achieving practical approaches for molecular analysis in brain tumours is essential, particularly given the significant neurological morbidity and financial burden associated with the current management. The possibility of minimally invasive cancer detection tools in brain tumour conditions could potentially revolutionise detection and follow-up rates within LMICs; a system of collection points in remote and rural areas could facilitate serum collection and use of liquid biopsy tools to help monitor and detect tumour response to treatment. Most of the developing world's population does not have quick access to MRI and neuro-radiologist facilities, nor afford the required repeated scans, resulting in missed follow-ups and recurrences. A practical liquid biopsy tool tackles both unaffordability and inaccessibility within these parts of the world, connecting these patients to more holistic neuro-oncological care.

**Disclaimer:** None.

**Conflict of Interest:** None.

**Funding Disclosure:** None.

### References

1. Abdullah UE, Laghari AA, Khalid MU, Rashid HB, Jabbar AA, Mubarak F, et al. Current management of glioma in Pakistan. *Glioma* 2019;2:139-44. DOI: 10.4103/glioma.glioma\_15\_19.
2. Khalid MU, Bajwa MH, Shah MM, Zafar SN, Laghari AA, Akhuzada NZ, et al. Factors associated with lost to follow up in patients with brain tumours: A multi-centre study in Pakistan. *J Pak Med Assoc* 2022;72(Suppl 4):s16-24. doi: 10.47391/JPMA.11-54-AKUB03.
3. Bajwa MH, Khalid MU, Shah MM, Shamim MS, Laghari AA, Akhuzada NZ, et al. Treatment patterns of glioma in Pakistan: An epidemiological perspective. *J Pak Med Assoc* 2022;72(Suppl

- 4):s34-9. doi: 10.47391/JPMA.11-S4-AKUB05.
4. Bajwa MH, Shah MM, Khalid MU, Khan AA, Zahid N, Anis SB, et al. Distance travelled for brain tumour surgery: An Low and Middle Income Country's perspective. *J Pak Med Assoc* 2022;72(Suppl 4):s25-33. doi: 10.47391/JPMA.11-S4-AKUB04.
  5. Yi Z, Qu C, Zeng Y, Liu Z. Liquid biopsy: early and accurate diagnosis of brain tumor. *J Cancer Res Clin Oncol* 2022;148:2347-73. doi: 10.1007/s00432-022-04011-3.
  6. Yekula A, Muralidharan K, Rosh ZS, Youngkin AE, Kang KM, Balaj L, et al. Liquid Biopsy Strategies to Distinguish Progression from Pseudoprogression and Radiation Necrosis in Glioblastomas. *Adv Biosyst* 2020;4:e2000029. doi: 10.1002/adbi.202000029.
  7. Bajwa MH, Shah MM, Khalid MU, Shamim MS, Baig E, Akhuzada NZ, et al. Time to surgery after radiological diagnosis of brain tumours in Pakistan: A nationwide cross-sectional study. *J Pak Med Assoc* 2022;72(Suppl 4):s93-7. doi: 10.47391/JPMA.11-S4-AKUB15.
  8. Fontanilles M, Duran-Peña A, Idbaih A. Liquid biopsy in primary brain tumors: looking for stardust!. *Curr Neurol Neurosci Rep* 2018;18:1-9. doi:10.1007/s11910-018-0820-z.
  9. Martínez-Ricarte F, Mayor R, Martínez-Sáez E, Rubio-Pérez C, Pineda E, Cordero E, et al. Molecular Diagnosis of Diffuse Gliomas through Sequencing of Cell-Free Circulating Tumor DNA from Cerebrospinal Fluid. *Clin Cancer Res* 2018;24:2812-9. doi: 10.1158/1078-0432.CCR-17-3800.
  10. Miller AM, Shah RH, Pentsova EI, Pourmaleki M, Briggs S, Distefano N, et al. Tracking tumour evolution in glioma through liquid biopsies of cerebrospinal fluid. *Nature* 2019;565:654-8. doi: 10.1038/s41586-019-0882-3.
  11. De Rubis G, Rajeev Krishnan S, Bebawy M. Liquid Biopsies in Cancer Diagnosis, Monitoring, and Prognosis. *Trends Pharmacol Sci* 2019;40:172-86. doi: 10.1016/j.tips.2019.01.006.
  12. Le Rhun E, Seoane J, Salzet M, Soffiotti R, Weller M. Liquid biopsies for diagnosing and monitoring primary tumors of the central nervous system. *Cancer Lett* 2020;480:24-8. doi: 10.1016/j.canlet.2020.03.021.
  13. Plaks V, Koopman CD, Werb Z. Cancer. Circulating tumor cells. *Science* 2013;341:1186-8. doi: 10.1126/science.1235226.
  14. Alix-Panabières C, Pantel K. Challenges in circulating tumour cell research. *Nat Rev Cancer* 2014;14:623-31. doi: 10.1038/nrc3820.
  15. Rossi G, Ignatiadis M. Promises and Pitfalls of Using Liquid Biopsy for Precision Medicine. *Cancer Res* 2019;79:2798-804. doi: 10.1158/0008-5472.CAN-18-3402.
  16. Müller C, Holtschmidt J, Auer M, Heitzer E, Lamszus K, Schulte A, et al. Hematogenous dissemination of glioblastoma multiforme. *Sci Transl Med* 2014;6:247ra101. doi: 10.1126/scitranslmed.3009095.
  17. Madlener S, Gojo J. Liquid Biomarkers for Pediatric Brain Tumors: Biological Features, Advantages and Perspectives. *J Pers Med* 2020;10:254. doi: 10.3390/jpm10040254.
  18. Bronkhorst AJ, Ungerer V, Holdenrieder S. The emerging role of cell-free DNA as a molecular marker for cancer management. *Biomol Detect Quantif* 2019;17:100087. doi: 10.1016/j.bdq.2019.100087.
  19. Jahr S, Hentze H, Englisch S, Hardt D, Fackelmayer FO, Hesch RD, et al. DNA fragments in the blood plasma of cancer patients: quantitations and evidence for their origin from apoptotic and necrotic cells. *Cancer Res* 2001;61:1659-65.
  20. Bagley SJ, Nabavizadeh SA, Mays JJ, Till JE, Ware JB, Levy S, et al. Clinical Utility of Plasma Cell-Free DNA in Adult Patients with Newly Diagnosed Glioblastoma: A Pilot Prospective Study. *Clin Cancer Res* 2020;26:397-40. doi: 10.1158/1078-0432.CCR-19-2533.
  21. Bagley SJ, Till J, Abdalla A, Sangha HK, Yee SS, Freedman J, et al. Association of plasma cell-free DNA with survival in patients with IDH wild-type glioblastoma. *Neurooncol Adv* 2021;3:vdab011. doi: 10.1093/oaajnl/vdab011.
  22. García-Romero N, Carrión-Navarro J, Areal-Hidalgo P, Ortiz de Mendivil A, Asensi-Puig A, Madurga R, et al. BRAF V600E Detection in Liquid Biopsies from Pediatric Central Nervous System Tumors. *Cancers (Basel)* 2019;12:66. doi: 10.3390/cancers12010066.
  23. Cantor E, Wierzbicki K, Tarapore RS, Ravi K, Thomas C, Cartaxo R, et al. Serial H3K27M cell-free tumor DNA (cf-tDNA) tracking predicts ONC201 treatment response and progression in diffuse midline glioma. *Neuro Oncol* 2022;24:1366-74. doi: 10.1093/neuonc/noac030.
  24. Batool SM, Muralidharan K, Hsia T, Falotico S, Gamblin AS, Rosenfeld YB, et al. Highly Sensitive EGFRvIII Detection in Circulating Extracellular Vesicle RNA of Glioma Patients. *Clin Cancer Res* 2022;28:4070-82. doi: 10.1158/1078-0432.CCR-22-0444.
  25. Sabbagh Q, Andre-Gregoire G, Guevel L, Gavard J. Vesiclemia: counting on extracellular vesicles for glioblastoma patients. *Oncogene* 2020;39:6043-52. doi: 10.1038/s41388-020-01420-x
  26. Liu ML, Werth VP, Williams KJ. Blood plasma versus serum: which is right for sampling circulating membrane microvesicles in human subjects? *Ann Rheum Dis* 2020;79:e73. doi: 10.1136/annrheumdis-2019-215505.
  27. Giulietti M, Occhipinti G, Righetti A, Armeni T, Principato G, Piva F. Employment of Exosomes for Liquid Biopsies. *Transl Biomed* 2015;6:e37. DOI: 10.21767/2172-0479.100037
  28. Todén S, Goel A. Non-coding RNAs as liquid biopsy biomarkers in cancer. *Br J Cancer* 2022;126:351-60. doi: 10.1038/s41416-021-01672-8.
  29. Iannó MF, Biassoni V, Schiavello E, Careno A, Boschetti L, Gandola L, et al. A microRNA Prognostic Signature in Patients with Diffuse Intrinsic Pontine Gliomas through Non-Invasive Liquid Biopsy. *Cancers (Basel)* 2022;14:4307. doi: 10.3390/cancers14174307.
  30. Morokoff A, Jones J, Nguyen H, Ma C, Lasocki A, Gaillard F, et al. Correction to: Serum microRNA is a biomarker for post-operative monitoring in glioma. *J Neurooncol* 2020;149:391-400. doi: 10.1007/s11060-020-03630-5.
  31. Olioso D, Caccese M, Santangelo A, Lippi G, Zagone V, Cabrini G, et al. Serum Exosomal microRNA-21, 222 and 124-3p as Noninvasive Predictive Biomarkers in Newly Diagnosed High-Grade Gliomas: A Prospective Study. *Cancers (Basel)* 2021;13:3006. doi: 10.3390/cancers13123006.
  32. Sippl C, Quiring A, Teping F, Schulz-Schaeffer W, Urbschat S, Ketter R, et al. MiRNA-181d Expression Correlates in Tumor versus Plasma of Glioblastoma Patients-the Base of a Preoperative Stratification Tool for Local Carmustine Wafer Use. *World Neurosurg* 2022;159:e324-33. doi: 10.1016/j.wneu.2021.12.053.
  33. Swellam M, Bakr NM, El Magdoub HM, Hamza MS, Ezz El Arab LR. Emerging role of miRNAs as liquid biopsy markers for prediction of glioblastoma multiforme prognosis. *J Mol Neurosci* 2021;71:836-44. doi: 10.1007/s12031-020-01706-5.
  34. Lombardi G, Corona G, Bellu L, Della Puppa A, Pambuku A, Fiduccia P, et al. Diagnostic value of plasma and urinary 2-hydroxyglutarate to identify patients with isocitrate dehydrogenase-mutated glioma. *Oncologist* 2015;20:562-7. doi: 10.1634/theoncologist.2014-0266.
  35. Picca A, Di Stefano AL, Sanson M. Current and future tools for determination and monitoring of isocitrate dehydrogenase status in gliomas. *Curr Opin Neurol* 2018;31:727-32. doi: 10.1097/WCO.0000000000000617.
  36. Saenz-Antoñanzas A, Auzmendi-Iriarte J, Carrasco-Garcia E, Moreno-Cugnon L, Ruiz I, Villanua J, et al. Liquid Biopsy in Glioblastoma: Opportunities, Applications and Challenges. *Cancers (Basel)* 2019;11:950. doi: 10.3390/cancers11070950.
  37. Khristov V, Lin A, Freedman Z, Staub J, Shenoy G, Mrowczynski O, et al. Tumor-Derived Biomarkers in Liquid Biopsy of Glioblastoma. *World Neurosurg* 2023;170:182-94. doi:

- 10.1016/j.wneu.2022.11.012.
38. Norton SE, Lechner JM, Williams T, Fernando MR. A stabilizing reagent prevents cell-free DNA contamination by cellular DNA in plasma during blood sample storage and shipping as determined by digital PCR. *Clin Biochem* 2013;46:1561-5. doi: 10.1016/j.clinbiochem.2013.06.002.
  39. Szadkowska P, Roura AJ, Wojtas B, Wojnicki K, Licholai S, Waller T, et al. Improvements in Quality Control and Library Preparation for Targeted Sequencing Allowed Detection of Potentially Pathogenic Alterations in Circulating Cell-Free DNA Derived from Plasma of Brain Tumor Patients. *Cancers (Basel)* 2022;14:3902. doi: 10.3390/cancers14163902.
  40. Palande V, Siegal T, Detroja R, Gorohovski A, Glass R, Flueh C, et al. Detection of gene mutations and gene-gene fusions in circulating cell-free DNA of glioblastoma patients: an avenue for clinically relevant diagnostic analysis. *Mol Oncol* 2022;16:2098-114. doi: 10.1002/1878-0261.13157.
  41. Maas SLN, van Solinge TS, Schnoor R, Yekula A, Senders JT, de Vrij J, et al. Orally Administered 5-aminolevulinic Acid for Isolation and Characterization of Circulating Tumor-Derived Extracellular Vesicles in Glioblastoma Patients. *Cancers (Basel)* 2020;12:3297. doi: 10.3390/cancers12113297.
  42. Li D, Bonner ER, Wierzbicki K, Panditharatna E, Huang T, Lulla R, et al. Standardization of the liquid biopsy for pediatric diffuse midline glioma using ddPCR. *Sci Rep* 2021;11:5098. doi: 10.1038/s41598-021-84513-1.
  43. Eastel JM, Lam KW, Lee NL, Lok WY, Tsang AHF, Pei XM, et al. Application of NanoString technologies in companion diagnostic development. *Expert Rev Mol Diagn* 2019;19:591-8. doi: 10.1080/14737159.2019.1623672.
  44. Giménez-Capitán A, Bracht J, García JJ, Jordana-Ariza N, García B, Garzón M, et al. Multiplex Detection of Clinically Relevant Mutations in Liquid Biopsies of Cancer Patients Using a Hybridization-Based Platform. *Clin Chem* 2021;67:554-63. doi: 10.1093/clinchem/hvaa248.
  45. Krasic J, Abramovic I, Vrtaric A, Nikolac Gabaj N, Kralik-Oguic S, Katusic Bojanac A, et al. Impact of Preanalytical and Analytical Methods on Cell-Free DNA Diagnostics. *Front Cell Dev Biol* 2021;9:686149. doi: 10.3389/fcell.2021.686149.
  46. Hallal S, Ebrahim Khani S, Wei H, Lee MYT, Sim HW, Sy J, et al. Deep Sequencing of Small RNAs from Neurosurgical Extracellular Vesicles Substantiates miR-486-3p as a Circulating Biomarker that Distinguishes Glioblastoma from Lower-Grade Astrocytoma Patients. *Int J Mol Sci* 2020;21:4954. doi: 10.3390/ijms21144954.
  47. Sippl C, Ketter R, Bohr L, Kim YJ, List M, Oertel J, et al. miRNA-181d Expression Significantly Affects Treatment Responses to Carmustine Wafer Implantation. *Neurosurgery* 2019;85:147-55. doi: 10.1093/neuros/nyy214.
  48. Tomeva E, Switzeny OJ, Heitzinger C, Hippe B, Haslberger AG. Comprehensive Approach to Distinguish Patients with Solid Tumors from Healthy Controls by Combining Androgen Receptor Mutation p.H875Y with Cell-Free DNA Methylation and Circulating miRNAs. *Cancers (Basel)* 2022;14:462. doi: 10.3390/cancers14020462.
  49. Zhang H, Wang J, Wang Z, Ruan C, Wang L, Guo H. Serum miR-100 is a potential biomarker for detection and outcome prediction of glioblastoma patients. *Cancer Biomark* 2019;24:43-9. doi: 10.3233/CBM-181416.
  50. Bukva M, Dobra G, Gomez-Perez J, Koos K, Harmati M, Gyukity-Sebestyen E, et al. Raman Spectral Signatures of Serum-Derived Extracellular Vesicle-Enriched Isolates May Support the Diagnosis of CNS Tumors. *Cancers (Basel)* 2021;13:1407. doi: 10.3390/cancers13061407.
  51. Cilibrasi C, Simon T, Vintu M, Tolias C, Samuels M, Mazarakis NK, et al. Definition of an Inflammatory Biomarker Signature in Plasma-Derived Extracellular Vesicles of Glioblastoma Patients. *Biomedicines* 2022;10:125. doi: 10.3390/biomedicines10010125.
  52. Cumba Garcia LM, Peterson TE, Cepeda MA, Johnson AJ, Parney IF. Isolation and Analysis of Plasma-Derived Exosomes in Patients With Glioma. *Front Oncol* 2019;9:651. doi: 10.3389/fonc.2019.00651.
  53. Ebrahimkhani S, Vafaei F, Hallal S, Wei H, Lee MYT, Young PE, et al. Deep sequencing of circulating exosomal microRNA allows non-invasive glioblastoma diagnosis. *NPJ Precis Oncol* 2018;2:28. doi: 10.1038/s41698-018-0071-0.
  54. Dobra G, Bukva M, Szabo Z, Bruszel B, Harmati M, Gyukity-Sebestyen E, et al. Small Extracellular Vesicles Isolated from Serum May Serve as Signal-Enhancers for the Monitoring of CNS Tumors. *Int J Mol Sci* 2020;21:5359. doi: 10.3390/ijms21155359.
  55. García-Romero N, Carrión-Navarro J, Esteban-Rubio S, Lázaro-Ibáñez E, Peris-Celda M, Alonso MM, et al. DNA sequences within glioma-derived extracellular vesicles can cross the intact blood-brain barrier and be detected in peripheral blood of patients. *Oncotarget* 2017;8:1416-28. doi: 10.18632/oncotarget.13635.
  56. Graziano F, Iacopino DG, Cammarata G, Scalia G, Campanella C, Giannone AG, et al. The triad Hsp60-miRNAs-extracellular vesicles in brain tumors: assessing its components for understanding tumorigenesis and monitoring patients. *Appl Sci* 2021;11:e2867. doi: 10.3390/app11062867.
  57. Hallal S, Azimi A, Wei H, Ho N, Lee MYT, Sim HW, et al. A Comprehensive Proteomic SWATH-MS Workflow for Profiling Blood Extracellular Vesicles: A New Avenue for Glioma Tumour Surveillance. *Int J Mol Sci* 2020;21:4754. doi: 10.3390/ijms21134754.
  58. Indira Chandran V, Welinder C, Månsson AS, Offer S, Freyhult E, Pernemalm M, et al. Ultrasensitive Immunoprofiling of Plasma Extracellular Vesicles Identifies Syndecan-1 as a Potential Tool for Minimally Invasive Diagnosis of Glioma. *Clin Cancer Res* 2019;25:3115-27. doi: 10.1158/1078-0432.CCR-18-2946.
  59. Jones PS, Yekula A, Lansbury E, Small JL, Ayinon C, Mordecai S, et al. Characterization of plasma-derived protoporphyrin-IX-positive extracellular vesicles following 5-ALA use in patients with malignant glioma. *EBioMedicine* 2019;48:23-35. doi: 10.1016/j.ebiom.2019.09.025.
  60. Li P, Xu Z, Liu T, Liu Q, Zhou H, Meng S, et al. Circular RNA Sequencing Reveals Serum Exosome Circular RNA Panel for High-Grade Astrocytoma Diagnosis. *Clin Chem* 2022;68:332-43. doi: 10.1093/clinchem/hvab254.
  61. Piazza A, Rosa P, Ricciardi L, Mangraviti A, Pacini L, Calogero A, et al. Circulating Exosomal-DNA in Glioma Patients: A Quantitative Study and Histopathological Correlations-A Preliminary Study. *Brain Sci* 2022;12:500. doi: 10.3390/brainsci12040500.
  62. Ricklefs FL, Maire CL, Matschke J, Dührsen L, Sauvigny T, Holz M, et al. FASN Is a Biomarker Enriched in Malignant Glioma-Derived Extracellular Vesicles. *Int J Mol Sci* 2020;21:1931. doi: 10.3390/ijms21061931.
  63. Rosa P, De Falco E, Pacini L, Piazza A, Ciraci P, Ricciardi L, et al. Next-Generation Sequencing Comparative Analysis of DNA Mutations between Blood-Derived Extracellular Vesicles and Matched Cancer Tissue in Patients with Grade 4 Glioblastoma. *Biomedicines* 2022;10:2590. doi: 10.3390/biomedicines10102590.
  64. Wang H, Jiang D, Li W, Xiang X, Zhao J, Yu B, et al. Evaluation of serum extracellular vesicles as noninvasive diagnostic markers of glioma. *Theranostics* 2019;9:5347-58. doi: 10.7150/thno.33114.
  65. Bagley SJ, Till J, Abdalla A, Sangha HK, Yee SS, Freedman J, et al. Association of plasma cell-free DNA with survival in patients with IDH wild-type glioblastoma. *Neurooncol Adv* 2021;3:vdab011. doi: 10.1093/oaajnl/vdab011.
  66. Fontanilles M, Marguet F, Beaussire L, Magne N, Pépin LF, Alexandru C, et al. Cell-free DNA and circulating TERT promoter

- mutation for disease monitoring in newly-diagnosed glioblastoma. *Acta Neuropathol Commun* 2020;8:179. doi: 10.1186/s40478-020-01057-7.
67. Husain A, Mishra S, Hadi R, Sahu A, Kumari S, Rastogi M, et al. Dynamics of cell-free DNA in predicting response in adult diffuse glioma on chemoradiotherapy. *Cancer Genet* 2022;268-69:55-63. doi: 10.1016/j.cancergen.2022.09.006.
  68. Izquierdo E, Proszek P, Pericoli G, Temelso S, Clarke M, Carvalho DM, et al. Droplet digital PCR-based detection of circulating tumor DNA from pediatric high grade and diffuse midline glioma patients. *Neurooncol Adv* 2021;3:vdab013. doi: 10.1093/noonl/vdab013.
  69. Kang KM, Muralidharan K, Yekula A, Small JL, Rosh ZS, Jones PS, et al. Blood-Based Detection of BRAF V600E in Gliomas and Brain Tumor Metastasis. *Cancers (Basel)* 2021;13:1227. doi: 10.3390/cancers13061227.
  70. Koga T, Li B, Figueroa JM, Ren B, Chen CC, Carter BS, et al. Mapping of genomic EGFRvIII deletions in glioblastoma: insight into rearrangement mechanisms and biomarker development. *Neuro Oncol* 2018;20:1310-2. doi: 10.1093/neuonc/noy058.
  71. Li D, Bonner ER, Wierzbecki K, Panditharatna E, Huang T, Lulla R, et al. Standardization of the liquid biopsy for pediatric diffuse midline glioma using ddPCR. *Sci Rep* 2021;11:5098. doi: 10.1038/s41598-021-84513-1.
  72. Mouliere F, Smith CG, Heider K, Su J, van der Pol Y, Thompson M, et al. Fragmentation patterns and personalized sequencing of cell-free DNA in urine and plasma of glioma patients. *EMBO Mol Med* 2021;13:e12881. doi: 10.15252/emmm.202012881.
  73. Nassiri F, Chakravarthy A, Feng S, Shen SY, Nejad R, Zuccato JA, et al. Detection and discrimination of intracranial tumors using plasma cell-free DNA methylomes. *Nat Med* 2020;26:1044-7. doi: 10.1038/s41591-020-0932-2.
  74. Muralidharan K, Yekula A, Small JL, Rosh ZS, Kang KM, Wang L. et al. TERT Promoter Mutation Analysis for Blood-Based Diagnosis and Monitoring of Gliomas. *Clin Cancer Res* 2021;27:169-78. doi: 10.1158/1078-0432.CCR-20-3083.
  75. Nørøxe DS, Østrup O, Yde CW, Ahlborn LB, Nielsen FC, Michaelsen SR, et al. Cell-free DNA in newly diagnosed patients with glioblastoma - a clinical prospective feasibility study. *Oncotarget* 2019;10:4397-406. doi: 10.18632/oncotarget.27030.
  76. Okamura R, Piccioni DE, Boichard A, Lee S, Jimenez RE, Sicklick JK, et al. High prevalence of clonal hematopoiesis-type genomic abnormalities in cell-free DNA in invasive gliomas after treatment. *Int J Cancer* 2021;148:2839-47. doi: 10.1002/ijc.33481.
  77. Pagès M, Rotem D, Gydush G, Reed S, Rhoades J, Ha G, et al. Liquid biopsy detection of genomic alterations in pediatric brain tumors from cell-free DNA in peripheral blood, CSF, and urine. *Neuro Oncol* 2022;24:1352-63. doi: 10.1093/neuonc/noab299.
  78. Panditharatna E, Kilburn LB, Aboian MS, Kambhampati M, Gordish-Dressman H, Magge SN, et al. Clinically Relevant and Minimally Invasive Tumor Surveillance of Pediatric Diffuse Midline Gliomas Using Patient-Derived Liquid Biopsy. *Clin Cancer Res* 2018;24:5850-9. doi: 10.1158/1078-0432.CCR-18-1345.
  79. Piccioni DE, Achrol AS, Kiedrowski LA, Banks KC, Boucher N, Barkhoudarian G, et al. Analysis of cell-free circulating tumor DNA in 419 patients with glioblastoma and other primary brain tumors. *CNS Oncol* 2019;8:CNS34. doi: 10.2217/cns-2018-0015.
  80. Sabedot TS, Malta TM, Snyder J, Nelson K, Wells M, deCarvalho AC, et al. A serum-based DNA methylation assay provides accurate detection of glioma. *Neuro Oncol* 2021;23:1494-508. doi: 10.1093/neuonc/noab023.
  81. Tuna G, Dal-Bekar NE, Akay A, Rükşen M, İşlekel S, İşlekel GH. Minimally Invasive Detection of IDH1 Mutation With Cell-Free Circulating Tumor DNA and D-2-Hydroxyglutarate, D/L-2-Hydroxyglutarate Ratio in Gliomas. *J Neuropathol Exp Neurol* 2022;81:502-10. doi: 10.1093/jnen/nlac036.

---

#### DISCLAIMER

Articles published in JPMA and Supplements of JPMA do not represent the views of the editor or editorial Board. Authors are solely responsible for the opinions expressed and the accuracy of the data.

The contribution of each author towards the published research included in this supplement is the responsibility of the authors and their institutions.

It is expected to be in accordance and compliance with the ICMJE Guidelines.

Any questions/queries raised by readers should be directed to the corresponding author.



## Use of artificial intelligence and radio genomics in neuroradiology and the future of brain tumour imaging and surgical planning in low- and middle-income countries

Faiza Urooj<sup>1</sup>, Aimen Tameezuddin<sup>2</sup>, Zaira Khalid<sup>3</sup>, Kiran Aftab<sup>4</sup>, Mohammad Hamza Bajwa<sup>5</sup>, Kaynat Siddiqui<sup>6</sup>, Saqib Kamran Bakhshi<sup>7</sup>, Hafiza Fatima Aziz<sup>8</sup>, Syed Ather Enam<sup>9</sup>

### Abstract

Brain tumour diagnosis involves assessing various radiological and histopathological parameters. Imaging modalities are an excellent resource for disease monitoring. However, manual inspection of imaging is laborious, and performance varies depending on expertise. Artificial Intelligence (AI) driven solutions a non-invasive and low-cost technology for diagnostics compared to surgical biopsy and histopathological diagnosis. We analysed various machine learning models reported in the literature and assess its applicability to improve neuro-oncological management. A scoping review of 47 full texts published in the last 3 years pertaining to the use of machine learning for the management of different types of gliomas where radiomics and radio genomic models have proven to be useful. Use of AI in conjunction with other factors can result in improving overall neurooncological management within LMICs. AI algorithms can evaluate medical imaging to aid in the early detection and diagnosis of brain tumours. This is especially useful where AI can deliver reliable and efficient screening methods, allowing for early intervention and treatment.

**Keywords:** Artificial Intelligence, Radiomics, Machine Learning, Genomics, Brain Neoplasms, Glioma, Biopsy

**DOI:** <https://doi.org/10.47391/JPMA.S3.GNO-07>

### Introduction

CNS tumours can be fatal if diagnosis and intervention are not done at the right time. Currently, they are estimated to affect 7-11 persons per 100,000 person-years.<sup>1</sup> Although the incidence of brain tumours is fairly constant, significant resources are employed for the management

.....  
<sup>1</sup>The Aga Khan Medical College and University, Karachi, Pakistan. <sup>2</sup>Ziauddin Medical College, Karachi, Pakistan. <sup>3</sup>Karachi Medical and Dental College, Karachi, Pakistan. <sup>4,5-9</sup>Department of Neurosurgery, The Aga Khan University, Karachi, Pakistan.

**Correspondence:** Syed Ather Enam **Email:** [ather.enam@aku.edu](mailto:ather.enam@aku.edu)

of these patients which can often be a challenge, especially in lower-income countries.<sup>1</sup> Impoverished healthcare systems do not have access to timely standard diagnosis and treatment for many patients.<sup>1</sup> Brain tumour diagnosis involves assessing tumour size, type, location, grading, and biopsy and treatments include surgery, chemotherapy, and radiation therapy.<sup>2</sup> Imaging modalities such as magnetic resonance imaging (MRI) are excellent tools for initial assessment and monitoring the disease,<sup>2</sup> however, manual inspection of imaging to detect tumour features with disease characteristics is laborious, and performance varies depending on individual expertise. Distinction on visualized characteristics is difficult and predicated on minute changes that may not always be readily assessed. Differentiating pathologies is the key to guiding personalised management. Surgical biopsy can miss key molecular characteristics due to sampling error or tumour heterogeneity. Moreover, prognosticating requires a deeper, algorithmic model to assess all aspects of neuro-oncological intervention and care.

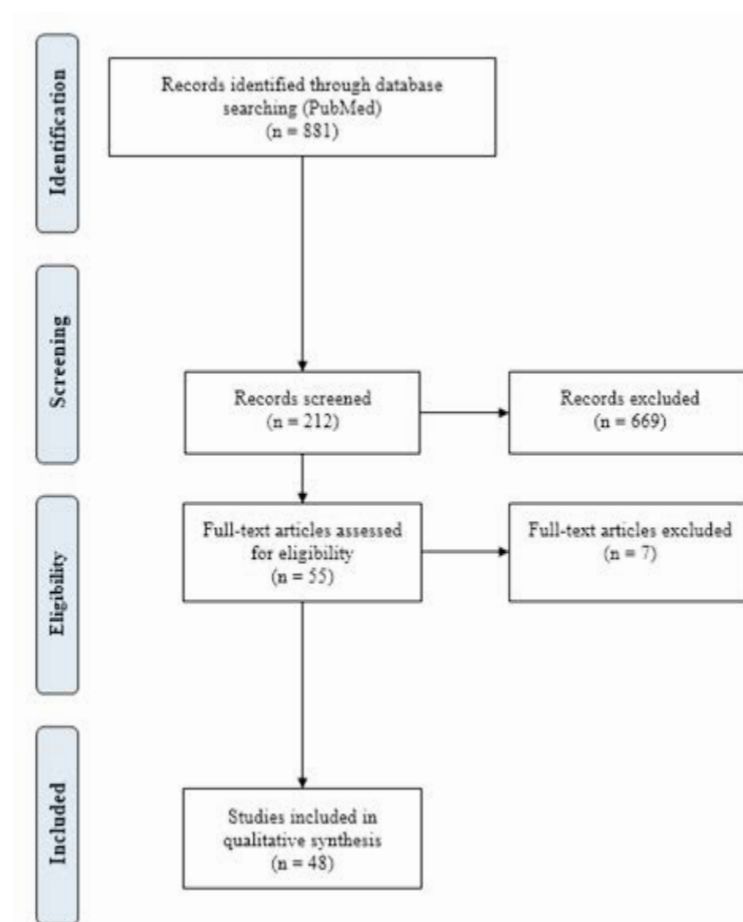
Recently, artificial intelligence (AI) technologies such as classical machine learning (ML) and deep learning (DL) have demonstrated advances in illness identification and categorisation. <sup>2</sup> Radiomics refers to the extraction of mineable data from medical imaging using image-processing techniques and using ML models to improve diagnosis, prognostication, and clinical decision support.<sup>3</sup> It is concerned solely with the imaging features or phenotype of the disease, whereas radio genomics combines and predicts both the imaging (phenotype) and genetic (genotype) aspects of the disorders.<sup>4</sup> The AI paradigm provides categorisation, detection, and segmentation for brain tumours, which has proven beneficial in terms of early identification, treatment, and survivability.<sup>4</sup> Based on genome-wide profiling and large-scale genomic analysis, molecular subtypes can be utilized to give diagnostic, prognostic, and therapeutic choices.<sup>5</sup> MRI-derived texture characteristics have demonstrated to non-invasively predict tumour type,

classification and behaviour. It is important to note that radio genomic research is in early stages and large number of samples are required to create robust models with acceptable performance.<sup>5</sup> Companies can expedite testing and observation by employing virtual clinical trials, sequencing, and pattern identification.<sup>6</sup>

This review article will analyse the effectiveness of various machine learning models reported in literature and discuss how lower-income nations can potentially benefit from radio genomics for brain tumours to improve neurooncological management.

## Methods

We conducted an extensive scoping review in March 2023, and identified 881 articles pertaining to the use of radiomics and radio genomics to assess imaging for different types of brain tumours. Fifty-five articles were shortlisted after the title, abstract and full text review. Of these 7 manuscripts were not available. A total of 48 articles, published during 2020 onwards were included in this study. (Figure 1) We conducted an extensive



**Figure-1:** Literature search algorithm..

literature review on PubMed and our search strategy was designed as follows (Radiomics OR Radio genomics OR Radiation Genomics OR Imaging Genomics) AND (Primary brain tumour [MeSH] OR Brain tumour [MeSH] OR Intracranial Neoplasm [MeSH] OR Malignant Brain Neoplasm [MeSH] OR Glioma [MeSH] OR Glioblastoma [MeSH] OR Astrocytoma [MeSH] OR Oligodendrogliomas [MeSH] OR neuroncology [MeSH]).<sup>2</sup> individuals conducted the title and abstract reviews independently and the finalised full texts were assessed for the type of tumour, sample size, study objectives, machine learning models used, and performance parameters.

## Results

Each article was reviewed, and the effectiveness of different ML models for brain tumour management has been summarised in tables 1 – 3.

## Discussion

Artificial intelligence is a collection of technologies, most of which directly relate to various healthcare fields, but the specific processes and tasks they support vary. The commonest application of machine learning is in precision medicine, to predict which treatment protocols are favourable to a patient based on various patient attributes.<sup>7</sup> Our review analyses various machine learning models reported in literature to diagnose and assess disease outcomes in brain tumours and responses to treatments.

The following ML models were analysed:

- 1) Random Forest: A random forest is an ensemble learning method that combines multiple decision trees to make predictions by aggregating the results of each tree.
- 2) Support Vector Machine (SVM): SVM is a supervised learning model that analyses data and classifies it into different categories by finding an optimal hyperplane that maximally separates the data points of different classes.
- 3) Deep Learning: Deep learning is a subset of machine learning that involves training artificial neural networks with multiple layers to learn representations of data.
- 4) Cox Regression: Cox regression, also known as the proportional hazards model, is a statistical survival analysis model used to investigate the relationship between survival time and predictor variables. It allows for the estimation of hazard ratios and provides insights into the impact of

**Table-1:** Tumour Characterization and Grading.

Study	Type of tumour(n)	Objective	Machine Learning Model	Performance Parameters (Accuracy, AUC, DICE Coefficient, C-index/indices)
Choi et al. <sup>9</sup> 2021	Glioma(1166)	Prediction of IDH status	CNN and binary classifier	Accuracy: 93.8, 87.9, 78.8 AUC: 0.96, 0.94, 0.86 DICE 0.86-0.92
Di Stefano et al. <sup>17</sup> 2020	Gliomas(80)	Characterization and survival prediction of fibroblast growth factor receptor 3 (FGFR3) positive gliomas and features unique to IDH wildtype gliomas	Cox proportional hazards	Exploratory (AUC) = 0.87 Validation MRI (AUC) = 0.75, Predicted survival (C-index) = 0.75 Clinical, genetic, and radiomic data (C-index) 0.81
Bijari et al. <sup>18</sup> 2022	GBM (50), Metastases (41)	Differentiating metastases from GBM using MRIs and comparing different machine learning models	MLP RF SVM LR DT Nb Knn Ada	Accuracy:      AUC: 0.90      0.90 0.92      0.94 0.57      0.55 0.93      0.88 0.91      0.92 0.64      0.86 0.79      0.90 0.90      0.92
Dong et al. <sup>19</sup> 2020	Glioblastoma and metastasis(120)	Differentiate supratentorial MET from GBM	Supervised learning category (decision tree, support vector machine, neural network, naiveBayes, and k-nearest neighbour	For the validation set Accuracy: 0.56 - 0.64 Sensitivity: 0.39 - 0.78 Specificity: 0.50 to 0.89
Hashido et al.2020	GliomaLGG: (15) HGG: (31)	1. Assess differences in glioma perfusion between arterial spin labelling (ASL) and dynamic susceptibility contrast (DSC) imaging2. Compare radiomic features of ASL and DSC imaging-derived cerebral blood flow (CBF)3. Assess radiomics-based classification models for low-grade gliomas (LGGs) and high-grade gliomas (HGGs)	Logistic regression models	AUC ASL-CBF: 0.888 DSC-CBF: 0.962
Jian et al. <sup>20</sup> 2021	Gliomas (44) studies	Diagnostic accuracy of ML models in molecular subtyping gliomas on preoperative MRI.	Random forest and SVM werethe most common ML classifiers	AUC IDH Mutation Training: 0.92, Validation: 0.90 1p19q codeletion Training: 0.83, Validation: 0.75 MGMT methylation: Training dataset: 0.87

Continued on next page...

Continued from previous page...

Li et al. <sup>21</sup> 2020	Gliomas(51)	Identification of immunohistochemical typing, to achieve the image-indication of tumour progression, angiogenesis, proliferation, or invasion	Random ForestAndDeep Learning	Accuracy Ki-67: 66.0, S-100: 0.898, Vimentin: 0.738, CD34: 0.667 AUC Ki-67: 0.713, S-100: 0.92, Vimentin: 0.854, CD34: 0.745
Bae et al. <sup>22</sup> 2020	Glioblastoma and Metastases(248)	Discriminating between glioblastoma and single brain metastasis.	Adaptive boosting and support vector machine	Deep Neural Network AUC: 0.956 Sensitivity: 90.6% Specificity: 88.0% Accuracy: 89% Traditional machine learning model AUC: 0.890 Human readers AUC: 0.774 and 0.904
Fan et al. <sup>23</sup> 2022	Pineal tumours(134)	Distinguish germinoma and pineal blastoma before surgery and assist in individualized diagnosis of patients with pineal region tumours.	Fusion radiomic model was established based selectedradiomic features through support vector machine	Accuracy Clinic radiomic combined model: Training: 0.878, Validation: 0.909 AUC Fusion radiomic model: Training: 0.920, Validation: 0.880 Clinical model: Training: 0.900, Validation: 0.880 Clinic radiomic combined model: Training: 0.950, Validation: 0.940
Li et al. <sup>24</sup> 2020	Ependymoma and Pilocytic astrocytoma (45)	Differentiated EP and PA using radiomics approach based on ML.	Support Vector Machine	Overall features set Texture: 0.82, Gabor transform: 0.75 Selected features set Selected texture: 0.80, Gabor transform based: 0.67, Wavelet transform: 0.73 AUC: Overall features set Texture: 0.81, Gabor transform: 0.73 Selected features set Texture: 0.78, Gabor transform based: 0.65, Wavelet transform: 0.72
Cao et al. <sup>25</sup> 2022	Lung cancer Brain Metastasis: (53) Breast cancer Brain Metastasis: (25)	Differentiating BMs originated from primary lung cancer and breast cancer.	Binary logistic regression and support vector machine	Training (AUC) CT: 0.703 vs. 0.751 MRI: 0.718 vs. 0.754 CT and MRI: 0.781 vs. 0.803 Validation (AUC) CT: 0.708 vs. 0.763 MRI: 0.715 vs. 0.717 CT and MRI: 0.771 vs. 0.805
Chang et al. <sup>26</sup> 2021	Medulloblastoma (38)	Multiparametric radiomics MRI analysis was conducted to reveal MB features since different MB subgroups have distinct patient	MR radiomics platform for feature extraction.	Accuracy: 71%AUCWNT: 0.82Group 3: 0.72Group 4: 0.78Prediction performance: 0.50

Continued on next page...

Continued from previous page...

		demographics, clinical management, and disease outcomes.		
Jalalifar et al. <sup>27</sup> 2020	BM40	The framework applied dissimilarities such as texture characteristics of tumour and enema to detect the tumour and lesion regions.	OC-SVM	DICE: QUANTITATIVE RESULTS OF SEGMENTATION FOR FIVE PATIENTS: 1. 0.88 ± 0.06 2. 0.84 ± 0.05 3. 0.88 ± 0.03 4. 0.80 ± 0.05 5. 0.82 ± 0.06
Dong et al. <sup>28</sup> 2021	Ependymoma and Medulloblastoma (51)	To investigate the effectiveness of radiomics and ML techniques on multimodal MR images in EP and MB of childhood.	Multivariate logistic regression and Random Forest	MLR and RF combined (AUC): 0.91
Chen et al. <sup>29</sup> 2020	Lung cancer with Brain Metastasis (110)	To classify EGFR, ALK, and KRAS mutation status in patients with primary lung cancer	Random Forest	Accuracy: Clinical data and radiomic features: EGFR: 77.7%, ALK: 86.7%, KRAS: 96.7% EGFR mutation (AUC) Radiomic features: 0.847 Clinical data: 0.609 Combined 0.912 ALK alteration status (AUC) Radiomic features: 0.813 Clinical data: 0.603 Combined: 0.915 KRAS mutation (AUC) Radiomic features: 0.938 Clinical data: 0.684 Combined: 0.985
Kandemirli et al. <sup>30</sup> 2020	Grade II meningiomas with brain invasion (BI): 56 Grade I and II Meningiomas with no brain invasion (NBI): 52	Differentiating meningiomas with and without brain invasion based on histopathology demonstration.	Random Forest	Grade I and II with brain invasion (AUC) Training: 0.999, Validation: 0.81 Cross-validated AUC BI versus NBI: 0.67, BI versus grade I meningiomas: 0.78
Huang et al. <sup>31</sup> 2021	Craniopharyngioma (164)	Discriminating the pathological subtypes of craniopharyngioma	Support vector machine recursive feature elimination (SVM-RFE)	Radiomic model (AUC) Training cohort: 0.899 Internal validation: 0.810 External validation: 0.920 Clinic radiological model (AUC) Training cohort: 0.677 Internal validation: 0.655 External validation: 0.671

Continued on next page...

Continued from previous page...

Jing et al. <sup>32</sup> 2022	Recurrence: (75) Pseudo progression: (43)	Early differential diagnosis of recurrence versus pseudo progression.	Multivariate Logistic Regression	Accuracy: Training group: T1: 80.72, T2: 72.29, T1+T2: 77.11 Test group: T1: 80.00, T2: 77.14, T1+T2: 88.57 AUC: Training group T1 + T2: 0.831, T1: 0.815, T2: 0.745 Test group T1 + T2: 0.829, T1: 0.804, T2: 0.734
Han et al. <sup>33</sup> 2021	Inflammation: (18) Glioma: (39)	Discriminating brain inflammation from grade II glioma.		Accuracy: Primary cohort T1W1: 0.795, T2W1: 0.955, Combination: 0.955 Validation cohort T1W1: 0.615, T2W1: 0.846, Combination: 0.923 AUC: Primary cohort T1W1: 0.811, T2W1: 0.980, Combination: 0.988 Validation cohort T1W1: 0.775, T2W1: 0.925, Combination: 0.950
Kim et al. <sup>34</sup> 2020	LGG (155)	Predicting IDH mutation status and tumor grading	SVM and random forest algorithm	IDH mutation status (Accuracy): 65.3% IDH Mutation (AUC) Multiparametric MRI: Training set 0.795, Validation set 0.747 Conventional MRI: Training set 0.729, Validation set: 0.705 tumour Grading (AUC) Multiparametric MRI: Training: 0.932, Validation: 0.819 Conventional MRI Training: 0.555, Validation: 0.644
Hashido et al. <sup>35</sup> 2021	Gliomas (52) LGG: (18) HGG: (34)	To evaluate various radiomics-based machine learning classification models using the apparent diffusion coefficient and cerebral blood flow maps for differentiating between low-grade gliomas and high-grade gliomas	1. Least absolute shrinkage and selection operator regularized logistic regression 2. Random Forest 3. Support vector machine with the radial basis function kernel 4. SVM with the linear kernel	Training Set (AUC) LASSO-LR: 0.965 RF: 1.000 SVM-RBF: 0.979 SVM-L: 0.969 Test set (AUC) LASSO-LR: 0.883 RF: 0.917 SVM-RBF: 0.717 SVM-L: 0.917
Cheng et al. <sup>36</sup> 2022	HGG(210) LGG(75)	Tumour grading and predictive performance of radiomic signature based on intratumorally, peritumoral features and their combinations	Minimum redundancy maximum relevance algorithm	Accuracy: ITV: 0.961, PTV: 0.856, IPTV: 0.933 AUC: ITV: 0.923 PTV: 0.877 IPTV: 0.954
Guo et al. <sup>37</sup> 2021	Glioma (152)	Explore whether multiparametric magnetic resonance imaging	Least absolute shrinkage and	Differentiating between (AUC) Training:

Continued on next page...

Continued from previous page...

(MRI)-based radiomics combined with selected blood inflammatory markers could effectively predict the grade and proliferation in glioma patients.

selection operator (LASSO)

Low- and high-grade: 0.92  
Grade III and grade IV: 0.91  
Low Ki-67 and high Ki-67: 0.94

Validation

Low- and high-grade: 0.94  
Grade III and grade IV: 0.75  
Low Ki-67 and high Ki-67: 0.82  
67: 0.82

**Table-2:** Predicting Overall Survival and Treatment response.

Author	Type of Tumor (n)	Machine Learning Model	Objective	Performance Parameters (Accuracy, AUC, DICE Coefficient, C-index/indices)
Geraghty et al. <sup>38</sup> 2022	IDH-Wildtype Glioblastoma Multiforme(235)	Linear Regression	Explore the role postoperative radiation planning MRI – based radiomics to predict the outcomes, with features extracted from the gross tumour volume and clinical target volume	Combined radiomics and clinical model (AUC): 0.632. GTR subgroup (AUC): 0.604 STR subgroup (AUC): 0.523 Biopsy subgroup (AUC): 0.632.
Computer et al. <sup>8</sup> 2021	Glioblastoma Multiforme(218)	Cox Regression	Prognostic value of Computed Tomography radiomics for overall survival.	Clinical Prognostic Score: 0.63-0.65, Volume-based Score: 0.52-0.61 Complex Radiomics Prognostic Score: 0.57-0.64 Clinical + Radiomics model: 0.59-0.71
Fathj Kazerooni et al. <sup>39</sup> 2022	Glioblastoma Multiforme(516)	Multivariate Cox-PH	To predict progression free survival (PFS) and overall survival (OS)	OS (AUC); Clinical: 0.623, Genetic: 0.588, Radiomics: 0.649, Combined: 0.725 PFS (AUC); Clinical: 0.582, Genetic: 0.587, Radiomics: 0.616, Combined: 0.670
Choi et al. <sup>40</sup> 2020	Low Grade Glioma(296)	Random Forest	Evaluate whether MRI-based radiomic features could improve the accuracy of survival predictions for lower grade gliomas over clinical and IDH status.	Clinical and IDH status (AUC): 0.627 Clinical + radiomic features (AUC): 0.709
Garcia Ruiz et al. <sup>41</sup> 2021	Primary Glioblastoma Multiforme (GBM)(144)	Multivariate Logistic Regression	1. Quantification of the enhancing residual tumour through computational image analysis and assessment of correlation with survival. 2. Pathological enhancement thickness on post-surgical MRI correlated with survival	Prognostic capacity for predicting long and short survival (AUC): 0.72
George et al. <sup>42</sup> 2022	Glioblastoma Multiforme(154)	Random Forest	Prediction of progression free survival and overall survival in patients with glioblastoma on PD-L1 inhibition immunotherapy	Predictive value for OS and PFS: C-index = 0.472–0.521 Predictive value for first on-treatment MR imaging: C-index = 0.692–0.750 (OS) and 0.680–0.715 (PFS)
Choi et al. <sup>43</sup> 2021	Glioblastoma Multiforme(120)	k-Nearest Neighbours (kNN), Naïve Bayes, Random Forest and Support vector machine (SVM)	Prognostic value of multivariate models in glioblastoma	Accuracy Transcriptome subtypes: Classical (70.9), Mesenchymal (73.3), Neural (88.4), Perineural (88.4) AUC Transcriptome subtypes: Classical (0.711), Mesenchymal (0.763), Neural (0.745), Perineural

Continued on next page...

Continued from previous page...

(0.854)				
Dasgupta et al. <sup>44</sup> 2021	Low Grade Glioma: 34 Brain Metastasis: 29	Support Vector Machine	Region's indicative of infiltrative tumours was correlated to the future areas of radiological disease recurrence	Accuracy of 0.92 and 0.79 in the training and test set, respectively (LGG vs. BM)
Li et al. <sup>21</sup> 2020	Gliomas(51)	Random Forest And Deep Learning	Identification of immunohistochemical typing, to achieve the image-indication of tumour progression, angiogenesis, proliferation or invasion.	Accuracy Ki-67: 66.0, S-100: 0.898, Vimentin: 0.738, CD34: 0.667 AUC Ki-67: 0.713±0.073, S-100: 0.92±0.0381 Vimentin: 0.854±0.0579, CD34: 0.745±0.077
Beig et al. <sup>45</sup> 2020	Glioblastoma Multiforme(203)	Cox Regression Model	1. Create a survival risk-score using radiomic features from the tumour habitat on routine MRI to predict progression-free survival in Glioblastoma. 2. Obtain a biological basis for prognostic radiomic features, by studying radio-genomic associations with molecular signaling pathways	Combination of Radiomic Risk Score with clinical (age, gender) and molecular features (MGMT, IDH status) resulted in a concordance index of 0.81 (p <0.0001) on training and 0.84 (p = 0.03) on the test set
Jiang et al. <sup>46</sup> 2022	Brain Metastasis with lung cancer (LCBM)(137)	Random forest with five-fold cross validation	Predicting the posttreatment response of LCBM to Gamma Knife Radiosurgery, facilitating the adjustment in treatment strategy	AUC RFTC+RFPE: 0.852 0.848, RFTC: 0.750 CBV map: 0.714, ADC map: 0.598 Post-contrast T1WI: 0.557 T2-FLAIR: 0.704, T1WI: 0.656, T2WI: 0.725 RF Score (AUC): 0.848
Ari et al. <sup>47</sup> 2022	High Grade Primary tumours (131)	Generalized Boosted Regression Model	Predicting pseudo progression in a representative patient cohort diagnosed with high grade adult-type diffuse gliomas (WHO grade 3 and 4).	Occurrence of pseudo progression with an AUC, mean sensitivity, mean specificity and mean accuracy of 91.49%, 79.92%, 88.61% and 84.35% in the full development group 78.51%, 66.26%, 78.31% and 72.40% in the testing group 72.87%, 71.75%, 80.00% and 76.04% in the independent validation sample
Jing et al. <sup>32</sup> 2022	Gliomas118	SMOTE and un sampling algorithms were employed.	Early differential diagnosis of recurrence versus pseudo progression.	Accuracy Training group: T1: 80.72, T2: 72.29, T1+T2: 77.11 Test group: T1: 80.00, T2: 77.14, T1+T2: 88.57 AUC Training group: T1 + T2: 0.831, T1: 0.815, T2: 0.745 Test group: T1 + T2: 0.829, T1: 0.804, T2: 0.734

**Table-3:** Predicting mutations and biomarker status.

Author	Type of tumour (n)	Machine Learning Model	Objective	Performance Parameters (Accuracy, AUC, DICE Coefficient, C-index/indices)
Choi et al. <sup>9</sup> 2021	Glioma1166	CNN and binary classifier	Prediction of IDH status and characterization of gliomas.	Accuracy:93.8, 87.9, 78.8 AUC:0.96, 0.94, 0.86 DICE:0.86-0.92

Continued on next page...



## Continued from previous page...

Kim et al. <sup>34</sup> 2020	LGG155	SVM and random forest algorithm	Predicting IDH mutation status and tumour grading	IDH mutation status:(Accuracy): 65.3% IDH Mutation (AUC) Multiparametric MRI: Training set 0.795, Validation set 0.747 Conventional MRI: Training set 0.729, Validation set: 0.705 Tumour Grading (AUC) Multiparametric MRI: Training: 0.932, Validation: 0.819 Conventional MRI Training: 0.555, Validation: 0.644
Le et al. <sup>10</sup> 2021	GBM120	XGBoost algorithm	Classification of GBM transcriptome sub types	Accuracy Classical: 70.9% Mesenchymal: 73.3% Neural: 80.4% Perineural 80.4%
Cao et al. <sup>48</sup> 2021	LGG102	Random forest	Characterize the IDH1 mutation status in LGGs.	Accuracy: Training: 0.70 to 0.76 Validation: 0.56 to 0.64
Bhandari et al. <sup>49</sup> 2021	LGG1655	SVM + Deep Learning	Classifying IDH and 1p19q status using MR imaging radiomics	Best classifier of IDH status (AUC)= 0.95. The best classifier of 1p19q status (AUC): 0.96.
Casale et al. <sup>50</sup> 2021	LGG209	Random Forest	Predicting the 1p/19q status of LGG from MRI images using texture analysis as an alternative to surgical biopsy	Accuracy Training Cubic interpolation: 0.86, Linear interpolation: 0.76 Validation Cubic interpolation: 0.72 Linear interpolation: 0.72 AUC: Training Cubic interpolation: 0.86 Linear interpolation: 0.82 Validation Cubic interpolation: 0.87 Linear interpolation: 0.77
Choi et al. <sup>11</sup> 2020	Grade IV Glioblastoma136		Compare IDH mutation status predictive performances between manual and fully automatic deep-learning segmentations	Accuracy: Manual: 86.8 % V-net: 75.8 % Development set: 73.3 % AUC: Manual: 0.904 V-net: 0.857 Development set: 0.771
Ahn et al. <sup>51</sup> 2020	Lung cancer with Brain Metastasis(210)	Random Forest,	Predicting EGFR mutation status in primary lung cancers	Identifying EGFR mutation (AUC): 86.81 Subgroup analyses revealed that small brain metastasis had the highest AUC: 89.09 The diagnostic performance for large BMs was lower than that for small brain metastasis (AUC): 78.22
Calabrese et al. <sup>52</sup> 2020	Glioblastoma199	Random Forest	Predicting genetic biomarker status in glioblastomas using preoperative imaging	AUC: TRX: 0.97 IDH: 0.95 7/10 aneuploidy: 0.93 CDKN2: 0.85 EGFR: 0.70

Continued on next page...

Continued from previous page...

				TERT: 0.65 PTEN: 0.64 TP53: 0.57 MGMT: 0.55
Kandemirli et al. <sup>12</sup> 2021	Gliomas(109)	Extreme gradient boosting algorithm(XGBoost)	Predict H3K27M mutation in midline gliomas	Accuracy: 72.7% AUC Training: 0.791 Validation: 0.737
Kocak et al. <sup>53</sup> 2020	LGG(107)	Adaptive boosting, k-nearest neighbours, naive Bayes, neural network, random forest, stochastic gradient descent; and support vector machine	Predicting the 1p/19q codeletion status of LGGs	Accuracy: Adaptive boosting: 75.2, k-nearest neighbours: 74.4, Naive Bayes: 80.3, Neural network: 83.8 Random Forest: 84.0, Stochastic gradient descent: 80.1, Support vector machine: 81.1 AUC: Adaptive boosting: 0.717, k-nearest neighbours: 0.751, Naive Bayes: 0.829, Neural network: 0.869 Random Forest: 0.840, Stochastic gradient descent: 0.769, Support vector machine: 0.838
Li et al. <sup>54</sup> 2022	Brain Metastasis(186)	Random Forest	Identifying EGFR and ALK mutation status in brain metastasis and exploring which MR sequence is most predictive.	Training (AUC) T2-FLAIR: 0.991 T1-CE: 0.954 T2WI: 0.880 Testing T2-FLAIR: 0.950 T1-CE: 0.867 T2WI: 0.731
He et al. <sup>55</sup> 2022	Glioma81	Multivariate Logistic Regression	Explored clinical and MRI imaging characteristics to predict four kinds of glioma molecular biomarkers (IDH, MGMT, TERT, 1p/19q)	Clinical model (AUC) IDH: 0.88; MGMT: 0.78; TERT: 0.66; 1p/19q: 0.66 Radiomics model (AUC) IDH: 0.87, MGMT: 0.83, TERT: 0.72, 1p/19q: 0.68

covariates on the survival outcome.

We found Cox regression and Random Forest algorithms as the most common methods being used when building a model to predict overall survival rates and tumour prognostication analysis. A Cox regression is commonly useful when evaluating the time to an event, therefore was found to be a common method when evaluating OS using selected features. Computer et al, in their study used age and WHO performance status as predictors to build the regression with a clinical prognostic score of 0.63-0.65.<sup>8</sup> However, a Cox regression is limited by its assumption of potential hazards - the assumption that the hazard function remains constant over time and is only a function of the explanatory variables. To counter this limitation, we found multiple studies, opting for the use of a random forest trained model to predict OS based on radiomic features, clinical profile, and IDH mutation status. A RF model is able to handle interactions of hundreds of radiomics features, not limiting itself to selected specialized explanatory variables such as in a Cox regression. This allows the use of MRI based radiomic

features, leading to an increased accuracy of progression free survival predictions. Choi et al.<sup>9</sup> conducted a cohort study of LGG patients and found that MRI based radiomics features improved accuracy of the model from 0.627 to an AUC reading of 0.709.<sup>9</sup> Other studies using RF models also saw increased accuracy in their predictions thereby confirming the benefits of using the model in radiomic phenotyping.

Traditionally, identification of biomarkers in brain tumours has been done through labour-intensive and time-consuming methods of DNA sequencing and PCR, prone to errors with limited sensitivity. The financial cost associated with this traditional method is extremely high and unaffordable for most patients therefore, not all molecular testing is available within LMICs. This severely limits the application of new, established markers within our regions which impacts patient selection, survival, and treatment protocols. Our review found that machine learning models, using radiomic features, are increasingly being proven to be effective in predicting the presence of these key biomarkers. Our review shows that various

models are being used but RF and Support Vector Machine (SVM) prevailed as the most common due to their relative better performance in handling large complex data sets, tumour classifications and predicting patterns in comparison to traditional statistical classifiers. Cao et al 2021,<sup>10</sup> was able to use VASARI features extracted from conventional MRI's and selected through RMR (Relevance Minimum Redundancy) as an input to their trained RF to create a model to predict the presence of the IDH/IDH1 mutation. The model achieved an area under ROC curve (AUC) of 0.779 for the training cohort and 0.849 for the validation cohort. The accuracy was further improved when further radiomics features were added thereby confirming the validity of using RF to create a predictive model for the presence of the IDH1 mutation. In addition to predicting IDH mutations, random forest algorithm is also used to predict EGFR mutation status. According to Ahn et al, a model trained with RF to identify an EGFR mutation presented an AUC of 86.81. RF was also effective in the identification of the 1p19q gene in tumours.<sup>11</sup> However, we also found support Vector Machine (SVM) coupled with a deep learning machine to be highly accurate and precise. According to Kocak et al, the accuracy of random forest model for predicting 1p19q mutation status was 84.0, while SVM remained almost equally as accurate at 81.1.<sup>12</sup> CNS tissue samples are difficult to obtain and preoperative localization of mutations and molecular characteristics of brain tumours using radio genomics can open up avenues for neo-adjuvant therapy and personalized medicine.

Both traditional classifiers and deep learning have their strengths and weaknesses, and the choice between the two approaches depends on the nature of the task and availability of resources. Traditional classifiers have their strength in interpretability and efficiency for certain tasks and smaller datasets, while deep learning excels in handling complex data, large datasets, and tasks where feature engineering is challenging. The choice between the two approaches depends on the specific problem, available data, and implementation details.<sup>13,14</sup>

Low- and Middle-Income Countries (LMICs) face several challenges in translating radio genomic and artificial intelligence technologies into clinical practice. High expenses for hardware, software, maintenance and limited access to advanced medical infrastructure, including high-quality imaging equipment and computing resources limit their widespread adoption. Lack of large and high-quality datasets limit development and validation of robust models' radio genomic and AI-based systems. Successful implementation of these systems requires a skilled workforce with expertise in

both radiology and data science. In LMICs, there is a shortage of trained professionals, making it challenging to develop, validate, and implement these technologies effectively.

Furthermore, integrating AI into clinical practice raises ethical concerns pertaining to patient privacy, data security, and potential biases in the algorithms. In LMICs, there may be limited regulations and guidelines specific to AI in healthcare, leading to uncertainty and hesitancy in adopting these technologies. In some regions, there may be cultural or societal barriers to accepting AI technologies and patients and healthcare providers may be hesitant to trust automated systems over traditional human expertise. Many AI models are developed and validated on datasets from high-income countries, which may not fully represent the diverse populations and diseases prevalent in LMICs. This lack of external validation can limit the generalizability and accuracy of AI systems in these settings.<sup>15,16</sup>

## Conclusion

AI-driven solutions and ML models are a non-invasive and low-cost technology for diagnostics compared to surgical biopsy and histopathological diagnosis. Radiomics and radio genomic models have proven to be useful in various steps of brain tumour management including diagnosis, grading, subtyping of tumours, survival prediction and treatment planning. Use of AI in conjunction with healthcare behaviours, socioeconomic factors and education can result in greater chances of improving overall neurooncological management within LMICs.

**Disclaimer:** None.

**Conflict of Interest:** None.

**Funding Disclosure:** None.

## References

1. Mohammadi E, Ghasemi E, Azadnajafabad S, Rezaei N, Saeedi Moghaddam S, Ebrahimi Meimand S, et al. A global, regional, and national survey on burden and Quality of Care Index (QCI) of brain and other central nervous system cancers; global burden of disease systematic analysis 1990-2017. *PLoS One* 2021;16:e0247120. doi: 10.1371/journal.pone.0247120.
2. Jena B, Saxena S, Nayak GK, Balestrieri A, Gupta N, Khanna NN, et al. Brain Tumor Characterization Using Radiogenomics in Artificial Intelligence Framework. *Cancers (Basel)* 2022;14:4052. doi: 10.3390/cancers14164052.
3. Shur JD, Doran SJ, Kumar S, Ap Dafydd D, Downey K, O'Connor JPB, et al. Radiomics in Oncology: A Practical Guide. *Radiographics* 2021;41:1717-32. doi: 10.1148/rg.2021210037.
4. Yi Z, Long L, Zeng Y, Liu Z. Current Advances and Challenges in Radiomics of Brain Tumors. *Front Oncol* 2021;11:732196. doi: 10.3389/fonc.2021.732196.
5. Bodalal Z, Trebeschi S, Nguyen-Kim TDL, Schats W, Beets-Tan R.

- Radiogenomics: bridging imaging and genomics. *Abdom Radiol (NY)* 2019;44:1960-84. doi: 10.1007/s00261-019-02028-w.
6. Javaid M, Haleem A, Singh RP, Suman R, Rab S. Significance of machine learning in healthcare: Features, pillars and applications. *Int J Intell Netw* 2022;3:58-73. doi:10.1016/j.ijin.2022.05.002.
  7. He J, Ren J, Niu G, Liu A, Wu Q, Xie S, et al. Multiparametric MR radiomics in brain glioma: models comparison to predict biomarker status. *BMC Med Imaging* 2022;22:137. doi: 10.1186/s12880-022-00865-8.
  8. Compter I, Verduin M, Shi Z, Woodruff HC, Smeenk RJ, Rozema T, et al. Deciphering the glioblastoma phenotype by computed tomography radiomics. *Radiother Oncol* 2021;160:132-9. doi: 10.1016/j.radonc.2021.05.002.
  9. Choi YS, Bae S, Chang JH, Kang SG, Kim SH, Kim J, et al. Fully automated hybrid approach to predict the IDH mutation status of gliomas via deep learning and radiomics. *Neuro Oncol* 2021;23:304-13. doi: 10.1093/neuonc/noaa177.
  10. Le NQK, Hung TNK, Do DT, Lam LHT, Dang LH, Huynh TT. Radiomics-based machine learning model for efficiently classifying transcriptome subtypes in glioblastoma patients from MRI. *Comput Biol Med* 2021;132:104320. doi: 10.1016/j.combiomed.2021.104320.
  11. Choi Y, Nam Y, Lee YS, Kim J, Ahn KJ, Jang J, et al. IDH1 mutation prediction using MR-based radiomics in glioblastoma: comparison between manual and fully automated deep learning-based approach of tumor segmentation. *Eur J Radiol* 2020;128:109031. doi: 10.1016/j.ejrad.2020.109031.
  12. Kandemirli SG, Kocak B, Naganawa S, Ozturk K, Yip SSF, Chopra S, et al. Machine Learning-Based Multiparametric Magnetic Resonance Imaging Radiomics for Prediction of H3K27M Mutation in Midline Gliomas. *World Neurosurg* 2021;151:e78-85. doi: 10.1016/j.wneu.2021.03.135.
  13. Krizhevsky A, Sutskever I, Hinton GE. ImageNet classification with deep convolutional neural networks. *Commun ACM* 2017;60:84-90. Doi: 10.1145/3065386.
  14. Ribeiro MT, Singh S, Guestrin C. "Why Should I Trust You?": Explaining the Predictions of Any Classifier. In: *Proceedings of the 22nd ACM SIGKDD International Conference on Knowledge Discovery and Data Mining*. San Francisco California, USA: Association for Computing Machinery (ACM) Inc, 2016; pp 1135-44. [Online] 2016 [Cited 2023 September 08]. Available from URL: <https://dl.acm.org/doi/10.1145/2939672.2939778>
  15. Hosny A, Parmar C, Quackenbush J, Schwartz LH, Aerts HJWL. Artificial intelligence in radiology. *Nat Rev Cancer* 2018;18:500-1. doi: 10.1038/s41568-018-0016-5.
  16. Mollura DJ, Culp MP, Pollack E, Battino G, Scheel JR, Mango VL, et al. Artificial Intelligence in Low- and Middle-Income Countries: Innovating Global Health Radiology. *Radiology* 2020;297:513-20. doi: 10.1148/radiol.2020201434.
  17. Di Stefano AL, Picca A, Saragoussi E, Bielle F, Ducray F, Villa C, et al. Clinical, molecular, and radiomic profile of gliomas with FGFR3-TACC3 fusions. *Neuro Oncol* 2020;22:1614-24. doi: 10.1093/neuonc/noaa121.
  18. Bijari S, Jahanbakhshi A, Hajishafiezharamini P, Abdolmaleki P. Differentiating Glioblastoma Multiforme from Brain Metastases Using Multidimensional Radiomics Features Derived from MRI and Multiple Machine Learning Models. *Biomed Res Int* 2022;2022:e2016006. doi: 10.1155/2022/2016006.
  19. Dong F, Li Q, Jiang B, Zhu X, Zeng Q, Huang P, et al. Differentiation of supratentorial single brain metastasis and glioblastoma by using peri-enhancing oedema region-derived radiomic features and multiple classifiers. *Eur Radiol* 2020;30:3015-22. doi: 10.1007/s00330-019-06460-w.
  20. Jian A, Jang K, Manuguerra M, Liu S, Magnussen J, Di Ieva A. Machine Learning for the Prediction of Molecular Markers in Glioma on Magnetic Resonance Imaging: A Systematic Review and Meta-Analysis. *Neurosurgery* 2021;89:31-44. doi: 10.1093/neuros/nyab103.
  21. Li J, Liu S, Qin Y, Zhang Y, Wang N, Liu H. High-order radiomics features based on T2 FLAIR MRI predict multiple glioma immunohistochemical features: A more precise and personalized gliomas management. *PLoS One* 2020;15:e0227703. doi: 10.1371/journal.pone.0227703.
  22. Bae S, An C, Ahn SS, Kim H, Han K, Kim SW, et al. Robust performance of deep learning for distinguishing glioblastoma from single brain metastasis using radiomic features: model development and validation. *Sci Rep* 2020;10:12110. doi: 10.1038/s41598-020-68980-6.
  23. Fan Y, Huo X, Li X, Wang L, Wu Z. Non-invasive preoperative imaging differential diagnosis of pineal region tumor: A novel developed and validated multiparametric MRI-based clinicoradiomic model. *Radiother Oncol* 2022;167:277-84. doi: 10.1016/j.radonc.2022.01.005.
  24. Li M, Wang H, Shang Z, Yang Z, Zhang Y, Wan H. Ependymoma and pilocytic astrocytoma: Differentiation using radiomics approach based on machine learning. *J Clin Neurosci* 2020;78:175-80. doi: 10.1016/j.jocn.2020.04.080.
  25. Cao G, Zhang J, Lei X, Yu B, Ai Y, Zhang Z, et al. Differentiating Primary Tumors for Brain Metastasis with Integrated Radiomics from Multiple Imaging Modalities. *Dis Markers* 2022;2022:5147085. doi: 10.1155/2022/5147085.
  26. Chang FC, Wong TT, Wu KS, Lu CF, Weng TW, Liang ML, et al. Magnetic resonance radiomics features and prognosticators in different molecular subtypes of pediatric Medulloblastoma. *PLoS One* 2021;16:e0255500. doi: 10.1371/journal.pone.0255500.
  27. Jalalifar A, Soliman H, Ruschin M, Sahgal A, Sadeghi-Naini A. A Brain Tumor Segmentation Framework Based on Outlier Detection Using One-Class Support Vector Machine. *Annu Int Conf IEEE Eng Med Biol Soc* 2020;2020:1067-70. doi: 10.1109/EMBC44109.2020.9176263.
  28. Dong J, Li L, Liang S, Zhao S, Zhang B, Meng Y, et al. Differentiation Between Ependymoma and Medulloblastoma in Children with Radiomics Approach. *Acad Radiol* 2021;28:318-27. doi: 10.1016/j.acra.2020.02.012.
  29. Chen BT, Jin T, Ye N, Mambetsariev I, Daniel E, Wang T, et al. Radiomic prediction of mutation status based on MR imaging of lung cancer brain metastases. *Magn Reson Imaging* 2020;69:49-56. doi: 10.1016/j.mri.2020.03.002.
  30. Kandemirli SG, Chopra S, Priya S, Ward C, Locke T, Soni N, et al. Presurgical detection of brain invasion status in meningiomas based on first-order histogram based texture analysis of contrast enhanced imaging. *Clin Neurol Neurosurg* 2020;198:106205. doi: 10.1016/j.clineuro.2020.106205.
  31. Huang ZS, Xiao X, Li XD, Mo HZ, He WL, Deng YH, et al. Machine Learning-Based Multiparametric Magnetic Resonance Imaging Radiomic Model for Discrimination of Pathological Subtypes of Craniopharyngioma. *J Magn Reson Imaging* 2021;54:1541-50. doi: 10.1002/jmri.27761.
  32. Jing H, Yang F, Peng K, Qin D, He Y, Yang G, et al. Multimodal MRI-Based Radiomic Nomogram for the Early Differentiation of Recurrence and Pseudoprogression of High-Grade Glioma. *Biomed Res Int* 2022;2022:e4667117. doi: 10.1155/2022/4667117.
  33. Han Y, Yang Y, Shi ZS, Zhang AD, Yan LF, Hu YC, et al. Distinguishing brain inflammation from grade II glioma in population without contrast enhancement: a radiomics analysis based on conventional MRI. *Eur J Radiol* 2021;134:109467. doi: 10.1016/j.ejrad.2020.109467.
  34. Kim M, Jung SY, Park JE, Jo Y, Park SY, Nam SJ, et al. Diffusion- and perfusion-weighted MRI radiomics model may predict isocitrate dehydrogenase (IDH) mutation and tumor aggressiveness in

- diffuse lower grade glioma. *Eur Radiol* 2020;30:2142-51. doi: 10.1007/s00330-019-06548-3.
35. Hashido T, Saito S, Ishida T. Radiomics-Based Machine Learning Classification for Glioma Grading Using Diffusion- and Perfusion-Weighted Magnetic Resonance Imaging. *J Comput Assist Tomogr* 2021;45:606-13. doi: 10.1097/RCT.0000000000001180.
  36. Cheng J, Liu J, Yue H, Bai H, Pan Y, Wang J. Prediction of Glioma Grade Using Intratumoral and Peritumoral Radiomic Features From Multiparametric MRI Images. *IEEE/ACM Trans Comput Biol Bioinform* 2022;19:1084-95. doi: 10.1109/TCBB.2020.3033538.
  37. Guo J, Ren J, Shen J, Cheng R, He Y. Do the combination of multiparametric MRI-based radiomics and selected blood inflammatory markers predict the grade and proliferation in glioma patients? *Diagn Interv Radiol* 2021;27:440-9. doi: 10.5152/dir.2021.20154.
  38. Geraghty BJ, Dasgupta A, Sandhu M, Malik N, Maralani PJ, Detsky J, et al. Predicting survival in patients with glioblastoma using MRI radiomic features extracted from radiation planning volumes. *J Neurooncol* 2022;156:579-88. doi: 10.1007/s11060-021-03939-9.
  39. Fathi Kazerooni A, Saxena S, Toorens E, Tu D, Bashyam V, Akbari H, et al. Clinical measures, radiomics, and genomics offer synergistic value in AI-based prediction of overall survival in patients with glioblastoma. *Sci Rep* 2022;12:8784. doi: 10.1038/s41598-022-12699-z.
  40. Choi YS, Ahn SS, Chang JH, Kang SG, Kim EH, Kim SH, et al. Machine learning and radiomic phenotyping of lower grade gliomas: improving survival prediction. *Eur Radiol* 2020;30:3834-42. doi: 10.1007/s00330-020-06737-5.
  41. Garcia-Ruiz A, Naval-Baudin P, Ligerio M, Pons-Escoda A, Bruna J, Plans G, et al. Precise enhancement quantification in post-operative MRI as an indicator of residual tumor impact is associated with survival in patients with glioblastoma. *Sci Rep* 2021;11:695. doi: 10.1038/s41598-020-79829-3.
  42. George E, Flagg E, Chang K, Bai HX, Aerts HJ, Vallières M, et al. Radiomics-Based Machine Learning for Outcome Prediction in a Multicenter Phase II Study of Programmed Death-Ligand 1 Inhibition Immunotherapy for Glioblastoma. *AJNR Am J Neuroradiol* 2022;43:675-81. doi: 10.3174/ajnr.A7488.
  43. Choi Y, Nam Y, Jang J, Shin NY, Lee YS, Ahn KJ, et al. Radiomics may increase the prognostic value for survival in glioblastoma patients when combined with conventional clinical and genetic prognostic models. *Eur Radiol* 2021;31:2084-93. doi: 10.1007/s00330-020-07335-1.
  44. Dasgupta A, Geraghty B, Maralani PJ, Malik N, Sandhu M, Detsky J, et al. Quantitative mapping of individual voxels in the peritumoral region of IDH-wildtype glioblastoma to distinguish between tumor infiltration and edema. *J Neurooncol* 2021;153:251-6. doi: 10.1007/s11060-021-03762-2.
  45. Beig N, Bera K, Prasanna P, Antunes J, Correa R, Singh S, et al. Radiogenomic-Based Survival Risk Stratification of Tumor Habitat on Gd-T1w MRI Is Associated with Biological Processes in Glioblastoma. *Clin Cancer Res* 2020;26:1866-7. doi: 10.1158/1078-0432.CCR-19-2556.
  46. Jiang Z, Wang B, Han X, Zhao P, Gao M, Zhang Y, et al. Multimodality MRI-based radiomics approach to predict the posttreatment response of lung cancer brain metastases to gamma knife radiosurgery. *Eur Radiol* 2022;32:2266-76. doi: 10.1007/s00330-021-08368-w.
  47. Ari AP, Akkurt BH, Musigmann M, Mammadov O, Blömer DA, Kasap DNG, et al. Pseudoprogression prediction in high grade primary CNS tumors by use of radiomics. *Sci Rep* 2022;12:5915. doi: 10.1038/s41598-022-09945-9.
  48. Cao M, Suo S, Zhang X, Wang X, Xu J, Yang W, et al. Qualitative and Quantitative MRI Analysis in IDH1 Genotype Prediction of Lower-Grade Gliomas: A Machine Learning Approach. *Biomed Res Int* 2021;2021:e1235314. doi: 10.1155/2021/1235314.
  49. Bhandari AP, Liang R, Koppen J, Murthy SV, Lasocki A. Noninvasive Determination of IDH and 1p19q Status of Lower-grade Gliomas Using MRI Radiomics: A Systematic Review. *AJNR Am J Neuroradiol* 2021;42:94-101. doi: 10.3174/ajnr.A6875.
  50. Casale R, Lavrova E, Sanduleanu S, Woodruff HC, Lambin P. Development and external validation of a non-invasive molecular status predictor of chromosome 1p/19q co-deletion based on MRI radiomics analysis of Low Grade Glioma patients. *Eur J Radiol* 2021;139:109678. doi: 10.1016/j.ejrad.2021.109678.
  51. Ahn SJ, Kwon H, Yang JJ, Park M, Cha YJ, Suh SH, et al. Contrast-enhanced T1-weighted image radiomics of brain metastases may predict EGFR mutation status in primary lung cancer. *Sci Rep* 2020;10:8905. doi: 10.1038/s41598-020-65470-7.
  52. Calabrese E, Villanueva-Meyer JE, Cha S. A fully automated artificial intelligence method for non-invasive, imaging-based identification of genetic alterations in glioblastomas. *Sci Rep* 2020;10:11852. doi: 10.1038/s41598-020-68857-8.
  53. Kocak B, Durmaz ES, Ates E, Sel I, Turgut Gunes S, Kaya OK, et al. Radiogenomics of lower-grade gliomas: machine learning-based MRI texture analysis for predicting 1p/19q codeletion status. *Eur Radiol* 2020;30:877-86. doi: 10.1007/s00330-019-06492-2.
  54. Li Y, Lv X, Wang B, Xu Z, Wang Y, Gao S, et al. Differentiating EGFR from ALK mutation status using radiomics signature based on MR sequences of brain metastasis. *Eur J Radiol* 2022;155:110499. doi: 10.1016/j.ejrad.2022.110499.
  55. He J, Ren J, Niu G, Liu A, Wu Q, Xie S, et al. Multiparametric MR radiomics in brain glioma: models comparison to predict biomarker status. *BMC Med Imaging* 2022;22:137. doi: 10.1186/s12880-022-00865-8.

#### DISCLAIMER

Articles published in JPMA and Supplements of JPMA do not represent the views of the editor or editorial Board. Authors are solely responsible for the opinions expressed and the accuracy of the data.

The contribution of each author towards the published research included in this supplement is the responsibility of the authors and their institutions. It is expected to be in accordance and compliance with the ICMJE Guidelines.

Any questions/queries raised by readers should be directed to the corresponding author.

## SCOPING REVIEW

## Developing neuro-oncology clinical trials in low- and middle-income countries: a scoping review of the current literature

Mohammad Hamza Bajwa<sup>1</sup>, Faiza Urooj<sup>2</sup>, Hafiza Fatima Aziz<sup>3</sup>, Ahsan Ali Khan<sup>4</sup>, Kaynat Siddiqui<sup>5</sup>, Rabeet Tariq<sup>6</sup>, Muhammad Shakir<sup>7</sup>, Muhammad Ehsan Bari<sup>8</sup>, Syed Ather Enam<sup>9</sup>

### Abstract

Low- and middle-income countries (LMICs) have historically been under-represented in clinical trials, leading to a disparity in evidence-based recommendations for the management of neuro-oncological conditions. To address this knowledge gap, we conducted a scoping review to assess the current literature on clinical trials in neuro-oncology from LMICs. The eligibility criteria for inclusion in this review included clinical trials registered and conducted with human subjects, with available English language text or translation, and focussed on neuro-oncological cases. The literature search strategy captured 408 articles, of which 61 met these criteria, with a significant number of randomised controlled trials from specific LMICs. The review found that LMIC clinical trials have contributed significantly to understanding surgical, chemotherapeutic, and radiation therapy interventions for brain tumours, paediatric cancers, and the repurposing of drugs as new targets in neuro-oncology. These findings highlight the potential for expanding clinical trials research in neuro-oncology in LMICs, which may significantly impact global understanding and management of these conditions, particularly from diverse populations from the global south.

**Keywords:** neuro-oncology, brain tumour, drug Repositioning

**DOI:** <https://doi.org/10.47391/JPMA.S3.GNO-08>

### Introduction

Clinical trials are the foundation for defining new cancer treatment standards; comparing diagnostic or therapeutic approaches can broaden our understanding of the disease process, susceptible patient groups, and the path forward in disease management and remission. Clinical studies from diverse communities have helped

.....  
<sup>1,3-5,7-9</sup>Department of Neurosurgery, The Aga Khan University, Karachi, Pakistan. <sup>2</sup>The Aga Khan Medical College and University, Karachi, Pakistan. <sup>6</sup>Jumma Research Laboratories, The Aga Khan University, Karachi, Pakistan.

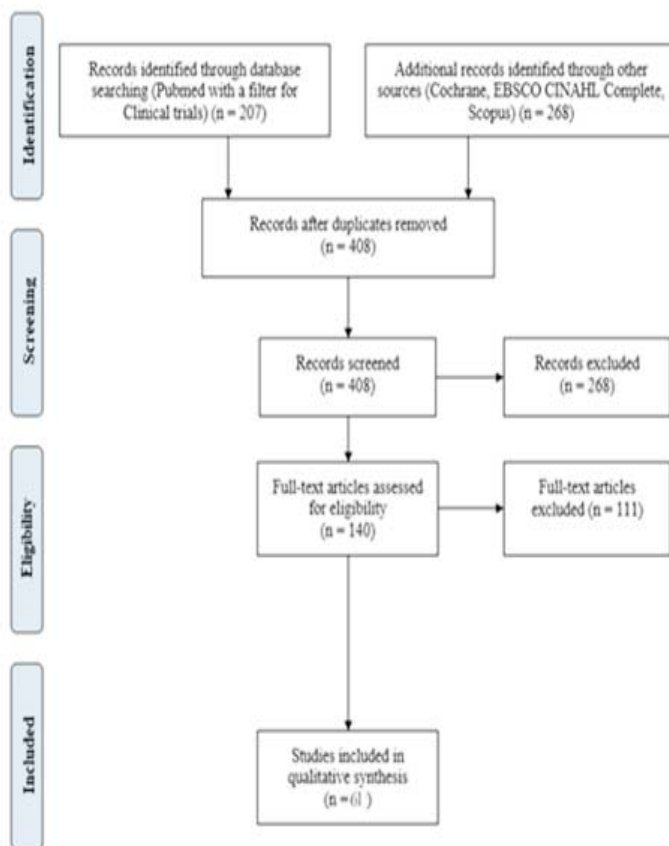
**Correspondence:** Syed Ather Enam **Email:** [ather.enam@aku.edu](mailto:ather.enam@aku.edu)

highlight the function of genetic composition and distinct populations that can be treated with particular, tailored treatment in many diseases, such as breast and lung illness. Similarly, the history of neuro-oncology clinical trials is littered with examples of big cohorts, multicentre investigations, and discovering innovations in treatment. However, historically, low- and middle-income countries (LMICs) have been under-represented in clinical trials, resulting in disparities in evidence-based recommendations for addressing neuro-oncological disorders in these locations. Clinical trials in neuro-oncology may be less common in LMICs for various reasons, including a lack of resources and infrastructure for conducting clinical trials, as well as cultural and socioeconomic variables that may influence patient recruitment and participation. Furthermore, gaining finance and regulatory permission for clinical studies in LMICs may be difficult.

Despite these limitations, there is a rising acknowledgment of the relevance of adding LMICs in neuro-oncology clinical trials. The molecular and socio-demographic epidemiology of neuro-oncological disorders in (LMICs) may differ from that in high-income countries (HICs), with major implications for therapy and management. For example, certain brain tumours and neurological malignancies may be more frequent in LMICs, and the frequency of certain risk factors may differ. As a result, clinical trials in LMICs may give useful insights into managing neuro-oncological disorders in these areas. Including LMICs in clinical trials can also assist in addressing global health inequities and guarantee that novel medicines are available to everyone. As a result, it is critical to continue emphasizing the inclusion of LMICs in neuro-oncology clinical trials to increase our understanding of these disorders and improve patient outcomes worldwide. The authors conducted a scoping review to capture the present status of neuro-oncological clinical trials and LMICs, highlight important strengths in LMIC clinical trial research, and recommend new paths for extending studies.

## Methods

A systematic search (Appendix 1) of multiple databases, (PubMed, Scopus, Cochrane Library, EBSCO) was conducted on 30.6.2023 using specific keywords related to clinical trials in neuro-oncology in LMICs (Figure 1). The search was limited to studies published in English or with available English translations. Eligibility criteria for inclusion in the review included clinical trials registered and conducted with human subjects, focussing on neuro-oncological cases. Non-trial studies, case reports, case series, systematic reviews, and meta-analyses were excluded. Post-hoc analyses and conference papers/abstracts were excluded. Two reviewers independently screened the titles and abstracts of the identified studies for eligibility, and full-text articles were obtained for those that met the inclusion criteria. Data were extracted from the included studies using a standardised form, including information on the study design, sample size, interventions, outcomes, and conclusions. Any discrepancies between the reviewers were resolved through discussion with a third senior



**Figure-1:** PRISMA Chart detailing the search methodology and systematic screening of articles.

author. The extracted data were analysed and synthesized to identify key themes and gaps in knowledge. The data were categorised into themes and subthemes, and the findings were compared and contrasted across studies.

## Results

We conducted an extensive literature review and identified 408 articles pertaining to the use of clinical trials to study and treat different types of brain tumours. Sixtyone articles were shortlisted after the title, abstract and full-text review – the results are detailed in tabulated forms Table 1<sup>1-34</sup>, Table 2<sup>35-46</sup>, Table 3<sup>47-57</sup> and Table 4<sup>58-61</sup>, according to treatment arms assessed and conclusions of the trial.

## Discussion

### Current state of clinical trials literature

Most clinical trials were conducted within the surgery, anaesthesiology, and critical care section(34 articles) – in comparison, we saw few clinical trials published in radiation and medical oncology. India and Egypt contributed significantly to the literature. Analysing the literature by categories and time points, within surgery and anaesthesiology, before 2010, historically, LMIC clinical trials in neuro-oncology have contributed towards investigating anaesthesia protocols for supratentorial tumour surgery, awake craniotomy, controlling ICP during pituitary surgery, PONV (postoperative nausea vomiting), and one study comparing pituitary surgery with the microscopic endo-nasal approach (Figure 2). A cursory view of this time period shows studies that were easily conducted due to small sample sizes and with varying cohorts – often, these would be mixed cohorts of supratentorial tumours, with no specific tumour subtype investigated. Post-2010, there is more specific diversification, with investigations of tranexamic acid for meningioma surgery, improving clinoidal meningioma resections with mobilisation of the cavernous sinus membrane, and image-guided surgery to compare intra-operative MRI and 2D-fluoroscopy for resection rates in pituitary macroadenoma surgery. There is still a plethora of literature generally investigated ideal postoperative and intraoperative medication regimens.

Twelve distinct trials were published regarding chemotherapy in LMICs. This appears to be mostly recent work, with only 2 publications from before 2010 – one investigating hydrocortisone replacement in DI post-trans-sphenoidal pituitary study, and adjuvant chemotherapy for paediatric high-risk medulloblastoma. A common trend in recent publications (post-2020) is reducing doses to minimize side effects from chemotherapeutic agents: an investigation in 2020

**Table-1:** Surgery, Anaesthesiology, Critical Care (n = 34)

No.	Year	Author	Country	Type of Tumour (n)	Treatment Arms	Outcomes Assessed/Conclusion
1	2017	Hooda et al. <sup>1</sup>	India	Meningioma (60)	Tranexamic acid group: intravenous bolus of 20 mg/kg over 20 min followed by an infusion of 1 mg/kg/h till conclusion of surgery	Blood loss significantly less in TXA group compared to placebo (830 ml vs 1124 ml; p = 0.03). Transfusion requirement less in tranexamic acid group (p > 0.05), patients fared better on 5-grade surgical haemostasis scale with good haemostasis (p = 0.007)
2	2012	Bansal et al. <sup>2</sup>	India	Supratentorial (80)	Cases (Craniotomy) Propofol: 19, Fentanyl and propofol: 21  Controls (Spinal Surgery) Propofol:19, Fentanyl and propofol: 21	Propofol dose for induction of anaesthesia was significantly reduced when administered after fentanyl in patients with supratentorial tumours.
3	2021	Barik et al. <sup>3</sup>	India	Supratentorial (90)	Group 1: equimolar 20% mannitol Group 2: 3% hypertonic saline Group 3: 8.4% sodium bicarbonate	8.4% sodium bicarbonate solution infusion is associated with superior intraoperative brain relaxation scores and improved hemodynamic stability compared to equimolar 3% hypertonic saline solution and 20% mannitol.
4	2008	Bhagat et al. <sup>4</sup>	India	Supratentorial (150)	Group 1: Low-dose propofol Group 2: Fentanyl Group 3: Isoflurane At the time of dural closure, until the beginning of skin closure	Low-dose fentanyl during craniotomy closure is more advantageous than propofol or isoflurane for early emergence in neurosurgical patients and most effective for preventing early postoperative hypertension
5	2022	Chandra et al. <sup>5</sup>	Indonesia	Intracranial -(60)	Group 1: Intravenous bolus of lidocaine (2%) 1.5 mg/kg before induction followed by 2 mg/kg/h continuous infusion up to skin closure Group 2: Placebo	Continuous lidocaine intravenous infusion improves brain relaxation after dura opening, and decreases intraoperative opioid consumption
6	2007	Gupta et al. <sup>6</sup>	India	Intrinsic eloquent area lesions	Awake group: 26 General anaesthesia group: 27	Mean operative time and blood loss were found to be less in GA group patients than in awake group. Better tumour cytoreduction, neurological improvement was seen in GA group than in awake group patients
7	2015	Ghoneim et al. <sup>7</sup>	Egypt	Supratentorial (60)	Group 1: Isoflurane Group 2: Sevoflurane Group 3: Desflurane	Desflurane and sevoflurane can be used to facilitate early emergence from anaesthesia in neurosurgical paediatric patients. Emergence times are shorter with desflurane or sevoflurane than with isoflurane. Desflurane or sevoflurane had similar intraoperative and postoperative incidence of adverse effects compared with those who received isoflurane
8	2018	Hegazy et al. <sup>8</sup>	Egypt	Spheno-clinoidal meningiomas without cavernous sinus involvement -(94)	Mobilization of the outer cavernous sinus membrane as a part of the surgical approach	Amount of blood loss and estimated blood loss were significantly less in the "with mobilization group" - mobilization group patients had a higher rate of radical resection
9	2018	Jonathan et al. <sup>9</sup>	India	Pituitary adenomas (60)	30 patients were randomly assigned to undergo trans-sphenoidal surgery with intraoperative	Intraoperative CSF drainage significantly reduced the incidence of CSF leak from 46.7% in the no LSAD group to 3.3% in the LSAD group (P < 0.001).



Continued from previous page...

					lumbar drain insertion (LSAD group) or no lumbar drain insertion (no LSAD group)	No statistically significant differences in the incidence of postoperative CSF rhinorrhoea between the two groups. No statistically significant difference in the extent of resection between the two groups.
10	2013	Beltagy et al <sup>10</sup>	Egypt	Paediatric fourth ventricular tumours (60)	Conventional micro neurosurgical techniques: 30 Neuro-navigated intraoperative ultrasonography (NIOUS) technique: 30	Total tumour excision was achieved in 96.7 % of NIOUS group versus 80 % in the conventional group. Mean operative time NIOUS group was 150 min versus 140.6 min in the conventional group. The mean operative blood loss was 67.5 ml NIOUS group versus 71 ml in the conventional group.
11	2021	Abdelhaleem <sup>11</sup>	Egypt	Supratentorial brain (52)	Block group (B): 26 received a bilateral trans nasal sphenopalatine ganglion block (SPGB) with 2% lidocaine	SPGB can control factors that increase cerebral blood flow during anaesthesia by the block of parasympathetic vasodilatory fibres to the arterial system in the anterior cerebral circulation, while neither hindering cerebral venous drainage nor impairing cerebral oxygenation
12	2017	Paul et al <sup>12</sup>	India	Supratentorial (60)	Desflurane: 30 Isoflurane: 30	Desflurane significantly reduced emergence times, and was able to facilitate an early neurological examination for patients.
13	2022	Rajkiran et al <sup>13</sup>	India	Supratentorial (110)	Group 1: Intravenous paracetamol Group 2: Intravenous diclofenac sodium 30 minutes before the end of surgery and postoperatively at 12-hour intervals up to 48 hours	Compared with paracetamol, diclofenac sodium provided more effective postoperative analgesia at 24 hours with no evidence of adverse effects on coagulation profiles
14	2022	Mishra et al <sup>14</sup>	India	Supratentorial (40)	Control: fluid regimen based on routine hemodynamic  Intervention: stroke volume variation guided therapy	No benefit of intervention over conventional intraoperative fluid therapy in terms of incidence of postoperative complications, hospital and ICU stay, and Glasgow outcome scores at-discharge  Use of guided fluids treatment led to better perioperative fluid management and brain relaxation scores.
15	2021	Konay et al <sup>15</sup>	India	Pituitary tumours (48)  Transsphenoidal surgery	Group 1: preoperative intranasal packing with 15ml 1.5% lidocaine with ephedrine	Similar hemodynamic stability during surgery, bleeding in field, and postoperative pain
16	2020	Sriganesh et al <sup>16</sup>	India	Supratentorial (24)	Group 1: fentanyl Group 2: dexmetomidine	Stress response to surgery is similar with opioid (fentanyl) and non-opioid (dexmedetomidine) analgesia as assessed by SPI (surgical pleth index) and blood markers such as cortisol, glucose, and pH.
17	2020	Singla et al <sup>17</sup>	India	Supratentorial (30)	Group 1: 5 ml/kg of 20% mannitol Group 2: 3% HTS (hypertonic saline)	Intraoperative brain relaxation was comparable; statistically significant difference in the mean arterial pressures (MAPs) between the two groups after one minutes (min) with a greater degree of decrease in blood pressure recorded in the mannitol group

Continued on next page...

Continued from previous page...

						Urine output was significantly higher in the mannitol group MAP with mannitol was significantly lower than the pre-induction value after 75 min of administration Administration of HTS was associated with a transient increase in serum sodium concentrations, which was statistically significant but returned to normal within 48 hours.
18	2019	Sriganesh et al <sup>18</sup>	India	Supratentorial (24)	Group 1: Fentanyl Group 2: Dexmedetomidine As primary intraoperative analgesic drug	Dexmedetomidine has the potential to be non-inferior to fentanyl for perioperative analgesia during craniotomies Compared between fentanyl and dexmedetomidine, there was no difference in the intraoperative fentanyl (top-up) and no difference in postoperative pain at 15 and 60 minutes. Adverse events were similar.
19	2017	Tandon et al <sup>19</sup>	India	Pituitary macroadenoma (50)	A: Intraoperative MRI (IOMRI) guided trans-sphenoidal pituitary resection: 25 B: 2Dimensional fluoroscopic guided resection: 25	Extent of resection was similar in both study arms (A, 94.9% vs B, 93.6%; p = 0.78), despite adjusting for experience of operating surgeon and use of microscope/endoscope for surgical resection. IOMRI helped optimize the extent of resection in 5/20 patients (25%) for pituitary tumor resection in-group A. Study failed to observe superiority of IOMRI over conventional 2D-F guided resection.
20	2017	Salimi et al <sup>20</sup>	Iran	Pituitary adenoma (60)	Dexmedetomidine infusion (0.6µg/kg/hour) or normal saline infusion	Propofol maintenance dose (µg/kg/min) and total Fentanyl use (µg) were significantly lower in Dex group compare to control group (P=0.01 and 0.003, respectively). Total bleeding amount during operation in Dex group was significantly lower than control group (P=0.012). Surgeon's satisfaction was significantly higher in Dex group at the end of surgery. MAP and heart rate throughout surgery were significantly lower in Dex group compare to control group
21	2013	Misra et al <sup>21</sup>	India	Adult intracranial tumours (63)	placebo (group D) or gabapentin (600 mg) (group GD) premedication orally, 2 hours before induction of anaesthesia. In addition, all patients received 4 mg of intravenous dexamethasone on the morning of surgery and continued receiving it after every 8 hours	gabapentin plus 4 mg of dexamethasone significantly reduced the 24-hour incidence of nausea and PONV. However, there was no reduction in either the postoperative pain scores or opioid consumption
22	2011	Soliman et al <sup>22</sup>	Egypt	Supratentorial (40)	Group A: —The dexmedetomidine was given as a bolus dose of 1 microg/kg in 20 minutes before induction of anaesthesia, followed by a maintenance infusion of 0.4 microg/kg/hr. The infusion was discontinued when surgery ended.	Continuous intraoperative infusion of dexmedetomidine during craniotomy for supratentorial tumours under general anaesthesia maintained the haemodynamic stability, reduced sevoflurane and fentanyl requirements, decreased intracranial pressure, and improved significantly the outcomes

Continued on next page...

Continued from previous page...

					Group B: —The patients received similar volumes of saline.	intraoperative end-tidal sevoflurane (%) in patients of group A less than in patients of group B (P-value <0.05). The intracranial pressure decreased in patients of Group A more than group B (P-value <0.05). The Glasgow coma scale (GCS) improved in patients of group A and deteriorated in patients of Group B with significant statistical difference between the two groups total fentanyl requirements from induction to extubating of patients increased in patients of group B more than in patients of group A (P-value <0.05). The total postoperative patients' requirements for antiemetic drugs within the 2 hours after extubating decreased in patients of group A more than group B (P-value <0.05). The postoperative duration from the end of surgery to extubating decreased significantly in patients of group A more than group B (P-value <0.05). The total urine output during the duration from drug administration to extubating of patients increased in patients of group A more than group B (P-value <0.05)
23	2011	Singh et al <sup>23</sup>	India	Supratentorial (116)	Group I: Nitrous oxide - Isoflurane anaesthesia (Nitrous oxide-based group)  Group II - Isoflurane anaesthesia (Nitrous oxide-free group).	avoidance of nitrous oxide in one's practice may not affect the outcome in the neurosurgical patients median duration of ICU stay in the nitrous group and the nitrous-free group was 1 (1 - 11 days) day and 1 (1 - 3 days) day respectively (P = 0.67), whereas the mean duration of hospital stay in the nitrous group was 4 (2 - 16) days and the nitrous free group was 3 (2 - 9) days (P = 0.06). The postoperative complications in the two groups were comparable.
24	2001	Korula et al <sup>24</sup>	India	Pituitary macroadenomas (57)	Study group 29 – controlled hypercapnia, raising end-tidal carbon dioxide levels to a maximum of 50 mm Hg by hypoventilation Control 28 - intrathecal saline	Twenty-seven of 29 patients in the study group and 25 of 28 patients in the control group reached the target pressure of 20 mm Hg Both techniques were equally effective in raising intracranial pressure and in providing descent of the suprasellar component of the tumour. No untoward side effects occurred while using either technique. The authors conclude that controlled hypercapnia is effective in producing descent of the suprasellar portion of a pituitary adenoma.
25	2023	Sarhan et al <sup>25</sup>	Egypt	Posterior fossa tumours (42)	Early hyperventilation group: 23 Early norm ventilation group: 19	Moderate hyperventilation reduced cerebral oxygenation without significant improvement of the surgical brain relaxation or the ICP
26	2009	Ali et al <sup>26</sup>	India	transsphenoidal resection of pituitary tumours (90)	randomly divided to receive propofol, isoflurane, or sevoflurane for maintenance of anaesthesia	After tracheal intubation, the rise in blood pressure was more in sevoflurane group than propofol Emergence and extubating times were significantly shorter with propofol and sevoflurane. Patients who received propofol had better cognition scores. Aldrete scores were better with propofol and sevoflurane than isoflurane. The pressor response after intubation and

Continued on next page...

Continued from previous page...

						emergence hypertension was significantly less with propofol. Better recovery profile was seen in sevoflurane and propofol groups and a better cognition in patients receiving propofol. Propofol plus nitrous oxide anaesthesia could be the technique of choice in patients undergoing trans nasal transsphenoidal pituitary surgery.
27	2019	Bhagat et al <sup>27</sup>	India	Intracranial tumours (90)	randomized to receive NS, RL, or a combination of NS and RL	use of NS was associated with hyperchloraemic metabolic acidosis and ionic hypocalcaemia. RL caused significant hyponatremia and increase in serum lactate levels. The combination of NS and RL has least influence on biochemical and metabolic parameters. The effects of three fluids were similar on the hemodynamic, brain relaxation score, as well as on postoperative complications and the duration of postoperative hospital stay.
28	2015	Gopalakrishna et al <sup>28</sup>	India	TNTS for pituitary tumour (46)	continuous infusion of DEX (group D) or 0.9% saline (group C)	Total fentanyl consumption during the study period was significantly lower in group D compared with group C. End-tidal isoflurane concentration requirement was found to be significantly reduced in group D compared with group C throughout the surgical period. Fentanyl and end-tidal isoflurane concentration requirement was reduced in group D compared with group C by 40% and 33.3%, respectively. Heart rate and mean arterial pressure were significantly higher in the group C compared with group D after intubation, during various stages of surgery and immediately after extubating. The group D had excellent surgical conditions and lesser bleeding in comparison to group C. Emergence time and extubating time were significantly shorter in group D compared with group C. Conclusions: DEX as an aesthetic adjuvant improved hemodynamic stability and decreased anaesthetic requirements in patients undergoing TNTS resection of pituitary tumour. In addition, DEX provided better surgical field exposure conditions and early recovery from anaesthesia.
29	2014	Bodaghabadi et al <sup>29</sup>	Iran	Recurrent Cushing Disease (52)	Group 1: 26, transsphenoidal micro adenoidectomy Group 2: 26, Gamma Knife radiosurgery	No significant relationship was found between preoperative 24-hour free urine cortisol and disease-free months or tumour volume among both groups. Our statistical analysis showed higher recurrence-free interval in the GKRS group compared with TSA group. With longer recurrence-free interval, GKRS could be considered a good treatment alternative to repeated TSA in recurrent CD.

Continued on next page...

## Continued from previous page...

30	2012	Daif et al <sup>30</sup>	Egypt	Brain tumours (40)	2 groups (haemodilution and control). In the haemodilution group (HG), 1000 mL of blood was drawn and replaced with the same volume of HES 130/0.4 (6%, Voluven) colloid. control group (CG), no blood was drawn, and hemodynamic were stabilized using normal saline until allogenic blood was needed	ANH and allogenic blood transfusion used in this study design were accompanied by comparable cerebral oxygenation parameters in patients subjected to brain tumour resection
31	2000	Shaheen et al <sup>31</sup>	India	Supratentorial (20)	Group 1 (10): alcuronium Group 2 (10): pipecuronium	The rise in intracranial pressure at intubation was significantly greater in group I (21.10+/-3.97 torr, 122.59%) when compared to group II patients (1.80+/-0.70 torr, 10.04%) (p<0.01). Cardiovascular parameters also showed a significantly greater degree of rise in group I when compared to group II patients. Heart rate increased by 29+/-6.32 beats min <sup>-1</sup> (33.52%) and systolic arterial pressure by 11.60+/-7.37 torr (9.47%) in group I. These parameters did not change significantly in group II.
32	2009	Jain et al <sup>32</sup>	India	Supratentorial (90)	3 groups to receive either placebo (saline), ondansetron 4 mg, or granisetron 1 mg intravenously at the time of dural closure	incidence of vomiting in 24 hours, severe emetic episodes, and requirement of rescue antiemetics were less in ondansetron and granisetron groups as compared with placebo (P<0.001). Both the study drugs had comparable effect on vomiting. However, the incidence of nausea was comparable in all 3 groups (P=0.46) ondansetron 4 mg and granisetron 1 mg are comparably effective at preventing emesis after supratentorial craniotomy. However, neither drugs prevented nausea effectively.
33	2007	Jain et al <sup>33</sup>	India	Pituitary adenomas (20)	Ten cases were operated by endoscopic endonasal trans-sphenoidal approach by endoscopic rhinologist (EETSS group) and other 10 cases were excised by microsurgical endonasal trans-sphenoidal approach by a neurosurgeon (SMETSS group)	Endoscopic approach provides a wide surgical field and broad lateral vision making easier distinction of tumour tissue: gland and gland diaphragm interface. Thus, there is less blood loss and nasoseptal complications, whereas there was no statistically significant difference in operative time and complete tumour removal
34	2018	Dey et al <sup>34</sup>	India	Supratentorial tumour (44)	two groups of 22 each to receive either normal saline or BC (Plasmalyte) as the maintenance fluid, intra-operatively	balanced crystalloid maintains metabolic status more favourably than normal saline in neurosurgical patients. Hyperchloremic metabolic acidosis, and the other problems which occur as a consequence of normal saline infusion may be circumvented by choosing a balanced crystalloid electrolyte solution. Neither of the crystalloids appeared to have any adverse effect on brain relaxation.

**Table-2:** Chemotherapy (n = 12).

No.	Year	Author	Country	Type of Tumour (n)	Treatment Arms	Outcomes Assessed/Conclusion
1.	2020	Khoury et al <sup>35</sup>	Lebanon	Metastasis (117)	Group 1 (84): Dexamethasone doses of 1144 mg/m <sup>2</sup> Group 2 (33): (Dexamethasone doses of 618 mg/m <sup>2</sup> )	Decreasing cumulative dose of dexamethasone for low-risk childhood acute lymphoblastic leukemia patients aiming to avoid serious viral infections led to a significant increase in isolated central nervous system relapse
2.	2013	Gaber et al <sup>36</sup>	Egypt	Glioblastoma Multiforme (60)	Group 1 (30): Temozolomide at a dose of 75 mg/m <sup>2</sup> daily with radiotherapy for 42 days starting 4 weeks after surgery and reaching to a total radiation dose of 60 Gy/30 Fractions/6 weeks Group 2 (30): Temozolomide at a dose of 75 mg/m <sup>2</sup> concomitantly with the same radiotherapy schedule daily in the first and last weeks of the same radiotherapy program	Reduced radiosensitizer dosing of temozolomide concomitant with radiotherapy in glioblastoma multiforme exhibited comparable efficacy with a classic continuous daily schedule, though with better tolerability
3.	2021	Gupta et al <sup>37</sup>	India	High-risk/metastatic medulloblastoma; residual tumour >1.5 cm <sup>2</sup> or leptomeningeal metastases (97)	Newly diagnosed patients received concurrent carboplatin (35 mg/m <sup>2</sup> ) for 15 days (day 1 to day 15) during craniospinal irradiation plus posterior fossa/tumour bed boost, followed by six cycles of standard adjuvant chemotherapy	On univariate analysis, leptomeningeal metastases and histological subtype emerged as significant prognostic factors for survival. Addition of concurrent carboplatin to RT as radio sensitizing chemotherapy is a simple and effective way of treatment intensification in high-risk/metastatic medulloblastoma.
4.	2017	Mousa et al <sup>38</sup>	Egypt	CNS tumours (80)	Intervention group received 5 g of <i>Nigella sativa</i> seeds (NS) daily throughout treatment while controls received nothing.	NS seeds showed a decrease in incidence of febrile neutropenia in children with brain tumours with shortening of subsequent length which may improve their outcome and thereby quality of life.
5.	2021	Koundal et al <sup>39</sup>	India	Sellar and suprasellar (50)	Patients in the intervention group received a nurse-led DI bundle (validated by three Delphi rounds) with four dietary components: intake of only water during thirst and avoidance of the following— added salt, high-protein foods and caffeinated drinks. Treating clinicians and the investigator assessing outcome were blinded about enrolment. Urine output, serum sodium, vasopressin requirement and hospital stay were assessed as primary outcomes. The outcome measures were monitored daily till the 6th postoperative day.	mean daily urine output was significantly lower in the DI bundle group than in control, both overall and among endonasal operated pituitary adenomas [3000.09(462.7) vs. 4095.71(896.4) ml & 2987.14(419.5) vs. 4064.73(1051) ml], with the greatest difference on the second postoperative day. Though hyponatremia in controls became most prominent during days 2–3 and resolved in a week, it was significantly lower in the intervention group (12.7% vs. 30.7%) overall, 11.4% vs. 29.4% endonasal adenomas). The need for vasopressin analogues and hospital stay were also significantly lower with DI bundle (p < 0.001).

Continued on next page...

## Continued from previous page...

6.	2020	Melika et al <sup>40</sup>	Iran	benign brain tumours (60)	The study group (n 1/4 30) received intramuscular injection of 300,000 IU vitamin D3 prior to surgery. The control group (n 1/4 30) was left without intervention, and both groups underwent routine therapies	On day 5 after craniotomy, the serum 25(OH)D levels increased significantly in the study group (P1/4 <0.001). The length of ICU and hospital stay was significantly lower in the study group compared to the control group (P 1/4 0.01 and P 1/4 0.008, respectively). It was true when the age, tumour size, tumour type, Karnofsky Performance Scale (KPS) score, and calcium and albumin levels at baseline entered the logistic regression model (OR 1/4 0.17 (95%CI 1/4 0.04e0.72, P 1/4 0.01), and OR 1/4 0.19 (95%CI 1/4 0.04e0.82, P 1/4 0.02), respectively). With and without the application of logistic regression analysis, there was no significant difference in perioperative complications.
7.	2022	Thakur et al <sup>41</sup>	India	Newly Diagnosed Glioblastoma (71)	Short-course radiotherapy (25 Gy in 5 fractions) has been shown to be non-inferior to standard course radiotherapy in elderly and frail patients (60 Gy in 30 fractions). The purpose of this study was to determine the effects of temozolomide combined with short-course radiotherapy on the outcome of elderly and frail patients.	In terms of overall survival and progression-free survival, radiotherapy with concurrent temozolomide and adjuvant temozolomide outperformed short-course radiotherapy alone. The median overall survival in arm 1 was 146 days and 121 days in arm 2 (P=0.146). The median progression-free survival in arm 1 was 109.50 days, while it was 77 days in arm 2 (P=0.028). With a median follow-up time of 6 months, the quality of life at 4 weeks and 12 weeks after treatment was not different between the two arms. Adding temozolomide to short-course radiotherapy significantly improved progression-free survival and showed an increasing trend in overall survival without compromising the quality of life.
8.	2022	Patil et al <sup>42</sup>	India	Recurrent GBM not eligible for re-irradiation (88)	CCNU-MBZ (CCNU was administered at 110 mg/m <sup>2</sup> every 6 weeks with MBZ 800 mg thrice daily): 44 TMZ-MBZ (MZ was administered at 200 mg/m <sup>2</sup> once daily on days 1-5 of a 28 days cycle with MBZ 1600 mg thrice daily): 44	The 9-month OS was 36.6% (95% CI 22.3-51.0) and 45% (95% CI 29.6-59.2) in the TMZ-MBZ and CCNU-MBZ arms respectively, in the ITT population. ECOG PS was the only independent prognostic factor impacting OS (HR-0.48, 95% CI 0.27-0.85; P = 0.012). The addition of MBZ to TMZ or CCNU failed to achieve the pre-set benchmark of 55% 9-month OS.
9.	2003	Rajaratnam et al <sup>43</sup>	India	Pituitary macroadenoma (114) underwent transsphenoidal surgery	Thirty-two patients were allotted to Group 1 (conventional dose hydrocortisone protocol), 30 to Group 2 (intermediate dose hydrocortisone protocol) and 52 to Group 3 (low dose hydrocortisone protocol)	The incidence of DI with the conventional dose was 52%, intermediate dose, 36% and low dose, 24% (p = 0.025). The low dose hydrocortisone protocol reduced the incidence of DI by 46% when compared with the conventional dose hydrocortisone protocol
10.	2015	Hosseini et al <sup>44</sup>	Iran	Brain metastasis (20)	In the first group, patients were treated with WBRT alone (control arm), and in the second group (intervention arm), patients received WBRT with concomitant sodium nitrite.	intravenous infusion of sodium nitrite with this dose and schedule to patients with brain metastases concurrent with radiotherapy did not show any major benefit in terms of radiologic response.

Continued on next page...

Continued from previous page...

11.	2005	Abd El-All et al <sup>45</sup>	Egypt	Paediatric high-risk medulloblastoma (48)	First (group I) included 21 patients who received postoperative craniospinal radiation therapy (36Gy+boost 20Gy to the posterior fossa). The second (group II) included 27 cases who received postoperative combination craniospinal radiation therapy (with the same dose as the first group) and chemotherapy (vincristine, etoposide, cisplatin).	In-group I, complete remission (CR) was achieved in 71.4% of the cases; partial remission (PR) in 14.3% of the patients; stationary disease (SD) in 14.3% and none of the cases suffered from progressive disease. The three-year OS was 69.5% and the three-year DFS was 61.3%. In-group II, CR was achieved in 59.3% of the cases; PR in 3.7%; SD in 3.7% and PD in 37.3% of the cases. The three-year OS was 48.4% and the 3-year DFS was 48.9%. In group I; 13 patients (62%) suffered a reduction of 8-20% in IQ in comparison to their normal siblings, whereas in Group II; 13 patients (48%) developed a reduction in IQ ranging from 12-21%. poorer outcome in the chemo-radiation group was due to the treatment interruption during radiation therapy caused by myelosuppression since the incidence of myelosuppression was higher in the chemo-radiation group and the recovery time was longer
12.	2016	El-Hamamsy et al <sup>46</sup>	2016	Brain metastases (50)	30-Gy WBRT (control group: 25 patients) or 30 Gy WBRT + simvastatin 80 mg/day for the WBRT period (simvastatin group: 25 patients)	addition of simvastatin was tolerated. Response rates were 60% and 78.6% (p = 0.427), 1-year PFS rates were 5.2% and 17.7% (p = 0.392), and 1-year OS rates were 12% and 8% (p = 0.880) for the control group and simvastatin group, respectively. Nonsignificant differences were found between the two arms regarding HRQL scales. The addition of simvastatin 80 mg/day did not improve the clinical outcomes of patients with BM receiving WBRT.

**Table-3:** Radiation Therapy (n = 11)

No.	Year	Author	Country	Type of Tumour (n)	Treatment Arms	Outcomes Assessed/Conclusion
1.	2014	Pashaki et al <sup>47</sup>	Iran	Glioblastoma Multiforme (68)	GBM, treated with resection, and given postoperative radiotherapy followed by concurrent and/or adjuvant chemotherapy	Higher radiation doses of (>60Gy) can improve local control and potentially survival
2.	2009	Asghar et al <sup>48</sup>	Pakistan	Brain Metastasis (30)	Whole brain radiotherapy with 20 Gy was given in five consecutive daily fractions. All were followed up for six months for survival.	Significant effect of treatment with 20 Gy radiotherapy as 76% of the patients during and 80% on the last day of therapy showed >50% response (p<0.05). Median survival of the patients after radiotherapy was two months (p<0.05). No serious toxicity was noted during this therapy.
3.	2013	Goda et al <sup>49</sup>	India	Children with diffuse intrinsic pontine gliomas(20)	Impact of multiparametric MRI and 18 F-FDG-PET on the outcomes	Cumulative RPI was able to classify the patients into different grades and was predictive of overall survival (p = 0.02). MR perfusion also predicted survival (p = 0.039). Sensitivity and specificity of MRI and FDG-PET to detect low-grade gliomas were low to moderate (33–66%), but moderate to high in detecting high-grade

Continued on next page...



Continued from previous page...

4.	2022	Zaghloul et al <sup>50</sup>	Egypt	Paediatric diffuse intrinsic pontine glioma (253)	3 arms of radiation therapy regimens: HF1, receiving 39 Gy in 13 fractions; HF2, receiving 45 Gy in 15 fractions; and conventional fractionation (CF), receiving 54 Gy in 30 fractions.	gliomas (50–100%). Baseline FDG uptake on PET scan did not correlate with survival (p = 0.7).  The median overall survival for the HF1, HF2, and CF were 9.6, 8.2, and 8.7 months, respectively. Younger patients (2–5 years of age) had better median OS in the whole cohort (11.6 months), HF1 (13.5), and CF (12.1) but not HF2 (6.2) (P = .003). Furthermore, the OS rates at 1, 1.5, and 2 years for children 2 to 5 years of age in the HF2 arm were lower than those in the HF1 and CF arms. Two hypo fractionated radiation therapy proved to be noninferior to conventional fractionation. The young age superiority was lost with a higher hypo fractionated radiation therapy dose, necessitating more caution in applying 45 Gy in 15 fractions in younger children (2–5 years of age).
5.	2017	Jalali et al <sup>51</sup>	India	Benign and Low-Grade Brain Tumours (200)	High-precision SCRT: 100 ConvRT to a dose of 54 Gy in 30 fractions over 6 weeks: 100	In young patients with residual and/or progressive benign or low-grade brain tumours requiring radiotherapy for long-term tumour control, SCRT compared with ConvRT achieves superior neurocognitive and neuroendocrine functional outcomes over 5 years without compromising survival.
6.	2011	Santra et al <sup>52</sup>	India	GBM (90)	Histopathologically proven glioma who had suspicion of recurrence clinically or imaging were evaluated using Tc-99m GHA SPECT and FDG PET/CT. 59 patients were positive and 31 were negative for tumour recurrence.	On subgroup analysis, GHA SPECT performed better than FDG PET/CT in all grades except for grade II gliomas, where both were equally effective. In all, 15 patients had intramodality discordance, with GHA SPECT being correct in 13 of them. GHA SPECT appears to be a better imaging modality than FDG PET/CT for detection of recurrent gliomas.
7.	2018	Mallick et al <sup>53</sup>	India	GBM (89)	Hypo fractionated accelerated radiotherapy (HART): 60 Gy in 20 fractions over 4 weeks @ 3 Gy/per fraction to high-risk planning target volume (PTV) and 50 Gy in 20 fractions over 4 weeks @ 2.5 Gy/per fraction to low-risk PTV conventional fractionated radiotherapy (CRT): 60 Gy in 30 fractions over 6 weeks @ 2 Gy/per fraction	Median OS in the CRT and HART arms were 18.07 months (95% CI 14.52–NR) and 25.18 months (95% CI 12.89–NR) respectively, p = 0.3. HART is comparable to CRT in terms of survival outcome. HART arm had no excess treatment interruption and minimal toxicity. Dose escalation, reduction in overall treatment time, is the advantages with use of HART
8.	2010	Kalaghchi et al <sup>54</sup>	Iran	CNS Tumours (4)	two groups (20 patients each), the first receiving GCSF prevention therapy before weekly craniospinal radiotherapy and the control group without this prophylaxis.	No significant differences in platelets and WBC loss between the treatment and control groups. Treatment interruption was lower in weekly GCSF therapy group (35%), compared to the control group (55%), although the difference was not statistically significant (P value 0.2). Weekly GCSF injections among CNS tumour patients receiving craniospinal therapy may decrease treatment interruption.

Continued on next page...

Continued from previous page...

9.	2020	Izzuddeen et al <sup>55</sup>	India	DIPG (33)	Patients in arm A received conventional fractionated RT of 60 Gy in 30 fractions over 6 weeks while patients in arm B received hypo-fractionated radiotherapy of 39 Gy in 13 fractions over 2.6 weeks along with concurrent Temozolomide (TMZ) 75 mg/m <sup>2</sup> from day 1 to day 17 followed by adjuvant TMZ for six cycles.	93% (n = 14) of patients in the conventional arm completed treatment while only 17% (n = 3) of the children could complete planned course of treatment in the experimental arm. The median overall survival (OS) was 11 months (95% CI - 7.5 to 14.5 months) in the conventional arm and 12 months (95% CI - 10.5 to 13.5 months) in the experimental arm (p = 0.208). 28% (n = 5) patients in the experimental arm developed grade 3 or 4 haematological toxicity. Conclusion: The above study shows that hypo fractionated radiotherapy with concurrent and adjuvant temozolomide does not improve OS and has higher haematological toxicity. Conventional radiotherapy remains the standard of care.
10.	2014	Gantery et al <sup>56</sup>	Egypt	Brain metastases (1-3) (60)	21 patients received WBRT + SRS, 18 patients received SRS alone and 21 patients received WBRT alone	Median local control was significantly better for WBRT + SRS compared to SRS alone & WBRT alone (10 vs 6 vs 5 months, respectively, P = 0.04). There was non-significant survival benefit for WBRT + SRS compared to SRS alone & WBRT alone. Survival was significantly better for patients with controlled primary tumour who received WBRT + SRS compared to SRS alone & WBRT alone (median survival was 12 vs 5.5 vs 8 months, respectively. P = 0.027)
11.	2003	Sharma et al <sup>57</sup>	India	High grade gliomas and glioblastoma multiforme who underwent surgery partial, sub-total or near-total excision as the primary treatment (50)	Study Group A: Localized field external radiotherapy 50 Gy/25#/5 wks followed by Boost 10 Gy/5#/1 wk, Control Group B: Whole brain external radiotherapy 40 Gy/20#/4 wks followed by Boost 20 Gy/10#/2 wks by localized field.	No significant difference in the local response was seen between the two groups after radiotherapy. Six months progression-free survival of the study group was 44% as compared to 26% in the control group. Six months overall survival was 66.67% in the study group and 50.72% in the control group (P<0.01). Maximum recurrences were noticed within 2 cm of the original tumour margin in both the groups. Although local control and survival of the patient in both the groups were same, performance status definitely improved in patients treated with localized field irradiation only.

**Table-4:** Miscellaneous (n = 4).

No.	Year	Author	Country	Type of Tumour (n)	Treatment Arms	Outcomes Assessed/Conclusion
1.	2019	Thakur et al. <sup>58</sup>	India	Intracranial tumors (80)	Nurse-led intervention was provided in the form of individual counselling, and a pamphlet was given to patients and caregivers in the experimental group at the time of discharge	Patients in the experimental group had significantly fewer behavioural symptoms and less severity of behavioural symptoms as compared to the control group. Caregivers in the experimental group had significantly less severity of distress as compared to the control group.
2.	2018	Patil et al <sup>59</sup>	India	Adult glioma (II-IV)(65)	Compared video follow-up and conventional clinical follow-up	Concurrence in decision of administering TMZ between VF and CF was 100% (p<0.00). Median cost incurred in VF was US\$58.15 while that incurred in CF was

Continued on next page...

Continued from previous page...

US\$131.23 (p<0.00)VF can substitute CF during adjuvant TMZ administration

3.	2015	Mirrahimi et al <sup>60</sup>	Iran	Supratentorial (60)	treatment group (30), 5 g of MgSO4 in normal saline was infused in 6 h 2 days before surgery, and the same dosage was repeated the day before and during surgery. The control group (30) received placebo	Significant change in S100B protein levels before and after surgery (p < 0.05), but we could not find similar results for NSE protein and the Barthel index score
4.	2010	Puri et al <sup>61</sup>	India	High-grade glioma (50)(GBM 32/50)	surgery followed by adjuvant radiotherapy and concomitant paclitaxeloral lycopene (Group A) 8 mg daily with radiotherapy or placebo (Group B)	Magnetic resonance imaging (MRI) of brain and Single Photon Emission Computed Tomography (SPECT) were done three-monthly for two visits and six-monthly thereafter. Primary endpoint was response at six months post radiotherapy.Pre- and post-treatment plasma lycopene levels in the patients in Gropu A were 152 ng/ml and 316 ng/ml and in the patients in Group B were 93 ng/ml and 98 ng/ml (P = 0.009). There was non-significant differences in favour of lycopene between Group A and Group B with higher overall response at six months (P = 0.100), response at last follow-up (P = 0.171) and time to progression (40.83 vs. 26.74 weeks, P = 0.089)

optimized steroids for CNS involvement in childhood ALL to reduce viral infections. Similarly, short course radiotherapy with Temozolomide was found to improve survival without compromising QoL in newly diagnosed

GBM in frail/elderly patients. Radiation oncology literature was also limited from LMICs (11 papers), with only two recent papers discussing DIPG treatment with conventional fractionated RT vs. hypo fractionated RT.

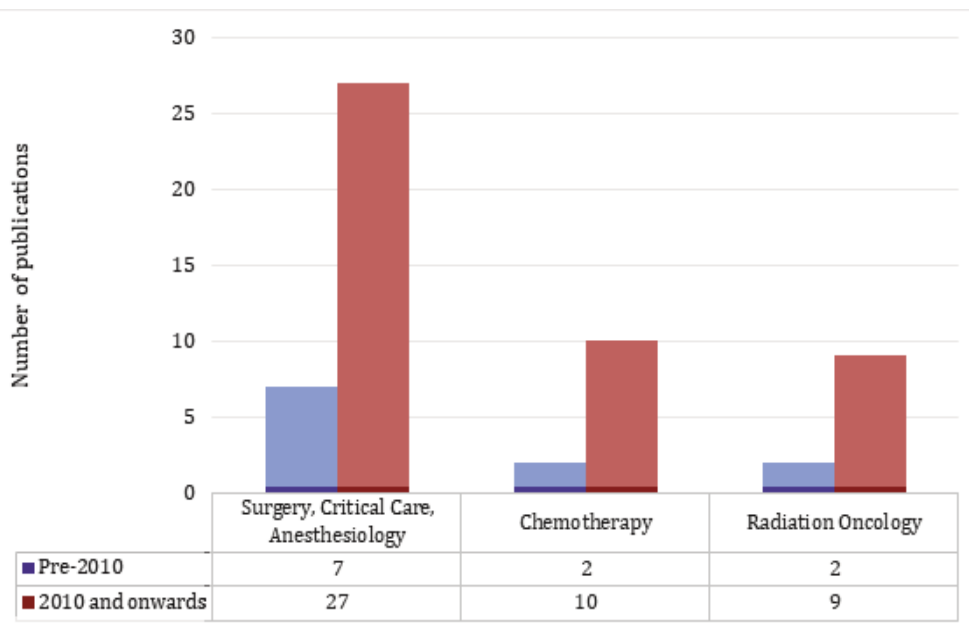


Figure-2: Comparison of clinical trials published before and after 2010 according to categories.

### Further avenues for clinical trial development

A subjective assessment of current trends in neuro-oncological clinical trials from LMICs shows great promise in terms of repurposing previous drugs for chemotherapy and radiosensitisation<sup>62</sup>, developing new protocols for reducing chemo- and radiation-related toxicities in childhood brain tumours, and novel, low-cost interventions in surgical neuro-oncology. With the advent of new immune-checkpoint inhibitors and CAR T cell therapy, it may be

difficult to determine financial viability of these options in LMIC health economies, considering many patients pay out-of-pocket for treatment and supply-chain demands may affect availability. A recent phase 1 study repurposing mebendazole, a common anti-helminthic drug, for recurrent high-grade glioma was able to determine tolerable dosing in concurrence with adjuvant concurrent chemo and radiotherapy (CCRT); such studies are practicable approaches towards conducting effective trial research in LMICs considering cost demands.

Much work has been published by the SIOP PODC (International Society of Paediatric Oncology (SIOP) committee named Paediatric Oncology in Developing Countries) regarding chemotherapy and radiation regimen recommendations for LMICs in paediatric brain tumours, based on local evidence, experts working within LMICs, and availability of medications.<sup>63</sup> These guidelines have been effective in developing standards of care for these pathologies in resource-limited settings; clinical trials assessing response and treating recurrent tumours with the available resource are needed. Low-cost interventions in neuro-oncological surgery, such as ultra-low-field portable MRI for assessing tumour resection rates, are other possible avenues of trial research.<sup>64</sup>

### Developing trials and infrastructure in LMICs

The evidence presented supports the need for greater buy-in from LMIC institutions towards building clinical trial research centres and collaborations, both local and regional, to help generate more well-founded science in the practice of neuro-oncology. The benefits from the perspective of LMIC stakeholders is developing real-world evidence for interventions that are locally sourced, well founded in populations of interest, and lead to LMIC researchers contributing significantly to global scientific efforts. This in turn incentivizes greater collaboration with other centres of excellence across the world – HIC researchers would benefit through understanding clinical trial research in populations distinct from their own, allowing for greater insights into treatment response and tumour behaviour, and help expand the potential pool of participants for ethical trials.

Clinical trial development in LMICs is currently ongoing – in an overview of recent oncology RCTs globally, it was reported that only 8% of oncology trials were lead by either upper-middle income countries (UMICs) or LMICs.<sup>65</sup> Despite greater inclusion of LMIC populations in HIC-led RCTs, LMIC research output does not reflect strong evidence of locally developed trials or infrastructure, as evidenced in further investigations.<sup>66</sup> Resource and logistics-related barriers to clinical trials in LMICs are well-

documented<sup>67</sup>; however, academic and industrial partnerships, in line with ethical and local governance standards, can help support clinical cancer care systems and conduct novel, effective clinical trial research. Within neuro-oncology trial research especially, prioritizing cooperative trials can help improve research output from LMICs.

### Conclusion

The presented review of LMIC-led clinical trials in neuro-oncology identifies trends in research and insights into new pathways for developing research. The current literature shows steady improvement in research output, with diversification and investigation into specific tumours, improving chemo- and radiation therapy regimens for specific populations, and investigating resource-efficient measures. Overall, there is a dire need for greater participation and collaboration in improving trial research output from these underserved populations.

### Appendix 1:

#### Search strategy:

((randomized clinical trial) OR (RCT)) AND ((neuro-oncology) OR (neuro oncology) OR (Brain tumour) OR (CNS tumour) OR (Central nervous system tumours) OR (Glioma) OR (Astrocytoma) OR (Oligodendroglioma) OR (GBM) OR (Glioblastoma) OR (Glioblastoma multiforme) OR (Glial tumour) OR (Medulloblastoma) OR (Ependymoma) OR (Pinealoma) OR (Craniopharyngioma) OR (Brain Metastasis)) AND ((LMIC) OR (Low income country) OR (Middle income country) OR (Low to middle income country) OR (Low-to-middle-income country) OR (Afghanistan) OR (Burkina Faso) OR (Burundi) OR (Central African Republic) OR (Chad) OR (Congo, Dem. Rep) OR (Eritrea) OR (Ethiopia) OR (The Gambia) OR (Guinea) OR (Guinea-Bissau) OR (Korea, Dem. People's Rep) OR (Liberia) OR (Madagascar) OR (Malawi) OR (Mali) OR (Mozambique) OR (Niger) OR (Rwanda) OR (Sierra Leone) OR (Somalia) OR (South Sudan) OR (Sudan) OR (Syrian Arab Republic) OR (Togo) OR (Uganda) OR (Yemen) OR (Rep. Zambia) OR (Angola) OR (India) OR (Philippines) OR (Algeria) OR (Indonesia) OR (Samoa) OR (Bangladesh) OR (Iran) OR (São Tomé and Príncipe) OR (Benin) OR (Kenya) OR (Senegal) OR (Bhutan) OR (Kiribati) OR (Solomon Islands) OR (Bolivia) OR (Kyrgyz Republic) OR (Sri Lanka) OR (Cabo Verde) OR (Lao PDR) OR (Tanzania) OR (Cambodia) OR (Lebanon) OR (Tajikistan) OR (Cameroon) OR (Lesotho) OR (Timor-Leste) OR (Comoros) OR (Mauritania) OR (Tunisia) OR (Congo) OR (Micronesia) OR (Fed. Sts) OR (Ukraine) OR (Côte d'Ivoire) OR (Mongolia) OR (Uzbekistan) OR (Djibouti) OR (Morocco) OR (Vanuatu) OR (Egypt) OR (Myanmar) OR (Vietnam) OR (El Salvador) OR (Nepal) OR (West Bank and Gaza) OR (Eswatini) OR

(Nicaragua) OR (Zimbabwe) OR (Ghana) OR (Nigeria) OR (Haiti) OR (Pakistan) OR (Honduras) OR (Papua New Guinea).

**Disclaimer:** None.

**Conflict of Interest:** None.

**Funding Disclosure:** None.

## References

- Hooda B, Chouhan RS, Rath GP, Bithal PK, Suri A, Lamsal R. Effect of tranexamic acid on intraoperative blood loss and transfusion requirements in patients undergoing excision of intracranial meningioma. *J Clin Neurosci* 2017;41:132-8. doi: 10.1016/j.jocn.2017.02.053.
- Bansal S, Ramesh VJ, Umamaheswara Rao GS. Fentanyl co-administration decreases the induction dose requirement of propofol in patients with supratentorial tumors and not in patients with spinal lesions. *J Neurosurg Anesthesiol* 2012;24:345-9. doi: 10.1097/ANA.0b013e318262282f.
- Barik AK, Agrawal S, Gupta P, Kumari R. Evaluation of equiosmolar 20% mannitol, 3% hypertonic saline and 8.4% sodium bicarbonate on intraoperative brain relaxation and hemodynamic parameters in patients undergoing craniotomy for supratentorial tumors: a prospective randomized study. *Minerva Anesthesiol* 2021;87:997-1000. doi: 10.23736/S0375-9393.21.15448-3.
- Bhagat H, Dash HH, Bithal PK, Chouhan RS, Pandia MP. Planning for early emergence in neurosurgical patients: a randomized prospective trial of low-dose anesthetics. *Anesth Analg* 2008;107:1348-55. doi: 10.1213/ane.0b013e31817f9476.
- Chandra S, Pryambodho P, Omega A. Evaluation of continuous intravenous lidocaine on brain relaxation, intraoperative opioid consumption, and surgeon's satisfaction in adult patients undergoing craniotomy tumor surgery: A randomized controlled trial. *Medicine (Baltimore)* 2022;101:e30216. doi: 10.1097/MD.00000000000030227.
- Gupta DK, Chandra PS, Ojha BK, Sharma BS, Mahapatra AK, Mehta VS. Awake craniotomy versus surgery under general anesthesia for resection of intrinsic lesions of eloquent cortex—a prospective randomised study. *Clin Neurol Neurosurg* 2007;109:335-43. doi: 10.1016/j.clineuro.2007.01.008.
- Ghoneim AA, Azer MS, Ghobrial HZ, El Beltagy MA. Awakening properties of isoflurane, sevoflurane, and desflurane in pediatric patients after craniotomy for supratentorial tumours. *J Neurosurg Anesthesiol* 2015;27:1-6. doi: 10.1097/ANA.0000000000000058.
- Hegazy A, Al-Shami H, Ali MFA, Fathallah M, Salah A, Mohamed H, et al. Mobilization of the outer cavernous membrane decreases bleeding and improves resection in sphenoid-clinoidal meningiomas without cavernous sinus extension: A randomized controlled trial. *Neurol India* 2018;66:407-15. doi: 10.4103/0028-3886.227306.
- Jonathan GE, Sarkar S, Singh G, Mani S, Thomas R, Chacko AG. A randomized controlled trial to determine the role of intraoperative lumbar cerebrospinal fluid drainage in patients undergoing endoscopic transsphenoidal surgery for pituitary adenomas. *Neurol India* 2018;66:133-8. doi: 10.4103/0028-3886.222823.
- El Beltagy MA, Atteya MM. The benefits of navigated intraoperative ultrasonography during resection of fourth ventricular tumors in children. *Childs Nerv Syst* 2013;29:1079-88. doi: 10.1007/s00381-013-2103-y.
- Abdelhaleem NF, Youssef EM. Effect of sphenopalatine ganglion block on intracranial pressure and cerebral venous outflow oxygenation during craniotomy for supratentorial brain tumours. *Anaesth Crit Care Pain Med* 2022;41:101013. doi: 10.1016/j.accpm.2021.101013.
- Paul AP, Vedantam A, Korula G, Chacko AG. A comparison of the recovery profiles of desflurane and isoflurane anesthesia in patients undergoing elective supratentorial craniotomy: A randomized controlled trial. *Neurol India* 2017;65:1053-8. doi: 10.4103/neuroindia.NI\_1136\_15.
- Rajkiran R, Soni SL, Jangra K, Bhagat H, Singh A, Singh A, et al. Diclofenac Is Superior to Paracetamol in Postoperative Pain Scores and Analgesic Consumption in Supratentorial Craniotomy With No Difference in Platelet and Clot Function: A Prospective Randomized Controlled Trial. *J Neurosurg Anesthesiol* 2022;34:321-6. doi: 10.1097/ANA.0000000000000765.
- Mishra N, Rath GP, Bithal PK, Chaturvedi A, Chandra PS, Borkar SA. Effect of Goal-Directed Intraoperative Fluid Therapy on Duration of Hospital Stay and Postoperative Complications in Patients Undergoing Excision of Large Supratentorial Tumors. *Neurol India* 2022;70:108-14. doi: 10.4103/0028-3886.336329.
- Konay AS, Williams A, Chacko AG, Singh G. A Prospective Randomized Trial Comparing Topical Intranasal Lidocaine and Levobupivacaine in Patients Undergoing Endoscopic Binostril Transnasal Transsphenoidal Resection of Pituitary Tumors. *J Neurosurg Anesthesiol* 2021;33:51-7. doi: 10.1097/ANA.0000000000000619.
- Sriganesh K, Syeda S, Shanthanna H, Venkataramaiah S, Palaniswamy SR. Effect of Opioid Versus Non-Opioid Analgesia on Surgical Pleth Index and Biomarkers of Surgical Stress During Neurosurgery for Brain Tumors: Preliminary Findings. *Neurol India* 2020;68:1101-5. doi: 10.4103/0028-3886.294559.
- Singla A, Mathew PJ, Jangra K, Gupta SK, Soni SL. A Comparison of Hypertonic Saline and Mannitol on Intraoperative Brain Relaxation in Patients with Raised Intracranial Pressure during Supratentorial Tumors Resection: A Randomized Control Trial. *Neurol India* 2020;68:141-5. doi: 10.4103/0028-3886.279671.
- Sriganesh K, Syeda S, Shanthanna H, Venkataramaiah S, Palaniswamy SR. Comparison of intraoperative fentanyl with dexmedetomidine for perioperative analgesia and opioid consumption during craniotomies: A randomised controlled pilot study with non-inferiority design. *Int J Clin Pract* 2019;73:e13338. doi: 10.1111/ijcp.13338.
- Tandon V, Raheja A, Suri A, Chandra PS, Kale SS, Kumar R, et al. Randomized trial for superiority of high field strength intraoperative magnetic resonance imaging guided resection in pituitary surgery. *J Clin Neurosci* 2017;37:96-10. doi: 10.1016/j.jocn.2016.10.044.
- Salimi A, Sharifi G, Bahrani H, Mohajerani SA, Jafari A, Safari F, et al. Dexmedetomidine could enhance surgical satisfaction in Transsphenoidal resection of pituitary adenoma. *J Neurosurg Sci* 2017;61:46-52. doi: 10.23736/S0390-5616.16.02792-2.
- Misra S, Parthasarathi G, Vilanilam GC. The effect of gabapentin premedication on postoperative nausea, vomiting, and pain in patients on preoperative dexamethasone undergoing craniotomy for intracranial tumors. *J Neurosurg Anesthesiol* 2013;25:386-91. doi: 10.1097/ANA.0b013e31829327eb.
- Soliman RN, Hassan AR, Rashwan AM, Omar AM. Prospective, randomized study to assess the role of dexmedetomidine in patients with supratentorial tumors undergoing craniotomy under general anaesthesia. *Middle East J Anaesthesiol* 2011;21:325-34.
- Singh GP, Prabhakar H, Bithal PK, Dash HH. A comparative evaluation of nitrous oxide-isoflurane vs isoflurane anesthesia in patients undergoing craniotomy for supratentorial tumors: A preliminary study. *Neurol India* 2011;59:18-24. doi: 10.4103/0028-3886.76851.

24. Korula G, George SP, Rajshekhar V, Haran RP, Jeyaseelan L. Effect of controlled hypercapnia on cerebrospinal fluid pressure and operating conditions during transsphenoidal operations for pituitary macroadenoma. *J Neurosurg Anesthesiol* 2001;13:255-9. doi: 10.1097/00008506-200107000-00015.
25. Sarhan KA, Emad R, Mahmoud D, Hasanin A, Hosny O, Al-Sonbaty M, et al. The effect of hyperventilation versus normoventilation on cerebral oxygenation using near infrared spectroscopy in children undergoing posterior fossa tumor resection: A randomized controlled cross-over trial. *Anaesth Crit Care Pain Med* 2023;42:101190. doi: 10.1016/j.accpm.2022.101190.
26. Ali Z, Prabhakar H, Bithal PK, Dash HH. Bispectral index-guided administration of anesthesia for transsphenoidal resection of pituitary tumors: a comparison of 3 anesthetic techniques. *J Neurosurg Anesthesiol* 2009;21:10-5. doi: 10.1097/ANA.0b013e3181855732.
27. Bhagat H, Singhal V, Dash HH, Mahajan S, Mishra N, Pandia MP. Comparative evaluation of intraoperative use of normal saline, Ringer's lactate, and combination of normal saline and Ringer's lactate in neurosurgical patients - A preliminary randomized clinical trial. *Neurol India* 2019;67:452-8. doi: 10.4103/0028-3886.258047.
28. Gopalakrishna KN, Dash PK, Chatterjee N, Easwer HV, Ganesamoorthi A. Dexmedetomidine as an Anesthetic Adjuvant in Patients Undergoing Transsphenoidal Resection of Pituitary Tumor. *J Neurosurg Anesthesiol* 2015;27:209-15. doi: 10.1097/ANA.0000000000000144.
29. Bodaghabadi M, Riazi H, Aran S, Bitaraf MA, Alikhani M, Alahverdi M, et al. Repeated transsphenoidal surgery or gamma knife radiosurgery in recurrent cushing disease after transsphenoidal surgery. *J Neurol Surg A Cent Eur Neurosurg* 2014;75:91-7. doi: 10.1055/s-0033-1345688.
30. Daif AA, Hassan YM, Ghareeb NA, Othman MM, Mohamed SA. Cerebral effect of acute normovolemic hemodilution during brain tumor resection. *J Neurosurg Anesthesiol* 2012;24:19-24. doi: 10.1097/ANA.0b013e31822f0346.
31. Shaheen B, Wig J, Grewal S, Tewari MK. Effect of pipecuronium and pancuronium on intracranial pressure and cardiovascular parameters in patients with supratentorial tumours. *Neurol India* 2000;48:37-42.
32. Jain V, Mitra JK, Rath GP, Prabhakar H, Bithal PK, Dash HH. A randomized, double-blinded comparison of ondansetron, granisetron, and placebo for prevention of postoperative nausea and vomiting after supratentorial craniotomy. *J Neurosurg Anesthesiol* 2009;21:226-30. doi: 10.1097/ANA.0b013e3181a7beaa.
33. Jain AK, Gupta AK, Pathak A, Bhansali A, Bapuraj JR. Excision of pituitary adenomas: randomized comparison of surgical modalities. *Br J Neurosurg* 2007;21:328-31. doi: 10.1080/02688690701395447.
34. Dey A, Adinarayanan S, Bidkar PU, Bangera RK, Balasubramanian V. Comparison of normal saline and balanced crystalloid (plasmalyte) in patients undergoing elective craniotomy for supratentorial brain tumors: A randomized controlled trial. *Neurol India* 2018;66:1338-44. doi: 10.4103/0028-3886.241347.
35. El-Khoury H, Chahrour M, Ghanem KM, Saifi O, Tamim H, El-Solh H, et al. Isolated Central Nervous System Relapse Following Treatment Reduction in Low-risk Acute Lymphoblastic Leukemia at the Children's Cancer Center of Lebanon. *J Pediatr Hematol Oncol* 2020;42:e428-33. doi: 10.1097/MPH.0000000000001785.
36. Gaber M, Selim H, El-Nahas T. Prospective study evaluating the radiosensitizing effect of reduced doses of temozolomide in the treatment of Egyptian patients with glioblastoma multiforme. *Cancer Manag Res* 2013;5:349-56. doi: 10.2147/CMAR.S52147.
37. Gupta T, Sinha S, Chinnaswamy G, Vora T, Prasad M, Bhat V, et al. Safety and efficacy of concurrent carboplatin during full-dose craniospinal irradiation for high-risk/metastatic medulloblastoma in a resource-limited setting. *Pediatr Blood Cancer* 2021;68:e28925. doi: 10.1002/pbc.28925.
38. Mousa HFM, Abd-El-Fatah NK, Darwish OA, Shehata SF, Fadel SH. Effect of Nigella sativa seed administration on prevention of febrile neutropenia during chemotherapy among children with brain tumors. *Childs Nerv Syst* 2017;33:793-800. doi: 10.1007/s00381-017-3372-7.
39. Koundal H, Dhandapani M, Thakur P, Dutta P, Walia R, Sahoo SK, et al. Effectiveness of dietary diabetes insipidus bundle on the severity of postoperative fluid imbalance in pituitary region tumours: A randomized controlled trial. *J Adv Nurs* 2021;77:3911-20. doi: 10.1111/jan.14894.
40. Hajimohammadebrahim-Ketabforoush M, Shahmohammadi M, Keikhaee M, Eslamian G, Vahdat Shariatpanahi Z. Single high-dose vitamin D3 injection and clinical outcomes in brain tumor resection: A randomized, controlled clinical trial. *Clin Nutr ESPEN* 2021;41:153-9. doi: 10.1016/j.clnesp.2020.11.027.
41. Thakur S, Kumar N, Salunke P, Ahuja C, Madan R. A Randomized Study of Short Course (One Week) Radiation Therapy with or without Temozolomide in Elderly and/or Frail Patients with Newly Diagnosed Glioblastoma (GBM). *Asian Pac J Cancer Prev* 2022;23:2317-23. doi: 10.31557/APJCP.2022.23.7.2317.
42. Patil VM, Menon N, Chatterjee A, Tonse R, Choudhari A, Mahajan A, et al. Mebendazole plus lomustine or temozolomide in patients with recurrent glioblastoma: A randomised open-label phase II trial. *EclinicalMedicine* 2022;49:e101449. doi: 10.1016/j.eclinm.2022.101449.
43. Rajaratnam S, Seshadri MS, Chandy MJ, Rajshekhar V. Hydrocortisone dose and postoperative diabetes insipidus in patients undergoing transsphenoidal pituitary surgery: a prospective randomized controlled study. *Br J Neurosurg* 2003;17:437-42. doi: 10.1080/02688690310001611233.
44. Hosseini SM, Arvandi S, Razmjoo S, Shahbazian H, Rahim F, Rafie T, et al. Radiation sensitization with sodium nitrite in patients with brain metastases: a pilot randomized controlled trial. *Med Oncol* 2015;32:46. doi: 10.1007/s12032-015-0493-2.
45. Abd El-Aal HH, Mokhtar MM, Habib E, El-Kashef AT, Fahmy ES. Medulloblastoma: conventional radiation therapy in comparison to chemo radiation therapy in the post-operative treatment of high-risk patients. *J Egypt Natl Canc Inst* 2005;17:301-7.
46. El-Hamamsy M, Elwakil H, Saad AS, Shawki MA. A Randomized Controlled Open-Label Pilot Study of Simvastatin Addition to Whole-Brain Radiation Therapy in Patients With Brain Metastases. *Oncol Res* 2016;24:521-8. doi: 10.3727/096504016X14719078133528.
47. Pashaki AS, Hamed EA, Mohamadian K, Abassi M, Safaei AM, Torkaman T. Efficacy of high dose radiotherapy in post-operative treatment of glioblastoma multiforme--a single institution report. *Asian Pac J Cancer Prev* 2014;15:2793-6. doi: 10.7314/apjcp.2014.15.6.2793.
48. Asghar AH, Mahmood H, Faheem M, Rizvi S, Sajid A, Irfan J. Therapeutic effects of 20 gray radiotherapy over a week in the management of brain metastases. *J Pak Med Assoc* 2009;59:278-81.
49. Goda JS, Dutta D, Raut N, Juvekar SL, Purandare N, Rangarajan V, et al. Can multiparametric MRI and FDG-PET predict outcome in diffuse brainstem glioma? A report from a prospective phase-II study. *Pediatr Neurosurg* 2013;49:274-81. doi: 10.1159/000366167.
50. Zaghoul MS, Nasr A, Tolba M, Refaat A, Youssef A, Mosaab A, et al. Hypofractionated Radiation Therapy For Diffuse Intrinsic Pontine Glioma: A Noninferiority Randomized Study Including 253 Children. *Int J Radiat Oncol Biol Phys* 2022;113:360-8. doi:

- 10.1016/j.ijrobp.2022.01.054.
51. Jalali R, Gupta T, Goda JS, Goswami S, Shah N, Dutta D. et al. Efficacy of Stereotactic Conformal Radiotherapy vs Conventional Radiotherapy on Benign and Low-Grade Brain Tumors: A Randomized Clinical Trial. *JAMA Oncol* 2017;3:1368-76. doi: 10.1001/jamaoncol.2017.0997.
  52. Santra A, Kumar R, Sharma P, Bal C, Julka PK, Malhotra A. Detection of recurrence in glioma: a comparative prospective study between Tc-99m GHA SPECT and F-18 FDG PET/CT. *Clin Nucl Med* 2011;36:650-5. doi: 10.1097/RLU.0b013e318217ae0.
  53. Mallick S, Kunhiparambath H, Gupta S, Benson R, Sharma S, Laviraj MA, et al. Hypofractionated accelerated radiotherapy (HART) with concurrent and adjuvant temozolomide in newly diagnosed glioblastoma: a phase II randomized trial (HART-GBM trial). *J Neurooncol* 2018;140:75-82. doi: 10.1007/s11060-018-2932-3.
  54. Kalaghchi B, Kazemian A, Hassanloo J, Zendehelel K. Granulocyte colony stimulating factor for prevention of craniospinal radiation treatment interruption among central nervous system tumor patients. *Asian Pac J Cancer Prev* 2010;11:1499-502.
  55. Izzuddeen Y, Gupta S, Haresh KP, Sharma D, Giridhar P, Rath GK. Hypofractionated radiotherapy with temozolomide in diffuse intrinsic pontine gliomas: a randomized controlled trial. *J Neurooncol* 2020;146:91-5. doi: 10.1007/s11060-019-03340-7.
  56. El Gantery MM, Abd El Baky HM, El Hossieny HA, Mahmoud M, Youssef O. Management of brain metastases with stereotactic radiosurgery alone versus whole brain irradiation alone versus both. *Radiat Oncol* 2014;9:116. doi: 10.1186/1748-717X-9-116.
  57. Sharma RR, Singh DP, Pathak A, Khandelwal N, Sehgal CM, Kapoor R, et al. Local control of high-grade gliomas with limited volume irradiation versus whole brain irradiation. *Neurol India* 2003;51:512-7.
  58. Thakur D, Dhandapani M, Ghai S, Mohanty M, Dhandapani S. Intracranial Tumors: A Nurse-Led Intervention for Educating and Supporting Patients and Their Caregivers. *Clin J Oncol Nurs* 2019;23:315-23. doi: 10.1188/19.CJON.315-323.
  59. Patil VM, Pande N, Chandrasekharan A, M C, Tonse R, Krishnatry R, et al. Shadow study: randomized comparison of clinic with video follow-up in glioma undergoing adjuvant temozolomide therapy. *CNS Oncol* 2018;7:CNS14. doi: 10.2217/cns-2017-0024.
  60. Mirrahimi B, Mortazavi A, Nouri M, Ketabchi E, Amirjamshidi A, Ashouri A, et al. Effect of magnesium on functional outcome and paraclinical parameters of patients undergoing supratentorial craniotomy for brain tumors: a randomized controlled trial. *Acta Neurochir (Wien)* 2015;157:985-91. doi: 10.1007/s00701-015-2376-x.
  61. Puri T, Goyal S, Julka PK, Nair O, Sharma DN, Rath GK. Lycopene in treatment of high-grade gliomas: a pilot study. *Neurol India* 2010;58:20-3. doi: 10.4103/0028-3886.60389.
  62. Patil VM, Bhelekar A, Menon N, Bhattacharjee A, Simha V, Abhinav R, et al. Reverse swing-M, phase 1 study of repurposing mebendazole in recurrent high-grade glioma. *Cancer Med* 2020;9:4676-85. doi: 10.1002/cam4.3094.
  63. Hessissen L, Parkes J, Amayiri N, Mushtaq N, Sirachainan N, Anacak Y, et al. SIOP PODC Adapted treatment guidelines for low grade gliomas in low and middle income settings. *Pediatr Blood Cancer* 2017;64(Suppl 5):e26737. doi: 10.1002/pbc.26737.
  64. Altaf A, Baqai MWS, Urooj F, Alam MS, Aziz HF, Mubarak F, et al. Utilization of an ultra-low-field, portable magnetic resonance imaging for brain tumor assessment in lower middle-income countries. *Surg Neurol Int* 2023;14:260. doi: 10.25259/SNI\_123\_2023.
  65. Wells JC, Sharma S, Del Paggio JC, Hopman WM, Gyawali B, Mukherji D, et al. An Analysis of Contemporary Oncology Randomized Clinical Trials From Low/Middle-Income vs High-Income Countries. *JAMA Oncol* 2021;7:379-85. doi: 10.1001/jamaoncol.2020.7478.
  66. Rubagumya F, Hopman WM, Gyawali B, Mukherji D, Hammad N, Pramesh CS, et al. Participation of Lower and Upper Middle-Income Countries in Clinical Trials Led by High-Income Countries. *JAMA Netw Open* 2022;5:e2227252. doi: 10.1001/jamanetworkopen.2022.27252.
  67. Grover S, Xu M, Jhingran A, Mahantshetty U, Chuang L, Small W Jr, et al. Clinical trials in low and middle-income countries - Successes and challenges. *Gynecol Oncol Rep* 2016;19:5-9. doi: 10.1016/j.gore.2016.11.007.

---

#### DISCLAIMER

Articles published in JPMA and Supplements of JPMA do not represent the views of the editor or editorial Board. Authors are solely responsible for the opinions expressed and the accuracy of the data.

The contribution of each author towards the published research included in this supplement is the responsibility of the authors and their institutions. It is expected to be in accordance and compliance with the ICMJE Guidelines.

Any questions/queries raised by readers should be directed to the corresponding author.

## SPECIAL COMMUNICATION

## The need for economic evaluations for neuro-oncology in low- and middle-income: the Pakistan perspective

Mashal Murad Shah<sup>1</sup>, Mohammad Hamza Bajwa<sup>2</sup>, Muhammad Usman Khalid<sup>3</sup>, Faiza Urooj<sup>4</sup>, Kaynat Siddiqui<sup>5</sup>, Muhammad Waqas Saeed Baqai<sup>6</sup>, Ahsan Ali Khan<sup>7</sup>, Hafiza Fatima Aziz<sup>8</sup>, Syed Ather Enam<sup>9</sup>

### Abstract

The incidence and prevalence of brain tumours have steadily increased within low- and middle-income countries, similar to patterns seen in high-income countries. In addition to the epidemiological landscape of brain tumours in Pakistan, it is important to consider the economics of brain tumour diagnosis and management to inform policy on neuro-oncological healthcare service delivery. The challenges associated with conducting economic evaluations in LMICs include the ability to receive funding for country-specific estimates, dearth of existing data and methodological development, and the need for investment in economic evaluations of health. Economic evaluations are most useful when funding support is given to country-specific initiatives to allocate resources. Cost and cost components must also be meticulously collected to enable accurate calculations of economic evidence for the decision-making process. To put neuro-oncological care at the forefront of the national health agenda, it is crucial for vigorous epidemiological and economic evidence to be available for policymakers.

**Keywords:** Incidence, Health Care, Brain Neoplasms, epidemiology.

**DOI:** <https://doi.org/10.47391/JPMA.S3.GNO-09>

### Introduction

The incidence and prevalence of brain tumour has steadily increased within low- and middle-income countries (LMICs), similar to patterns seen in high-income countries (HICs).<sup>1</sup> This is due to the shift in the epidemiology of the disease from an acute illness to a chronic condition, as a result of improved diagnostic and therapeutic methods.<sup>2</sup> However, the prolonged nature of brain tumour treatment, which can span months to years, coupled with the need for regular follow-up care, has led to a rise in treatment costs. While HICs can afford to invest

in new technologies and innovative treatments, LMICs must focus on implementing standardised care protocols for brain tumour treatment in low-resource settings. This requires targeted policy that addresses issues in the healthcare pipeline which impede the care of brain tumour patients.

Policy formulation often begins with epidemiological data to determine the burden of disease and scope of the problem. The Pakistan Society of Neuro-oncology (PASNO) and the Aga Khan University's Centre of Global Surgical Care (CGSC) conducted a nationwide cross-sectional study to assess brain tumour distribution in Pakistan, known as the Pakistan brain tumour epidemiology study (PBTES).<sup>3</sup> The purpose of this study was to establish the current epidemiological landscape of brain tumours in Pakistan and analyse distribution according to various factors affecting brain tumour care across the healthcare spectrum. This was the first study to quantify brain tumour burden at the national level and can provide direction for future cancer surveillance efforts in both the epidemiological and molecular fields.

In addition to the epidemiological landscape of brain tumours in Pakistan, it is important to consider the economics of brain tumour diagnosis and management to inform policy on neuro-oncological healthcare service delivery. Economic evaluations are a crucial part of the decision-making process in the healthcare. They help policymakers, healthcare providers, and other stakeholders to determine the most efficient and cost-effective ways to allocate resources to improve population health.<sup>4</sup> A systematic literature search for economic evaluations of various aspects of brain tumour care identified only two of the 85 articles as being from LMICs, and one of these was from South Asia. This indicates a need to explore costs, cost-effectiveness and quality of life for brain tumour patients in country-specific contexts in order to mobilize political will to support neurological policy and health services (Figure 2).

However, conducting economic evaluations in resource-constrained areas comes with challenges and limitations.<sup>5</sup>

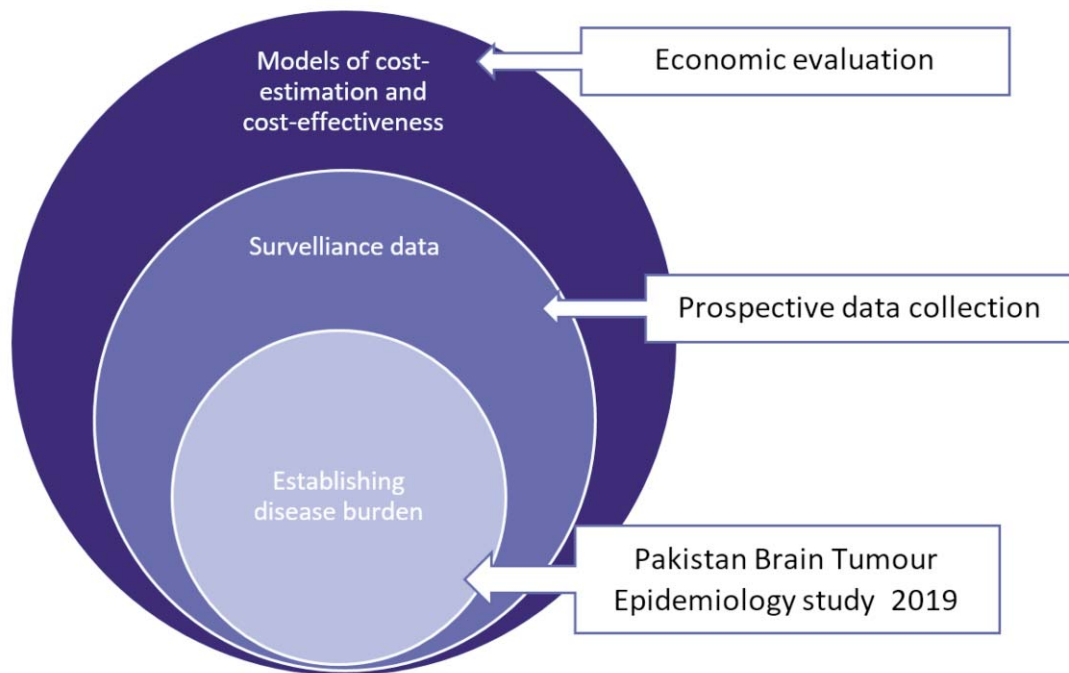
<sup>1</sup>Department of Surgery, The Aga Khan University, Karachi, Pakistan.

<sup>2,3,5-9</sup>Department of Neurosurgery, The Aga Khan University, Karachi, Pakistan.

<sup>4</sup>The Aga Khan Medical College and University, Karachi, Pakistan.

**Correspondence:** Syed Ather Enam **Email:** [ather.enam@aku.edu](mailto:ather.enam@aku.edu)





**Figure-1:** Health Policy Decision-making Components in Pakistan.

Pitt et al. identified these challenges as the ability to receive funding for country-specific estimates, dearth of existing data and methodological development, and the need for investment in economic evaluations of health.<sup>6</sup>

### Prioritizing funding support

Economic evaluations of health have been shown to improve health outcomes, establish practice guidelines, and develop public reimbursement lists and negotiate prices.<sup>7</sup> This evidence is lacking in many LMICs, including Pakistan. Furthermore, non-communicable diseases, such as cancer, were historically ranked low on the global health agenda for many years, while, in LMICs, maternal and child health and infectious disease were often prioritised in deliberative priority setting exercises, resulting in greater attention from funding agencies worldwide.<sup>8</sup> Additionally, funding agencies tend to finance regional or multi-country studies, which result in generalised estimates.<sup>6</sup> For economic evaluations to be useful in policymaking, it is essential that burden of disease, costs, and cost-effectiveness data are all collected in the local context in which they will be used to allocate resources.

### Evidence gaps and Methodological development and investment

In high-income countries, robust health information systems allow for costing and cost-effectiveness studies of various conditions and treatment strategies. From a

provider perspective, direct costs for brain tumour care in the United States have been categorised as: craniotomy costs alone, post-operative radiotherapy costs alone, craniotomy followed by radiotherapy costs, standard of care treatment costs, disease first recurrence after treatment costs, and adjunctive therapy costs.<sup>9</sup> Costs from a patient perspective found in a cost-of-illness study in Sweden indicated that the direct costs for brain tumour care involved ambulatory care, hospital care, long-term and home care, and drugs. Ambulatory and hospital care can further be broken down into diagnostic radiology, major surgery, radiation therapy costs.<sup>10</sup> It is important to also examine indirect costs such as loss of productivity for the individual and loss of productivity by caregivers and informal care costs. Indirect costs to the patient and patient's household included sick leave, retirement, and mortality.<sup>10</sup> Many of the costs and cost components associated with brain tumour care have been determined by HICs; it is important for LMICs such as Pakistan to determine our own costs and effectiveness, along with our disease burden, to be able to adequately prioritise interventions for brain tumour treatment and management. Using the cost components from HICs as a guide, it is important for Pakistan to create its own costs database. Health systems constraints associated with limited financial data must be mitigated in order to successfully carry out economic evaluations for decision making.

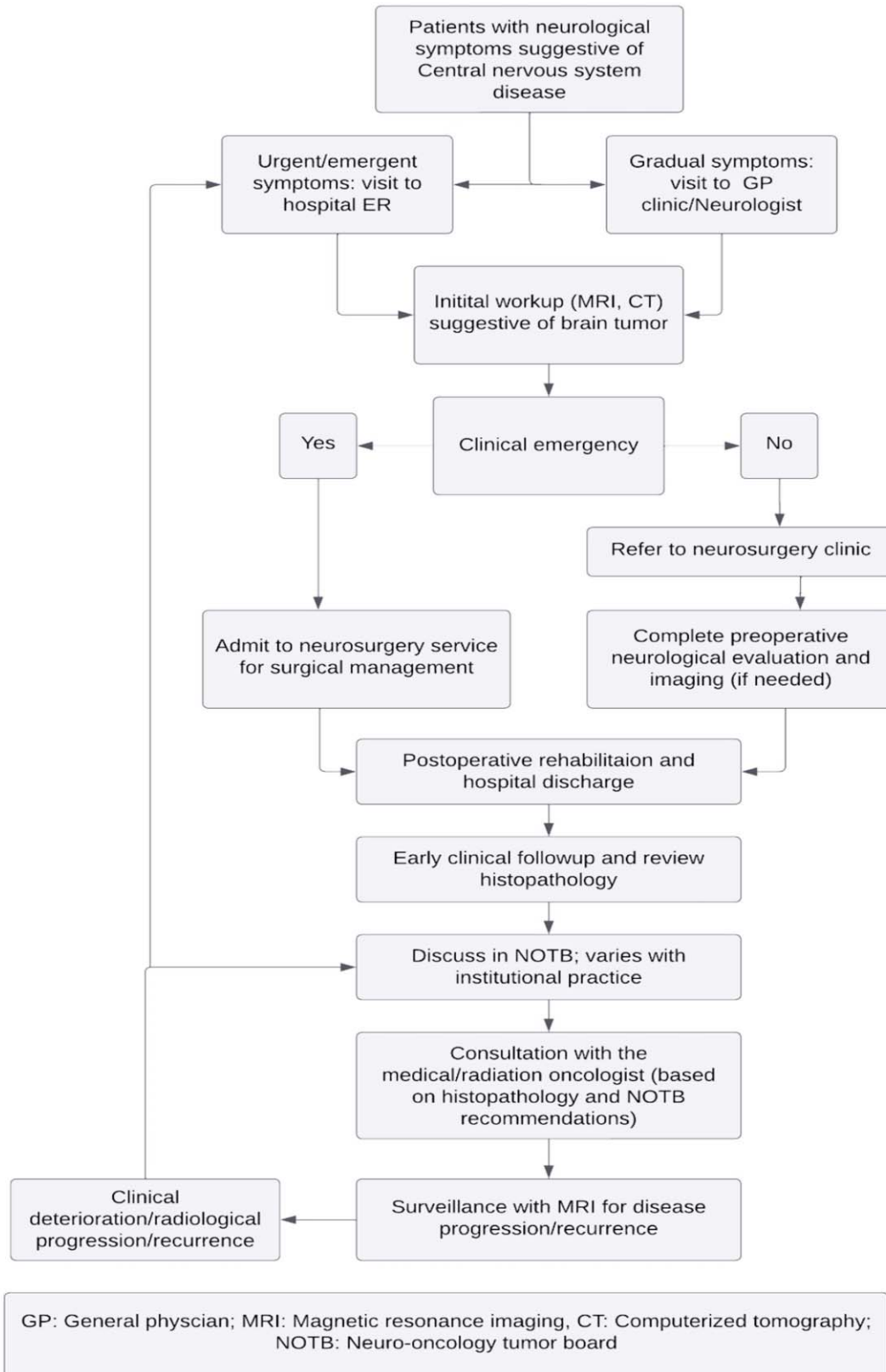


Figure-2: Proposed Brain Tumour Care Pathway in Pakistan..

While Pakistan has shown commitment to moving towards universal health coverage, the existing health system is a mix of public and private sector facilities that provide neuro-oncological care. Therefore, both government and societal perspectives need to be considered. In Pakistan, 56.24% of all health expenditure is paid out-of-pocket.<sup>11</sup> This, along with the productivity loss associated with brain tumour treatment and management, results in a high cost-of-illness for brain tumours. It is important to conduct studies which assess, and subsequently implement programmes that can provide protection against financial risk. Without accurate, country-specific data, economic evaluations cannot be efficiently used for decision-making and priority setting in health.

### **Carrying out an economic evaluation in Pakistan for brain tumours: the way forward**

While economic evaluations of brain tumour care in LMICs are rare, they are not unheard of. In Vietnam, a cost-effectiveness analysis of stereotactic radiosurgery versus surgical resection was carried out.<sup>12</sup> To determine costs, both direct and indirect costs were calculated. Out-of-pocket spending percentages were taken from national estimates, and average costs for travel and accommodation were used. Assumptions were made for the number of caregivers and the productivity loss associated with taking time off from work and/or school. For the effectiveness analysis, survival time was considered as the primary outcome, and the mean survival time was used in their calculations.

Cost-effectiveness analyses, and other economic evaluations, can be similarly executed in Pakistan, despite the health systems constraints associated with neuro-oncological care. This has been demonstrated by an economic evaluation that was carried out for neurovascular disease intervention in 2009.<sup>13</sup> Out-of-pocket spending is typically well-documented in private health facilities, which can be used to calculate patient perspective costs. In public hospitals, which are nominally free at the point of care, hospital costs can be used to estimate provider costs, whereas patient spending on consumables must also be considered for the societal perspective. Often, public hospitals do not keep meticulous records of their budgets for specific disease management. While this is a process that will require time to effectively implement, starting with policy to consistently documented financial data is the first step to accurately estimate cost-of-illness and cost-effectiveness to further draft policy on streamlining neuro-oncological care. Financial data can also be estimated from various stages of the brain tumour care pathway. Figure 2

outlines the care pathway in Pakistan; cost components in Pakistan include imaging and diagnosis, surgery costs, initial, preoperative and follow-up clinic visits, postoperative home care and adjuvant chemoradiation.

Effectiveness data, while crucial, may be more difficult to obtain. Like in many LMICs, public hospitals in Pakistan are not recorded in a consistent, standardised manner. The Centre of Global Surgical Care at the Aga Khan University, Pakistan is promoting a culture of robust perioperative (including 30-day) mortality and morbidity as per the Lancet's Global Surgery Indicators.<sup>14</sup> To obtain accurate survival data for brain tumours to determine effectiveness, efforts must be made at provincial and national levels to instill centralised medical record keeping, which can help with both economic health policy and guideline development.

### **Conclusion**

To put neuro-oncological care at the forefront of the national health agenda, it is crucial for vigorous epidemiological and economic evidence to be available for policymakers. By understanding the challenges to performing economic evaluations in LMICs, we can adapt methods to individual country contexts for decision-making and guideline development.

**Disclaimer:** None.

**Conflict of Interest:** None.

**Funding disclosure:** None.

### **References**

1. Bell JS, Koffie RM, Rattani A, Dewan MC, Baticulon RE, Qureshi MM, et al. Global incidence of brain and spinal tumors by geographic region and income level based on cancer registry data. *J Clin Neurosci* 2019;66:121-7. doi: 10.1016/j.jocn.2019.05.003.
2. Di Luca M, Nutt D, Oertel W, Boyer P, Jaarsma J, Destrebecq F, et al. Towards earlier diagnosis and treatment of disorders of the brain. *Bull World Health Organ* 2018;96:298-. doi: 10.2471/BLT.17.206599.
3. Enam SA, Baig E, Shah MM, Bajwa MH, Khalid MU, Tahir I, et al. The Pakistan Brain Tumor Epidemiology Study—gaps in patient care. *Brain Tumor Res Treat* 2022;10(Suppl 1):s427. doi:10.14791/btrt.2022.10.F-1208.
4. Cairns J, Fox-Rushby JA. Economic Evaluation: Understanding Public Health, 1st ed. In: Fox-Rushby JA, Cairns J, eds. New York, USA: Open University Press, 2005; pp 253.
5. Griffiths UK, Legood R, Pitt C. Comparison of Economic Evaluation Methods Across Low-income, Middle-income and High-income Countries: What are the Differences and Why? *Health Econ* 2016;25(Suppl 1):29-41. doi: 10.1002/hec.3312.
6. Pitt C, Vassall A, Teerawattananon Y, Griffiths UK, Guinness L, Walker D, et al. Foreword: Health Economic Evaluations in Low- and Middle-income Countries: Methodological Issues and Challenges for Priority Setting. *Health Econ* 2016;25(Suppl 1):1-5. doi: 10.1002/hec.3319.
7. Rabarison KM, Bish CL, Massoudi MS, Giles WH. Economic

- Evaluation Enhances Public Health Decision Making. *Front Public Health* 2015;3:164. doi: 10.3389/fpubh.2015.00164.
8. Parkhurst JO, Vulimiri M. Cervical cancer and the global health agenda: Insights from multiple policy-analysis frameworks. *Glob Public Health* 2013;8:1093-108. doi: 10.1080/17441692.2013.850524.
  9. Goel NJ, Bird CE, Hicks WH, Abdullah KG. Economic implications of the modern treatment paradigm of glioblastoma: an analysis of global cost estimates and their utility for cost assessment. *J Med Econ* 2021;24:1018-24. doi: 10.1080/13696998.2021.1964775.
  10. Blomqvist P, Lycke J, Strang P, Törnqvist H, Ekblom A. Brain tumours in Sweden 1996: care and costs. *J Neurol Neurosurg Psychiatry* 2000;69:792-8. doi: 10.1136/jnnp.69.6.792.
  11. The World Bank. Out-of-pocket expenditure (% of current health expenditure) - Pakistan. [Online] 2023 [Cited 2024 March 21]. Available from URL: <https://data.worldbank.org/indicator/SH.XPD.OOPC.CH.ZS?locations=PK>
  12. Dao A. What it means to say "I Don't have any money to buy health insurance" in rural Vietnam: How anticipatory activities shape health insurance enrollment. *Soc Sci Med* 2020;266:113335. doi: 10.1016/j.socscimed.2020.113335.
  13. Zubair Tahir M, Enam SA, Pervez Ali R, Bhatti A, ul Haq T. Cost-effectiveness of clipping vs coiling of intracranial aneurysms after subarachnoid hemorrhage in a developing country--a prospective study. *Surg Neurol* 2009;72:355-60. doi: 10.1016/j.surneu.2008.11.003.
  14. Meara JG, Leather AJ, Hagander L, Alkire BC, Alonso N, Ameh EA, et al. Global Surgery 2030: evidence and solutions for achieving health, welfare, and economic development. *Lancet* 2015;386:569-624. doi: 10.1016/S0140-6736(15)60160-X.

---

**DISCLAIMER**

Articles published in JPMA and Supplements of JPMA do not represent the views of the editor or editorial Board. Authors are solely responsible for the opinions expressed and the accuracy of the data.

The contribution of each author towards the published research included in this supplement is the responsibility of the authors and their institutions.

It is expected to be in accordance and compliance with the ICMJE Guidelines.

Any questions/queries raised by readers should be directed to the corresponding author.

## A guideline on guidelines: neuro-oncology guideline standards for low- and middle-income countries

Mohammad Hamza Bajwa<sup>1</sup>, Mashal Murad Shah<sup>2</sup>, Fatima Mustansir<sup>3</sup>, Fatima Gauhar<sup>4</sup>, Erum Baig<sup>5</sup>, Syed Nabeel Zafar<sup>6</sup>, Kaynat Siddiqui<sup>7</sup>, Hafiza Fatima Aziz<sup>8</sup>, Syed Ather Enam<sup>9</sup>

### Abstract

Guidelines for low- and middle-income countries (LMICs) are needed in complex, multidisciplinary areas such as oncology, requiring mobilising considerable resources and specialists for coordinated care. Neuro-oncology guidelines have been primarily established in countries where technological advancements and robust care pathways facilitate broad resource utilisation. In contrast, LMICs require complex and region-specific interventions to provide equitable care. The present opinion paper is a culmination of our own centre's experience collaborating and developing loco-regional guidelines for brain tumour care, keeping in mind LMIC experiences and expertise available. We intend for the process and methodology to apply to a broader audience of other LMIC authors and clinicians collaborating with LMIC institutions to develop guidelines and clinical recommendations.

**Keywords:** : neuro-oncology, surgery, Critical Pathways, Brain Neoplasms

**DOI:** <https://doi.org/10.47391/JPMA.S3.GNO-10>

### Introduction

Standardising oncological care has helped to improve patient care and survival.<sup>1</sup> Guidelines are an essential instrument for ensuring uniform care. The Guidelines International Network database, a global network cataloging clinical guidelines from major institutions and working groups, lists over 3,700 guidelines from 39 countries.<sup>2</sup> A majority of these are developed at research institutions within HICs.<sup>3</sup> Owolabi et al. reported in a systematic review of guidelines on hypertension that only one manuscript was from a low-income country.<sup>4</sup> When trying to apply clinical standards to neuro-oncology in

<sup>1,7-9</sup>Department of Neurosurgery, The Aga Khan University, Karachi, Pakistan.

<sup>2,5</sup>Department of Surgery, The Aga Khan University Hospital, Karachi, Pakistan.

<sup>3</sup>Department of Surgery, Washington University School of Medicine, Missouri, USA. <sup>4</sup>The Aga Khan Medical College and University, Karachi, Pakistan.

<sup>6</sup>Department of Surgical Oncology, University of Wisconsin School of Medicine and Public Health, Wisconsin, USA.

**Correspondence:** Syed Ather Enam **Email:** [ather.enam@aku.edu](mailto:ather.enam@aku.edu)

low- and middle-income countries (LMIC) we have observed a lack of local data in major guidelines, absence of collaborations and conformation to best clinical practices amongst local clinicians and researchers, and the lack of consideration of applicability of recommendations.<sup>5</sup> In neuro-oncology, most guidelines are developed within the global North, with a focus on molecular classification of CNS tumours and updated treatment options, as evidenced by recent updates in the 2021 WHO Classification of Primary Brain Tumours.<sup>6</sup> Molecular panels can be cost-prohibitive particularly when considering assays and genetic sequencing. To truly reach a cohesive aim for global oncology, we must give more value to the transferability of these recommendations in more resource-limited setting. The 2009 Appraisal of Guidelines for Research & Evaluation (AGREE II) in particular emphasized the value of applicability to guideline development.<sup>7</sup>

The difficulty in implementing guidelines developed in HICs within LMICs has been demonstrated before; stark differences in the availability of resources and specialized skills and a lack of understanding of local contexts and practices can hinder guidelines-based healthcare.<sup>8</sup> The WHO has highlighted this issue by forming Complex Interventions Working Groups; context-dependent solutions can account for circumstances and variations from region to region.<sup>9</sup> Reporting standards and templates for systematic reviews and guidelines may be the solution to developing complex, perspectives-based guidelines.<sup>10</sup>

Developing this context requires understanding ground-level realities and quantifying system-level deficiencies. Collecting epidemiological data to define the problem and developing locally derived solutions is possible through multi-center collaborations. Local solutions can be a source of frugal innovations to deliver quality care.<sup>5</sup> Specifically, we need to address the heterogeneity of healthcare systems in LMICs, as they constantly evolve and change with rapid shifts in the availability of resources. Robust infrastructure is not readily available across the country, and supply shortages of medicines

and equipment are too common. Recently, we developed consensus guidelines for management of medulloblastoma, craniopharyngioma, and various other brain tumours in Pakistan (REFERENCES from articles 10-23 of this supplement)<sup>11-24</sup> In this article, we draw upon our experiences and propose solutions for developing equitable guidelines.

### Recommendations development

Evidence suggests higher compliance with guidelines when subject specialists and local clinicians were involved in guideline creation.<sup>25</sup> The Delphi technique is an effective way to engage significant numbers of local stakeholders and experts through a series of questionnaires distributed to subject experts in order to achieve consensus. It has been used to develop guidelines on surgical-site infections, prescription of lower-limb prostheses, and rotator cuff pathology, to name a few.<sup>26-28</sup> Neuro-oncology guideline developers can

take direction from such examples. The involvement of subject experts and the formation of working groups to tackle LMIC-based issues within neuro-oncology effectively is a thoughtful approach –evidence-based discussions generate credibility and acceptance within the local academic community. Priority should be given to experts from varying resource settings that may shed light on healthcare inequalities previously unreported. Whether brain tumour patients are being treated at peripheral rural-care centres or densely-populated urban cities, we intend to develop locally applicable guidelines to provide recommendations that can be followed within the available resources.

Effective guidelines require establishing evidence-based standards of care with resource-stratification and applicability. Recommending technologies that require significant investment and infrastructure may undermine basic surgical and oncological care capacity. Resource

**Table-1:** Developing guidelines in LMICs.

---

#### *Assembling a Team*

The formation of a multidisciplinary guidelines committee involves:

1. Senior subject-experts with considerable experience in LMICs
2. Junior researchers with expertise in conducting literature review and scientific manuscript writing

It is particularly necessary to include clinicians and researchers from various hospitals, with a spectrum of centres ranging from academic, high volume centres in major cities as well as practitioners in the peripheries. This will promote guidelines ownership and adoption.

Under the guidance of senior members, guidelines working groups can be formed with direction given to junior members in carrying out literature searches for clinical evidence and current recommendations. These can be further refined through the experience and input by subject-experts.

---

#### *The Process*

It is advisable to first hold general meetings with all members of a guidelines committee to reach a consensus on the aims and direction of the proposed guidelines. The committee must define the role of each member in development of guidelines and specific deadlines. It can also be advisable to break into sub-groups with consideration to every associated specialty, with the intention of reconvening.

Particularly for LMIC guidelines, it is imperative to define the following:

1. Contentious points in clinical management that require addressing
2. Gaps in management that are observed in LMICs (e.g. through meetings and research, we have collected anecdotal evidence of a lack of standardised surgical guidelines in operating on prolactinomas)
3. A focus on cost-effectiveness, applicability and ensuring equitable access to standardised care in recommendations

Committees must identify the current standard of care in LMICs and address issues in care with concise and precise recommendations. Further debate and discussion can occur within the committee, resulting in formation of multiple draft papers, reviews by senior members, and ratification by the committee as a whole.

It is essential that points of contention and criticism be met with evidence-guided debate with consideration for all stakeholders.

---

#### *Post-production*

Committees should consider dissemination of their papers locally to increase local access to guidelines and elevate national standards of research. This can be done through national scientific associations and conferences. Endorsements from local hospitals and educational institutions can be vital.

The template for the guidelines paper can be modified and adjusted for use in other, future guidelines publications.

---

**Table-2:** Summary of Recommendations**Recommendations**

Developing equitable partnerships with clinicians and researchers in LMICs.  
 Considerations for cost-effectiveness and transferability of established solutions in more developed countries.  
 Context-based solutions can be more effective and are more acceptable.  
 Guideline committees in LMICs should include stakeholders from all disciplines involved in neuro-oncological care.  
 Ratification processes, such as the Delphi method or those similar to the NCCN Harmonized Guidelines, can be used for group consensus  
 Resource-stratification of recommendations.

stratification of recommendations is a viable solution; 'minimal required' and 'preferred but optional' classifications, similar to the American Society of Clinical Oncology (ASCO) Resource-Stratified Guidelines.<sup>29</sup> The aim was to mobilise the resources and expertise available through members of HICs and the international world at large in order to guide cancer prevention and care guidelines across the world. Varying levels of resources in LMICs were addressed through a four-tier resource-stratification system and ensured evidence-based guidelines development through a systematic review and the modified ADAPTE process. Colour-coded frameworks have also been put forward by the NCCN Harmonized Guidelines,<sup>30</sup> with recommendations in black denoting generally agreed-upon minimum acceptable standards, grey for optimal but understandably advanced-care recommendations that can be followed but should not be a limiting factor in providing care, and blue for regionally appropriate options of care.

As a result of our own experiences in creating national neuro-oncology guidelines, we propose an approach for developing guidelines in LMICs (Table 1). Guidelines start with a systematic review of the literature and appraisal of current guidelines published within HICs. This undergoes rigorous review and validation of the current recommendations through established instruments, such as the AGREE II tool and ASCO Guideline Endorsement Content Review Form.<sup>31,32</sup> Guideline committee members should particularly pay attention to the rigor of methodology of previously written guidelines as given in AGREE II; this is a critical factor in determining the quality of evidence produced.

The pooled review and analysis can be modified and updated according to expertise provided by senior guidelines committee members and then be taken to a consensus panel discussion. The committee can undergo various procedures, such as the Delphi technique, process, discuss, and take consensus votes on individual

recommendations and edits. Generally speaking, most ( $\geq 75\%$ ) of the voting members of the panel should strongly agree, or agree, for ratification of each recommendation. These processes can take place through virtual conferences, allowing adequate time and consideration to all members regardless of their location or ability to travel. An excellent example is the development of the NCCN Harmonized Guidelines™ for Sub-Saharan Africa which allowed local community health leaders to vote via device applications on the importance of certain services over others.<sup>30</sup> Meetings were conducted twice yearly and allowed guidelines working groups to include multidisciplinary experts for clarification and expertise in discussions. Over three days, these working groups were able to agree on recommendations and harmonise these guidelines.

Once the guidelines have been agreed upon, manuscript preparation will take place. We recommended that a standardised syntax be used throughout the draft paper for clarity, readability, and understanding of what is being said. Resources such as the Guide Lines Into Decision Support (GLIDES) methodology<sup>33</sup> have shown great promise in this regard. After this, dissemination becomes the end goal which can be achieved with the help of international collaborators, for critical appraisal and visibility. Knowledge of ground-level circumstances will play a crucial role in helping global researchers improve research and guidelines while ensuring LMIC perspectives have a central role in the proposal of solutions. HIC international programmes can help early-career LMIC neuro-oncologists investigate and validate these guidelines.

**Implementation in neuro-oncology**

Based on these infrastructural and financial limitations and unique cultural practices in LMICs, we believe guidelines that are constructed accordingly would be more practical and suitable to our setting. Consider these examples of proposing resource-stratified guidelines in neuro-oncology:

**Follow-up compliance**

A large part of neuro-oncology care delivery is adequate follow-up and treating recurrent disease. In our clinical settings, we see many patients who fail to follow up and receive adjuvant chemoradiotherapy after tumour resection and will once again present to the emergency department, typically with a more malignant and aggressive tumour. The Pakistan Brain Tumour Consortium (PBTC) conducted a country-wide epidemiological survey of major neurosurgical centers in 2019; we found that most patients who underwent

surgical resection for a brain tumour had no record of receiving adjuvant chemotherapy or radiation therapy<sup>34</sup>. This is astonishing as gliomas, especially high-grade gliomas, tend to be seen frequently at our centres. The loss of patients to follow-up is a critical reason why morbidity and mortality of brain tumours have become a growing problem in LMICs. Our recommendations are:

- i. Inclusion of minimum follow-up timelines, with extended and shorter dates for follow-ups, when considering patients at higher risk for complications and the need for timely intervention
- ii. Reducing follow-up imaging and testing to a minimum would guide clinical decision-making without becoming a financial barrier for the patient
- iii. Development of low-cost interventions to continue patient follow-ups

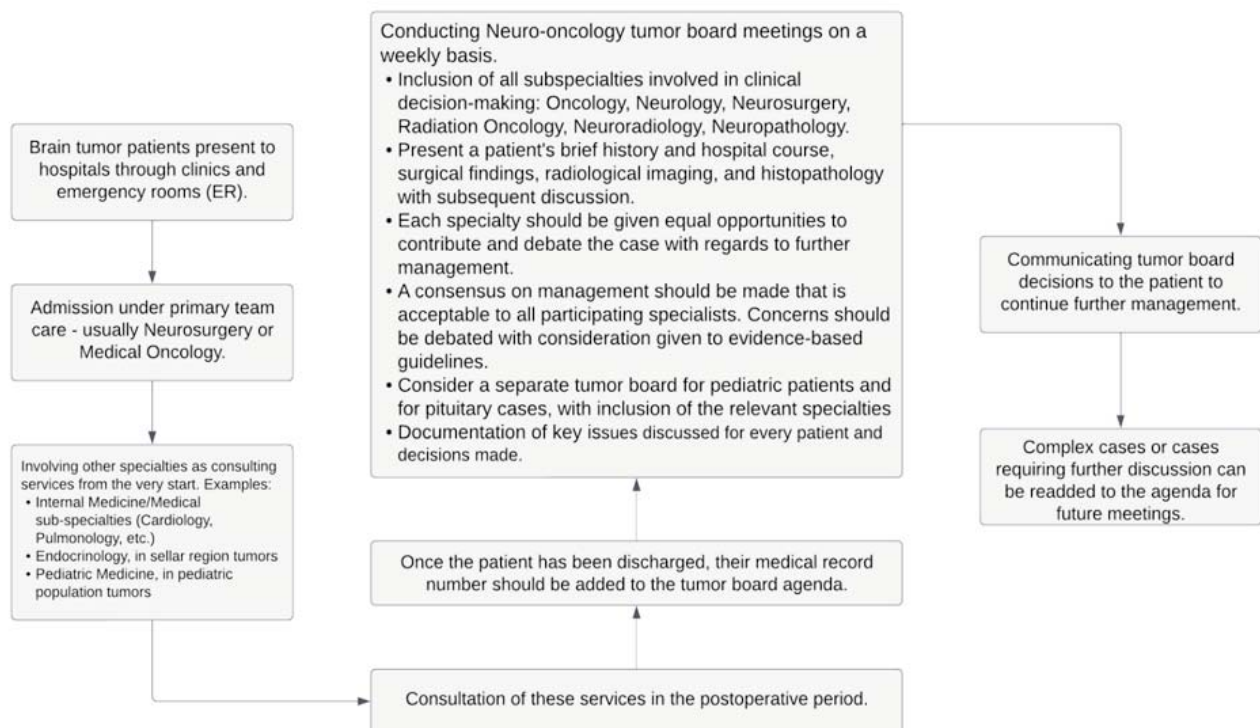
### A multidisciplinary approach to neuro-oncological patients

A patient with symptoms suggestive of a brain tumour needs a battery of specialists to help accurately diagnose, treat, and further follow up on the later-stage complications and difficulties the patient faces. It is standard within HICs for a patient's case to be discussed at

a multidisciplinary neuro-oncology tumour board.<sup>35</sup> Often, the neuro-oncologist or neurosurgeon presents relevant imaging, histopathology, and clinical findings to an audience from various fields. Moreover, this is incredibly fruitful; according to the imaging available, an expert neuro-radiologist can guide the surgical team in opting for a less invasive biopsy approach if maximal safe resection is not indicated. Guidelines on every specialty are considered in treating the disease holistically.<sup>36</sup> Tumour boards in LMICs are sparse and scattered discussing Pakistan, for instance, standardised tumour boards with stakeholders from all specialties are present in a few academic institutions, often located in private sector hospitals.<sup>37</sup> Figure 1 proposes the steps institutions can take to form multidisciplinary tumour boards and include all concerned specialties.

### Diagnostic imaging

Our recommendation for the ideal approach to initial imaging needed to diagnose most brain tumours is MRI imaging with complete protocols, i.e., T1, T2, T1-post contrast, DWI, SWI, and other imaging protocols dependent on the type of tumour diagnosed on scans and preoperative requirements (e.g., Diffusor-tensor imaging). If facilities to attain complete protocols are unavailable, we recommend that patients have an MRI



**Figure1:** Formation of Multidisciplinary Tumour Boards.



scan with a minimum of T1, T2, and T1-post contrast images. CT scans can also be used to supplement findings.

### Complex cases in surgical neuro-oncology

Surgery for brain tumours is another infrastructure-dependent factor. Within LMICs, few specialist neurosurgeons have certifications in neuro-oncology or paediatric neurosurgery (in the case of paediatric brain tumour patients). As a result, most cases are handled by general neurosurgeons, some with clinical interests in brain tumour surgery. However, in complex cases especially, management can be variable with a greater propensity for mismanagement or a lack of infrastructure resulting in poor clinical outcomes. The solution would be to develop recommendations that encourage and necessitate the collaboration of low-volume centres with higher-volume academic centres.

Moreover, we can encourage standardised surgical protocols that can be applied in resource-deficient settings. Overburdened urban centres, where long waiting lists, lack of resources, and structural loopholes can result in issues managing brain tumour patients. Our solution would be for guidelines to incorporate minimum required recommendations with standardisation of protocols to ensure patients are treated with standardized surgical practices and followed up timely.

Considering resource constraints, it is more appropriate to consider the available facilities and recommend them accordingly. However, if possible, a more exhaustive battery of radiological investigations can be ordered if a patient can afford these facilities and they are readily available. Nevertheless, in setting up minimum standards for applying these guidelines, we do not alienate hospitals and healthcare centers in most regions. It is crucial to remember that while advanced neurosurgical and oncological protocols may prove to be applicable and better for patients in HICs, it is ultimately a question of transferability. Will the provision of advanced technologies and the pursuit of treatments that are costly and not transferable to the larger region benefit the public health crisis of morbidity secondary to brain tumours? Perhaps LMICs will benefit from targeted and precise practices addressing the most pressing concerns in neuro-oncology.

### Conclusion

Preferring quality, evidence, and context-based guidelines over many guidelines that miss the target is our priority within neuro-oncology research in LMICs. By expanding our horizons, we can attempt to identify and meet gaps in neuro-oncological management,

particularly where standardised management and approaches are sorely needed. Standardising, optimizing, and utilising clinical recommendations within these settings may prove fruitful in reducing disease burden and improving patient outcomes (Table 2).

**Disclaimer:** None.

**Conflict of Interest:** None.

**Source of Funding:** None.

### References

1. Koh WJ, Anderson BO, Carlson RW. NCCN resource-stratified and harmonized guidelines: A paradigm for optimizing global cancer care. *Cancer* 2020;126(Suppl 10):s2416-23. doi: 10.1002/cncr.32880
2. Ollenschläger G, Marshall C, Qureshi S, Rosenbrand K, Burgers J, Mäkelä M. et al. Improving the quality of health care: using international collaboration to inform guideline programmes by founding the Guidelines International Network (G-I-N). *Qual Saf Health Care* 2004;13:455-60. doi: 10.1136/qhc.13.6.455
3. Griswold DP, Khan AA, Chao TE, Clark DJ, Budohoski K, Devi BI, et al. Neurosurgical Randomized Trials in Low- and Middle-Income Countries. *Neurosurgery* 2020;87:476-83. doi: 10.1093/neuros/nyaa049
4. Owolabi M, Olowoyo P, Miranda JJ, Akinyemi R, Feng W, Yaria J, et al. Gaps in Hypertension Guidelines in Low- and Middle-Income Versus High-Income Countries: A Systematic Review. *Hypertension* 2016;68:1328-37. doi: 10.1161/HYPERTENSIONAHA.116.08290
5. Jumbam DT, Durnwald L, Munabi NCO, Ayala R. Implementation science: A missing link in global surgery. *East Cent Afr J Surg* 2021;26:45. DOI: 10.4314/ecajs.v26i2.1
6. Louis DN, Perry A, Wesseling P, Brat DJ, Cree IA, Figarella-Branger D, et al. The 2021 WHO Classification of Tumors of the Central Nervous System: a summary. *Neuro Oncol* 2021;23:1231-5. doi: 10.1093/neuonc/noab106
7. Hoffmann-Eßer W, Siering U, Neugebauer EAM, Brockhaus AC, McGauran N, Eikermann M. Guideline appraisal with AGREE II: online survey of the potential influence of AGREE II items on overall assessment of guideline quality and recommendation for use. *BMC Health Serv Res* 2018;18:143. doi: 10.1186/s12913-018-2954-8
8. Olayemi E, Asare EV, Benneh-Akwasi Kuma AA. Guidelines in lower-middle income countries. *Br J Haematol* 2017;177:846-54. doi: 10.1111/bjh.14583
9. Booth A, Moore G, Flemming K, Garside R, Rollins N, Tunçalp Ö, et al. Taking account of context in systematic reviews and guidelines considering a complexity perspective. *BMJ Glob Health* 2019;4:e000840. doi: 10.1136/bmjgh-2018-000840
10. Petticrew M, Knai C, Thomas J, Rehfuss EA, Noyes J, Gerhardus A, et al. Implications of a complexity perspective for systematic reviews and guideline development in health decision making. *BMJ Glob Health* 2019;4:e000899. doi: 10.1136/bmjgh-2018-000899
11. Khan AA, Waheed AA, Ahmed AA, Hafiz A, Zaki A, Gilani A, et al. Consensus Guidelines For The Management Of Adult Low-Grade Gliomas For Low And Middle-Income Countries. *J Pak Med Assoc* 2024;74(Suppl 3):s93-9. Doi: 10.47391/JPMA.S3.GNO-11.
12. Enam SA, Aziz HF, Bakhshi SK, Altaf A, Siddiqui K, Hafiz A, et al. Consensus guidelines for the management of adult high-grade gliomas for low and middle-income countries. *J Pak Med Assoc*

- 2024;74(Suppl 3):s100-8. Doi: 10.47391/JPMA.S3.GNO-12.
13. Enam SA, Shakir M, Khan AA, Tahir M, Siddiqui K, Shamim MS, et al. Consensus guidelines for the management of vestibular schwannoma for low and middle-income countries. *J Pak Med Assoc* 2024;74(Suppl 3):s109-14. Doi: 10.47391/JPMA.S3.GNO-13.
  14. Enam SA, Bajwa MH, Mustansir F, Baig E, Gauhar F, Arif A, et al. Consensus guidelines for the management of pediatric medulloblastoma in low and middle-income countries. *J Pak Med Assoc* 2024;74(Suppl 3):s115-24. Doi: 10.47391/JPMA.S3.GNO-14.
  15. Enam SA, Mushtaq N, Khalid MU, Bajwa MH, Khan AA, Verani SS, et al. Consensus guidelines for the management of craniopharyngioma in low and middle-income countries. *J Pak Med Assoc* 2024;74(Suppl 3):s125-33. Doi: 10.47391/JPMA.S3.GNO-15.
  16. Bakhshi SK, Tariq R, Tariq M, Hafiz A, Gilani A, Aziz HF, et al. Consensus guidelines for the management of pineal region tumours for low and middle-income countries. *J Pak Med Assoc* 2024;74(Suppl 3):s134-43. Doi: 10.47391/JPMA.S3.GNO-16.
  17. Khan AA, Khalid MU, Bajwa MH, Tahir I, Paracha S, Shakir M, et al. Consensus guidelines for the management of intracranial ependymoma for low and middle-income countries. *J Pak Med Assoc* 2024;74(Suppl 3):s144-50. Doi: 10.47391/JPMA.S3.GNO-17.
  18. Enam SA, Masroor M, Bakhshi SK, Shaikat F, Aziz HF, Siddiqui K, et al. Consensus guidelines for the management of intracranial meningioma for low and middle-income countries. *J Pak Med Assoc* 2024;74(Suppl 3):s151-7. Doi: 10.47391/JPMA.S3.GNO-18.
  19. Aziz HF, Suleman F, Hafiz A, Bajwa MH, Gilani A, Siddiqui K, et al. Consensus guidelines for the management of brain stem and diffuse midline glioma for low and middle-income countries. *J Pak Med Assoc* 2024;74(Suppl 3):s158-66. Doi: 10.47391/JPMA.S3.GNO-19.
  20. Aziz HF, Bakhshi SK, Ahmed N, Bajwa MH, Jabbar AA, Hafiz A, et al. Consensus guidelines for the management of primary central nervous system lymphoma for low and middle-income countries. *J Pak Med Assoc* 2024;74(Suppl 3):s167-75. Doi: 10.47391/JPMA.S3.GNO-20.
  21. Aziz HF, Bakhshi SK, Javed Z, Hafiz A, Zaki A, Siddiqui K, et al. Consensus guidelines for the management of intracranial metastases for low and middle-income countries. *J Pak Med Assoc* 2024;74(Suppl 3):s176-84. Doi: 10.47391/JPMA.S3.GNO-21.
  22. Enam SA, Urooj F, Siddiqui K, Bajwa MH, Aziz HF, Shaikat F, et al. Judicious and evidence-based use of radiosurgery - recommendations for low-middle income countries. *J Pak Med Assoc* 2024;74(Suppl 3):s200-10. Doi: 10.47391/JPMA.S3.GNO-24.
  23. Aziz HF, Bajwa MH, Bakhshi SK, Siddiqui K, Khan SA, Shakir M, et al. Consensus guidelines for the management of posterior fossa tumour for low and middle-income countries. *J Pak Med Assoc* 2024;74(Suppl 3):s185-9. Doi: 10.47391/JPMA.S3.GNO-22.
  24. Aziz HF, Bakhshi SK, Tariq R, Baqai MWS, Bajwa MH, Siddiqui K, et al. Consensus guidelines for the management of primary supratentorial intraventricular tumour for low and middle-income countries. *J Pak Med Assoc* 2024;74(Suppl 3):s190-9. Doi: 10.47391/JPMA.S3.GNO-23.
  25. Grimshaw JM, Russell IT. Effect of clinical guidelines on medical practice: a systematic review of rigorous evaluations. *Lancet* 1993;342:1317-22. doi: 10.1016/0140-6736(93)92244-n
  26. National Institute for Health Research Global Research Health Unit on Global Surgery. Delphi prioritization and development of global surgery guidelines for the prevention of surgical-site infection. *Br J Surg* 2020;107:970-7. doi: 10.1002/bjs.11530
  27. van der Linde H, Hofstad CJ, van Limbeek J, Postema K, Geertzen JH. Use of the Delphi Technique for developing national clinical guidelines for prescription of lower-limb prostheses. *J Rehabil Res Dev* 2005;42:693-704. doi: 10.1682/jrrd.2003.11.0172
  28. Eubank BH, Mohtadi NG, Lafave MR, Wiley JP, Bois AJ, Boorman RS, et al. Using the modified Delphi method to establish clinical consensus for the diagnosis and treatment of patients with rotator cuff pathology. *BMC Med Res Methodol* 2016;16:56. doi: 10.1186/s12874-016-0165-8
  29. Al-Sukhun S, Temin S, Chavez-MacGregor M, Denduluri N, Oliver TK, Pyle D, et al. ASCO Resource-Stratified Guidelines: Methods and Opportunities. *J Glob Oncol* 2018;4:1-8. doi: 10.1200/JGO.18.00113
  30. Mutebi M, Adewole I, Orem J, Abdella K, Coker O, Kolawole I, et al. Toward Optimization of Cancer Care in Sub-Saharan Africa: Development of National Comprehensive Cancer Network Harmonized Guidelines for Sub-Saharan Africa. *JCO Glob Oncol* 2020;6:1412-8. doi: 10.1200/GO.20.00091
  31. Amer YS, Elzababany MM, Omar TI, Ibrahim AG, Dowidar NL. The 'Adapted ADAPTE': an approach to improve utilization of the ADAPTE guideline adaptation resource toolkit in the Alexandria Center for Evidence-Based Clinical Practice Guidelines. *J Eval Clin Pract* 2015;21:1095-106. doi: 10.1111/jep.12479
  32. Brouwers MC, Kho ME, Browman GP, Burgers JS, Cluzeau F, Feder G, et al. AGREE II: advancing guideline development, reporting and evaluation in health care. *CMAJ* 2010;182:e839-42. doi: 10.1503/cmaj.090449
  33. Shiffman RN, Michel G, Rosenfeld RM, Davidson C. Building better guidelines with BRIDGE-Wiz: development and evaluation of a software assistant to promote clarity, transparency, and implementability. *J Am Med Inform Assoc* 2012;19:94-10. doi: 10.1136/amiajnl-2011-000172
  34. Enam SA, Shah MM, Bajwa MH, Khalid MU, Bakhshi SK, Baig E, et al. The Pakistan Brain Tumour Epidemiology Study. *J Pak Med Assoc* 2022;72(Suppl 4):s4-11. doi: 10.47391/JPMA.11-S4-AKUB01.
  35. Lutterbach J, Pagenstecher A, Spreer J, Hetzel A, Velthoven Vv, Nikkha G, et al. The brain tumor board: lessons to be learned from an interdisciplinary conference. *Onkologie* 2005;28:22-6. doi: 10.1159/000082124
  36. Barbaro M, Fine HA, Magge RS. Foundations of Neuro-Oncology: A Multidisciplinary Approach. *World Neurosurg* 2021;151:392-401. doi: 10.1016/j.wneu.2021.02.059
  37. Abbasi AN. Cancer management is a multidisciplinary team work. *J Coll Physicians Surg Pak* 2011;21:259-61.

#### DISCLAIMER

Articles published in JPMA and Supplements of JPMA do not represent the views of the editor or editorial Board. Authors are solely responsible for the opinions expressed and the accuracy of the data.

The contribution of each author towards the published research included in this supplement is the responsibility of the authors and their institutions. It is expected to be in accordance and compliance with the ICMJE Guidelines.

Any questions/queries raised by readers should be directed to the corresponding author.

## NARRATIVE REVIEW

## Consensus guidelines for the management of adult low-grade gliomas for low and middle-income countries

Ahsan Ali Khan<sup>1</sup>, Ayesha Akbar Waheed<sup>2</sup>, Ali Azan Ahmed<sup>3</sup>, Asim Hafiz<sup>4</sup>, Adeeba Zaki<sup>5</sup>, Ahmed Gilani<sup>6</sup>, Faiza Urooj<sup>7</sup>, Mohammad Hamza Bajwa<sup>8</sup>

**Pakistan Brain Tumour Consortium:** (Authors list at the end of the supplement), Syed Ather Enam

### Abstract

Low-grade gliomas (LGG) are brain tumors of glial cells origin. They are grade 1 and grade 2 tumors according to the WHO classification. Diagnosis of LGG is made through imaging, histopathological analysis, and use of molecular markers. Imaging alone does not establish the grade of the tumor and thus a histopathological examination of tissue is crucial in establishing the definite histopathological diagnosis. Clinical presentation varies according to the location and size of the tumor. Surgical resection is strongly recommended in LGG over observation to improve overall survival as surgery leads to greater benefit due to progression-free survival. Radiation has shown benefits in LGG patients in randomized controlled trials and chemotherapy with temozolomide has also shown good results. This paper covers the principles of low-grade gliomas management and summarizes the recommendations for the LMICs.

**Keywords:** Temozolomide, survival, brain Neoplasms, glioma, neuroglia

**DOI:** <https://doi.org/10.47391/JPMA.S3.GNO-11>

### Introduction

Brain tumors are defined upon their histopathological features and their cells of origin. Tumors arising from the glial cells of the nervous system are defined as gliomas. These tumors are further divided into astrocytoma and oligodendroglioma. The grade attributes clinical prognosis. Histological appearance and molecular markers such as isocitrate dehydrogenase (IDH), ATRX, tumor protein (TP53), 1p19q co-deletion attributes to the final diagnosis LGG in parenthesis as per WHO classification 2021.<sup>1</sup> However, recently another term 'lower-grade gliomas have been used to include grade 3 also, but we have discussed only grade 2 in this paper.

<sup>1,8,9</sup>Department of Neurosurgery, The Aga Khan University, Karachi, <sup>2,3,7</sup>The Aga Khan Medical College and University, Karachi, <sup>4</sup>Department of Radiation Oncology, The Aga Khan University, Karachi, Pakistan. <sup>5</sup>Department of Oncology, Aga Khan University Hospital, Pakistan. <sup>6</sup>Department of Pathology, University of Colorado, Children's Hospital Colorado, USA.

**Correspondence:** Syed Ather Enam **Email:** [ather.enam@aku.edu](mailto:ather.enam@aku.edu)

LGGs are glial tumors with slow growth rates and their occurrence is usually between the third and fourth decades of life. Seizures are present as the primary complaint in majority of the patients while focal neurological deficits and headaches are also common.<sup>2</sup> In most cases, LGGs exist in the high-functioning regions of the brain, in the eloquent cortical, subcortical, and the secondary functional areas of the insula and the supplemental motor areas.<sup>3</sup>

The low-grade gliomas are not necessarily benign tumors, they have the potential for malignant transformation over time, but this process is not uniform and can vary significantly from case to case. The mean time for malignant transformation of low-grade glial tumors to high-grade varies and depends on several factors, including the type of tumor, its location, genetic factors, and the patient's overall health. The timeframe of malignant transformation can range from a few years to over a decade.

The median time for this transformation is often cited in various studies, but it's essential to note that these are average figures and individual cases can vary widely. Approximately 72% of grade 2 tumors may show malignant transformation over time and hence, we recommend early surgical resection of the low-grade gliomas over "wait and see" approach. This paper covers the principles of low-grade gliomas management and summarizes the recommendations for the low-middle income countries (LMICs).<sup>4,5</sup>

### Methods

The literature search of the high-quality data on low-grade gliomas was done in March 2023 on different databases including PubMed, Google Scholar, Scopus, and Embase in March 2023. The most relevant and high-quality studies were analyzed to develop the evidence-based recommendations. An expert panel was convened consisting of specialists and leading experts within the field of neuro-oncology to identify the gaps in diagnosis and management of low-grade gliomas within Pakistan. This group was tasked with identifying best-practice recommendations and their application within the

context of Pakistan as a (LMIC). Recommendations were collated and reviewed for utility and evidence-based practices.<sup>6</sup>

### Initial evaluation

Initial diagnosis of LGGs is made through imaging, histopathological analysis and use of molecular markers. Imaging alone does not establish the grade of the tumor and thus a histopathological examination of tissue is crucial in establishing the definite histopathological diagnosis.<sup>7</sup> In Computed Tomography (CT) scans, LGGs appear as regions of low attenuation that may or may not enhance.<sup>8</sup> Meanwhile, Magnetic Resonance Imaging (MRI), both T1 and T2, are non-enhancing and sometimes minimal or subtle enhancement with calcifications appearing on high T1 and low T2 signals.<sup>9</sup> FLAIR sequence plays an important role in defining the extent and boundaries of the LGGs.

LGGs management involves factors such as the extent of surgical resection, the timing of intervention, risks associated with chemotherapy, the timing of radiotherapy, and the long-term consequences of all treatments. Therefore, the purpose of this study is to outline the difficulties faced in the provision of these aforementioned treatments and their applicability in low- and middle-income countries (LMICs), ascertaining the recent developments in the diagnostic workup of LGGs in order to establish refined treatment methods that are suitable for LMICs.

Clinical symptoms for LGGs are not consistent. Mostly symptoms are associated with mass effect from invasion into obstructive hydrocephalus or surrounding parenchyma. While some patients with LGGs may be asymptomatic, many patients present with seizures, signs of increased intracranial pressure through headache and papilledema, and cognitive changes.<sup>3, 10</sup>

### Surgical management

The main goal involved with surgery is to obtain a maximal safe resection or form a pathological diagnosis through biopsy. Developments such as tractography, preoperative functional MRIs, and intraoperative neurophysiological monitoring allow surgeons to maximize the objectives of the surgery. Moreover, in cases where safe resection is not a possibility, image guided biopsy is conducted using preoperative and intraoperative imaging to gather tissue for histopathological examination.<sup>2, 10</sup> In comparison to a needle biopsy, which has an over 50% misdiagnosis rate, surgical resection provides a far feasible avenue for characterization, grading, proper diagnosis, and treatment of LGGs.<sup>11</sup>

Recent studies have strongly suggested surgery over observation to improve overall survival as surgery leads to greater benefit due to progression-free survival.<sup>12, 13</sup> Moreover, surgical resection has also shown substantial benefits in reducing seizure<sup>14</sup> It is important to consider two factors when proceeding to a surgery, the impact on patients' quality of life (QoL) and the overall survival in comparison to monitored waiting. With the latest developments in surgical techniques, it has now become more efficient for surgeons to conduct surgeries in cases of patients with LGGs while also not affecting the eloquent brain. Through magnetic source imaging and functional MRI, surgeons can map the vital regions of the brain such as language and motor cortices.<sup>15</sup> Intraoperative MRI and MRS enable the evaluation of the degree of tumor resection, further clarifying the residual tumor whereas Diffusion Tensor Imaging allows improved surgical planning, reducing risks and deficits involved.<sup>6, 16</sup> Intra-operative ultrasonography (IOUS) has also shown benefits during surgical resection. It provides real-time guidance which plays an important role in the extent of tumor resection. In limited resources, ultrasound can be an extremely effective adjunct.<sup>17, 18</sup>

### Pathological assessment

Histopathological diagnosis is crucial in the definite management of the LGGs. The molecular pathology of low-grade gliomas involves deletion on chromosomes 1p and 19q, with significant association with oligodendrogliomas. Deletion of the 19q13.3 region is responsible for 73% of oligodendrogliomas and 38% of astrocytomas, the deletion of 1p36 region is involved in 18% of astrocytomas and 73% of oligodendrogliomas and finally, both 1p36 and 19q13.3 regions are codeleted in 64% of oligodendrogliomas, and 11% of astrocytomas.<sup>19</sup>

Moreover, overexpression and mutation of tumor protein 53 (TP53), involved in the p53 pathway, leads to diffuse astrocytomas.<sup>20</sup> Decreased MGMT activity is also found in correlation to low grade gliomas. MGMT is a DNA repair enzyme that removes alkyl groups from the O6 position of guanine.<sup>21</sup>

However, methylation of the MGMT promoter leads to increased sensitivity of gliomas to the effects of alkylating agents- most likely due to reduced activity of MGMT.<sup>22</sup>

In addition, mutations in the gene BRAF of chromosome 7 (7q34), also contribute to low grade gliomas. The BRAF gene is involved in production of a protein that activates the mitogen-activated protein kinase (MAPK) pathway.<sup>23</sup>

Finally, isocitrate dehydrogenase mutations, IDH1 and IDH2, are also found in pathogenesis of low-grade

gliomas. IDH1 and IDH1 are NADP dependent enzymes that catalyze the conversion of isocitrate to  $\alpha$ -ketoglutarate.<sup>24</sup> Mutation of IDH1 results in reduced enzymatic activity due to impaired isocitrate binding that leads to production of D-2-hydroxyglutarate (d-2HG), which then acts as an oncogenic metabolite.<sup>25,26</sup>

When looking closely into the histopathological end of the diagnosis, stains such as eosin and hematoxylin are employed for identification. Oligodendrogliomas are infiltrating cells with perinuclear clearing following a honeycomb pattern, meanwhile, astrocytomas have fibrillary neoplastic astrocytes, and oligoastrocytomas contain both types of tumor cell types.

### Adjuvant treatment radiotherapy

Radiation is one of the few intervention methods that has shown benefit in LGG patients in a randomized controlled trial.<sup>27</sup> Numerous clinical trials have been set up to discern the differences between high-dose and low-dose radiation and early postoperative radiation vs. delayed radiation at time of disease recurrence or progression. Regarding timing of RT, studies have shown better progression free survival when radiation had incorporated early after surgery as compared to delayed radiation in the management of LGG however it failed to show any benefit in term of survival.<sup>27</sup> Similarly, dose response study failed to show significant difference in both the progression-free survival and overall survival in LGG through radiation dose escalation beyond 54 Gy instead lead to more toxicity.<sup>28</sup>

Radiotherapy is put forward for management of recently diagnosed LGG in adults, to improve progression free survival regardless of the level of surgical resection (Level I recommendation). Radiotherapy is suggested for management of recently diagnosed LGG as a substitute to observation in maintaining cognitive function (Level II recommendation). Radiotherapy suggested for management of recently diagnosed LGG that involves ameliorating seizure control and prolonging progression free survival in patients with subtotal resection and epilepsy (Level III recommendation).

In case of progression free survival, it was noted that a more aggressive approach towards surgical resection combined with radiotherapy led to significantly higher levels of 5-year progression free survival rates.<sup>29</sup> Moreover, radiotherapy also showed substantial improvements in controlling seizures.<sup>30</sup>

Recent advances in radiotherapy techniques such as intensity-modulated radiation therapy (IMRT)/ Volume modulated arc therapy (VMAT) and stereotactic radiation

therapy have allowed targeting the tumor with high precision during treatment, without damaging the surrounding healthy brain tissue and hence addressing the concerned related with radiation toxicity.<sup>2,31</sup>

### Chemotherapy

Neuro-oncologists have found renewed interest in chemotherapy with specific focus on temozolomide, with its ability to cross the blood-brain barrier, heightened activity against glioblastomas and favorable toxicity profile in comparison to other available agents- leading to an improved quality of life.<sup>32</sup>

The major concern in the application of chemotherapy is should all LGG patients be provided adjuvant chemotherapy involving Procarbazine, CCNU, and Vincristine (PCV) or rather it should be specified to high-risk patients solely.<sup>33</sup> However, to follow this path, better analysis upon the differentiation of high-risk LGG must be more probed into to ensure that the cognitive decline induced by chemotherapy is minimized and limited to patients where it is of greater benefit and increased quality of life.<sup>34</sup> Therefore, a molecular analysis study was conducted to determine the benefits of adjuvant chemotherapy involving PCV chemotherapy in 1p/19q co-deleted tumors as well as in CpG Island Methylated Phenotype (CIMP) positive tumors, IDH mutations, and MGMT promoter methylation.<sup>35,36</sup>

Recent years have seen PCV being gradually replaced by temozolomide that has improved tolerance levels and is easier to administer. Even though RTOG studies have yielded similar treatment results in temozolomide, and CCNU, the latter had to be eventually discontinued due to its extreme levels of toxicity that led to a decreased survival rate.<sup>37</sup> However, a new chemotherapeutic drug vorasidenib has shown to increase progression-free survival in patients with grade 2 IDH mutant glioma.<sup>38</sup>

While decline in cognition and defining the correct set of patients to provide chemotherapy remain as the focal challenges, developments such as temozolomide remain to be proponents of chemotherapy in LGG management.

### Post-operative management and follow-up

Post-op MRI brain with and without contrast should be done within 72 hours. Clinically speaking, the extent of surgical resection is the major determinant of post-operative management and eventually the quality of life. The accurate analysis of the extent of surgical excision is reported on post-op MRI brain. Looking into the follow up aspect of LGG management, we find key metrics such as (i) physical activity, (ii) social function, (iii) cognitive function, (iv) emotions function, and (v) fatigue with

**Table-1:** Summary of Recommendations for Low-Grade Glioma.

Radiology	<ul style="list-style-type: none"> <li>• MRI brain with and without contrast.</li> <li>• ‘Minimum required’ MRI protocol:               <ul style="list-style-type: none"> <li>◦ Imaging on at least 0.5T.</li> <li>◦ Sequences: Axial T2 and coronal or axial FLAIR sequence; pre-contrast T1 and contrast enhanced T1.</li> </ul> </li> <li>• Tumor location, size, margins, enhancement pattern, and presence of hemorrhage/mineralization.</li> <li>• Postoperative MRI is recommended within 72 hours of surgery. If delayed, then an MRI should be performed after 6 weeks.               <ul style="list-style-type: none"> <li>◦ To identify the extent of resection.</li> <li>◦ To have a baseline to compare successive imaging.</li> <li>◦ Not required after biopsy.</li> </ul> </li> </ul>
Neurosurgery	<ul style="list-style-type: none"> <li>• Surgical goals: Maximal safe resection of the tumor, preferably GTR.</li> <li>• SMR should be attempted where possible with potential survival benefit.</li> <li>• Biopsy/debulking is recommended where maximal safe resection is not possible.</li> <li>• Awake resection is advised if the expertise is available.</li> </ul>
Neuropathology	<ul style="list-style-type: none"> <li>• Hematoxylin and eosin (H&amp;E) preparation to establish astrocytic or oligodendroglia lineage.</li> <li>• Distinguish low-grade glioma from high-grade gliomas based on evaluation of cytological atypia, cellularity, mitotic count, presence/ absence of necrosis and vascular proliferation.</li> <li>• Immunohistochemical stains GFAP, Olig2, IDH1 R132H, ATRX, p-53, stains stratify these tumors.</li> <li>• For diffuse glioma with morphological features of Oligodendroglioma, 1p/19q co-deletion is to be tested by FISH or refer to reference labs for the same, if not available at the same centre.</li> <li>• Consider IDH1 and IDH2 PCR testing if IHC is inconclusive for the same.</li> </ul>
Medical and Radiation Oncology	<ul style="list-style-type: none"> <li>• <b>Low risk patients:</b> (GTR &amp; Age &lt; 40 years): Observation.</li> <li>• <b>High-risk patients:</b> (STR or Age &gt; 40 years):               <ul style="list-style-type: none"> <li>◦ Radiation followed by Adjuvant PCV x 6 cycles.</li> <li>◦ CCRT with TMZ followed by monthly TMZ.</li> </ul> </li> <li>• Focal brain radiation with advanced conformal techniques such as 3DCRT/IMRT/VMAT is recommended.</li> <li>• The common radiation dose is 54 Gy in 30 fractions given at 1.8 Gy per fraction for five days a week for 6 weeks.</li> <li>• <b>Recurrent disease:</b> <ul style="list-style-type: none"> <li>◦ Temozolomide, PCV, Avastin.</li> </ul> </li> </ul>

Continued on next page...

Continued from previous page...

	<ul style="list-style-type: none"> <li>• Case needs to be discussed in a radiation oncology facility having peer review practice by site-specific specialists for consideration of re-irradiation with highly conformal techniques such as IMRT/VMAT or stereotactic radiation SRS/f-SRT</li> </ul>
Follow-up	<ul style="list-style-type: none"> <li>• First follow-up at post-op day 10 for wound assessment, stitch removal, discussion related to histopathology and NOTB recommendations.</li> <li>• The neurosurgeon needs to connect the patient with radiation and medical oncologists if needed.</li> <li>• Lifelong follow-up with MRI every 3 months for 1 year and then 6 monthly with neurosurgeon/medical oncologist.</li> <li>• Redo surgery can be considered in case of recurrence/disease progression after risk stratification in NOTB.</li> </ul>

MRI: Magnetic resonance imaging, FLAIR: Fluid-attenuated inversion recovery, GTR: Gross total resection, SMR: Supra marginal resection, GFAP: Glial fibrillary acidic protein, IDH: Isocitrate dehydrogenase, ATRX:  $\alpha$  thalassemia/mental retardation syndrome X-linked, FISH: fluorescence in situ hybridization, PCR: Polymerase chain reaction, IHC: Immunohistochemistry, STR: Subtotal resection, CCRT: Concurrent chemoradiotherapy, TMZ: Temozolomide, 3DCRT: Three-dimensional conformal radiotherapy, IMRT: Intensity-modulated radiation therapy, VMAT: Volumetric modulated arc therapy, Gy: Gray, PCV: Procarbazine, Lomustine, and Vincristine, SRS/f-SRT: Stereotactic radiosurgery/fractionated stereotactic radiation therapy, NOTB: Neuro-Oncology tumor board.

respect to time after the surgery or other treatment method.

## Prognosis

Close follow-up is advised, preferably with MRI every 3 to 6 months post-operatively. Redo surgery can be offered in case of recurrence. Several prognostic factors allude to the risk of death in patients with LGG. The size of tumor diameter being > 5cm, presence of tumor in eloquent regions of the brain, patients with preoperative KPS, and IDH non mutated/wild type tumors are the important markers of risk of death.<sup>39</sup> In addition, seizures, volume of residual tumor, delayed post-operative radiotherapy, Age, and the respective pathology (astrocytoma, oligodendroglioma/mixed) are other prognostic factors related to the 5-year and 10-year progression free rates.<sup>40</sup>

## Factors affecting optimal care

Although treatment options have expanded, as well as

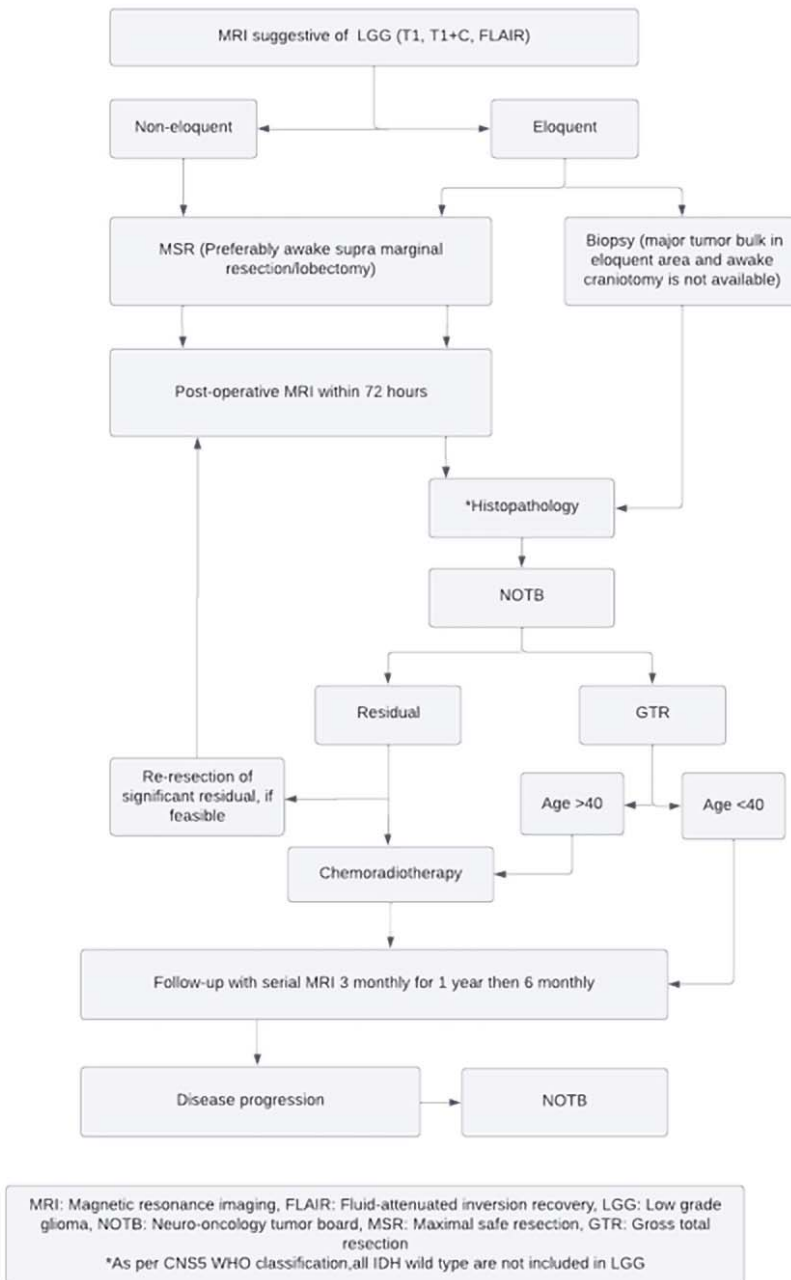
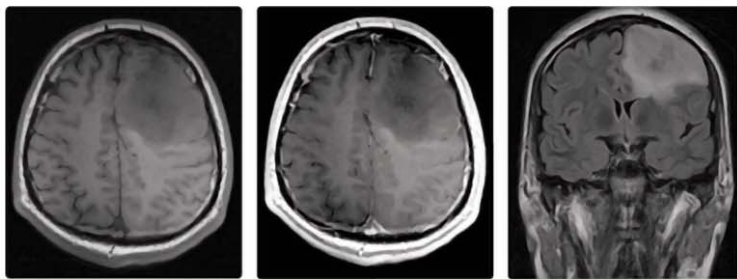


Figure-1: Management of LGG algorithm.

efforts to improve existing treatment regimes, a serious limiting factor remains in the lack of clinical follow-up. This serves as an obstacle in assessing the efficacy and effectiveness of chosen treatment plans, narrowing the pool of viable data. Many reasons behind this poor rate of follow-up are mostly situational and apply more so in the case of LMIC settings. For example, there is a dearth of tertiary care health care centers in Pakistan. In addition to coming from less affording households, patients must travel large distances to seek treatment, let alone follow-up. Moreover, treatment can be suboptimal owing to the burden of patients on a single center. The most appropriate treatment plan may not be an option for each patient. Hence, the effort in treating LGGs should not only be directed at finding the best treatment, but also eliminating the factors that affect care.

### Gaps in knowledge

With new advancements in imaging, radiotherapy, chemotherapy, and surgical techniques, the management of LGG keeps varying and it is more apt to identify the risks associated with the “wait-and-see” approach. Current data is in strong favor of surgical resection to maximize benefits, but further trials and investigations are necessary to unlock the complete potential of novel imaging techniques and molecular marker pathogenesis. However, the presence of cognitive decline, epilepsy, and insufficient health-related Quality of Life remain important issues that have to be addressed to ensure a sustainable management procedure.<sup>39 40</sup> Finally, implications concerning stereotactic biopsy and Perfusion weighted MR imaging still require further exploration to introduce them into the mainstream treatment modalities.

### Conclusion

These guidelines serve as a practical roadmap based on valuable experience

and are formulated for physicians working in resource-limited settings, (Table 1 and Figure 1). Their implementation has significant potential to improve outcomes and aims to nurture a stronger emphasis on multidisciplinary care within LMICs, such as Pakistan.

**Disclaimer:** None.

**Conflict of Interest:** None.

**Funding Disclosure:** None.

## References

- Louis DN, Perry A, Wesseling P, Brat DJ, Cree IA, Figarella-Branger D, et al. The 2021 WHO Classification of Tumors of the Central Nervous System: a summary. *Neuro Oncol* 2021;23:1231-5. doi: 10.1093/neuonc/noab106.
- Forst DA, Nahed BV, Loeffler JS, Batchelor TT. Low-grade gliomas. *Oncologist* 2014;19:403-13. doi: 10.1634/theoncologist.2013-0345.
- Duffau H, Capelle L. Preferential brain locations of low-grade gliomas. *Cancer* 2004;100:2622-6. doi: 10.1002/cncr.20297.
- Tom MC, Park DYJ, Yang K, Leyrer CM, Wei W, Jia X, et al. Malignant Transformation of Molecularly Classified Adult Low-Grade Glioma. *Int J Radiat Oncol Biol Phys* 2019;105:1106-12. doi: 10.1016/j.ijrobp.2019.08.025.
- Satar Z, Hotton G, Samandouras G. Systematic review-Time to malignant transformation in low-grade gliomas: Predicting a catastrophic event with clinical, neuroimaging, and molecular markers. *Neurooncol Adv* 2021;3:vdab101. doi: 10.1093/oaajnl/vdab101.
- Bajwa MH, Shah MM, Mustansir F, Gauhar F, Baig E, Zafar SN, et al. A Guideline On Guidelines – Neuro-Oncology Guideline Standards For Low And Middle-Income Countries. *J Pak Med Assoc* 2024;74(Suppl 3):s87-92. Doi: 10.47391/JPMA.S3.GNO-10.
- Fan GG, Deng QL, Wu ZH, Guo QY. Usefulness of diffusion/perfusion-weighted MRI in patients with non-enhancing supratentorial brain gliomas: a valuable tool to predict tumour grading? *Br J Radiol* 2006;79:652-8. doi: 10.1259/bjr/25349497.
- Pirzkall A, Nelson SJ, McKnight TR, Takahashi MM, Li X, Graves EE, et al. Metabolic imaging of low-grade gliomas with three-dimensional magnetic resonance spectroscopy. *Int J Radiat Oncol Biol Phys* 2002;53:1254-6. doi: 10.1016/s0360-3016(02)02869-9.
- Henson JW, Gaviani P, Gonzalez RG. MRI in treatment of adult gliomas. *Lancet Oncol* 2005;6:167-75. doi: 10.1016/S1470-2045(05)01767-5.
- Pouratian N, Asthagiri A, Jagannathan J, Shaffrey ME, Schiff D. Surgery Insight: the role of surgery in the management of low-grade gliomas. *Nat Clin Pract Neurol* 2007;3:628-39. doi: 10.1038/ncpneu0634.
- Muragaki Y, Chernov M, Maruyama T, Ochiai T, Taira T, Kubo O, et al. Low-grade glioma on stereotactic biopsy: how often is the diagnosis accurate? *Minim Invasive Neurosurg* 2008;51:275-9. doi: 10.1055/s-0028-1082322.
- Youland RS, Brown PD, Giannini C, Parney IF, Uhm JH, Laack NN. Adult low-grade glioma: 19-year experience at a single institution. *Am J Clin Oncol* 2013;36:612-9. doi: 10.1097/COC.0b013e31825d580a.
- Jakola AS, Myrmet KS, Kloster R, Torp SH, Lindal S, Unsgård G, et al. Comparison of a strategy favoring early surgical resection vs a strategy favoring watchful waiting in low-grade gliomas. *JAMA* 2012;308:1881-8. doi: 10.1001/jama.2012.12807.
- Chang EF, Potts MB, Keles GE, Lamborn KR, Chang SM, Barbaro NM, et al. Seizure characteristics and control following resection in 332 patients with low-grade gliomas. *J Neurosurg* 2008;108:227-35. doi: 10.3171/JNS/2008/108/2/0227.
- Pouratian N, Schiff D. Management of low-grade glioma. *Curr Neurol Neurosci Rep* 2010;10:224-31. doi: 10.1007/s11910-010-0105-7.
- Pamir MN, Ozduman K. 3-T ultrahigh-field intraoperative MRI for low-grade glioma resection. *Expert Rev Anticancer Ther* 2009;9:1537-9. doi: 10.1586/era.09.134.
- Lombardi G, Barresi V, Castellano A, Tabouret E, Pasqualetti F, Salvalaggio A, et al. Clinical Management of Diffuse Low-Grade Gliomas. *Cancers (Basel)* 2020;12:3008. doi: 10.3390/cancers12103008.
- Mitchell D, Shireman JM, Dey M. Surgical Neuro-Oncology: Management of Glioma. *Neurol Clin* 2022;40:437-53. doi: 10.1016/j.ncl.2021.11.003.
- Okamoto Y, Di Patre PL, Burkhard C, Horstmann S, Jourde B, Fahey M, et al. Population-based study on incidence, survival rates, and genetic alterations of low-grade diffuse astrocytomas and oligodendrogliomas. *Acta Neuropathol* 2004;108:49-56. doi: 10.1007/s00401-004-0861-z.
- Mineura K, Izumi I, Watanabe K, Kowada M. Influence of O6-methylguanine-DNA methyltransferase activity on chloroethylnitrosourea chemotherapy in brain tumors. *Int J Cancer* 1993;55:76-81. doi: 10.1002/ijc.2910550115.
- Preusser M, Charles Janzer R, Felsberg J, Reifenberger G, Hamou MF, Diserens AC, et al. Anti-O6-methylguanine-methyltransferase (MGMT) immunohistochemistry in glioblastoma multiforme: observer variability and lack of association with patient survival impede its use as clinical biomarker. *Brain Pathol* 2008;18:520-32. doi: 10.1111/j.1750-3639.2008.00153.x.
- Dhomen N, Marais R. New insight into BRAF mutations in cancer. *Curr Opin Genet Dev* 2007;17:31-9. doi: 10.1016/j.gde.2006.12.005.
- Xu X, Zhao J, Xu Z, Peng B, Huang Q, Arnold E, et al. Structures of human cytosolic NADP-dependent isocitrate dehydrogenase reveal a novel self-regulatory mechanism of activity. *J Biol Chem* 2004;279:33946-57. doi: 10.1074/jbc.M404298200.
- Zhao S, Lin Y, Xu W, Jiang W, Zha Z, Wang P, et al. Glioma-derived mutations in IDH1 dominantly inhibit IDH1 catalytic activity and induce HIF-1alpha. *Science* 2009;324:261-5. doi: 10.1126/science.1170944.
- Dang L, White DW, Gross S, Bennett BD, Bittinger MA, Driggers EM, et al. Cancer-associated IDH1 mutations produce 2-hydroxyglutarate. *Nature* 2009;462:739-44. doi: 10.1038/nature08617.
- Dhawan S, Patil CG, Chen C, Venteicher AS. Early versus delayed postoperative radiotherapy for treatment of low-grade gliomas. *Cochrane Database Syst Rev* 2020;1:CD009229. doi: 10.1002/14651858.CD009229.pub3.
- Schomas DA, Laack NN, Rao RD, Meyer FB, Shaw EG, O'Neill BP, et al. Intracranial low-grade gliomas in adults: 30-year experience with long-term follow-up at Mayo Clinic. *Neuro Oncol* 2009;11:437-45. doi: 10.1215/15228517-2008-102.
- Barcia JA, Barcia-Salorio JL, Ferrer C, Ferrer E, Algás R, Hernández G. Stereotactic radiosurgery of deeply seated low grade gliomas. *Acta Neurochir Suppl* 1994;62:58-61. doi: 10.1007/978-3-7091-9371-6\_12.
- Scerrati M, Montemaggi P, Iacoangeli M, Roselli R, Rossi GF. Interstitial brachytherapy for low-grade cerebral gliomas: analysis of results in a series of 36 cases. *Acta Neurochir (Wien)* 1994;131:97-10. doi: 10.1007/BF01401459.
- Kahlenberg CA, Fadul CE, Roberts DW, Thadani VM, Bujarski KA, Scott RC, et al. Seizure prognosis of patients with low-grade



- tumors. *Seizure* 2012;21:540-5. doi: 10.1016/j.seizure.2012.05.014.
31. Correa DD, DeAngelis LM, Shi W, Thaler HT, Lin M, Abrey LE. Cognitive functions in low-grade gliomas: disease and treatment effects. *J Neurooncol* 2007;81:175-84. doi: 10.1007/s11060-006-9212-3.
  32. Dhermain FG, Hau P, Lanfermann H, Jacobs AH, van den Bent MJ. Advanced MRI and PET imaging for assessment of treatment response in patients with gliomas. *Lancet Neurol* 2010;9:906-20. doi: 10.1016/S1474-4422(10)70181-2.
  33. van den Bent MJ. Chemotherapy for low-grade glioma: when, for whom, which regimen? *Curr Opin Neurol* 2015;28:633-98. doi: 10.1097/WCO.0000000000000257.
  34. Wick W, Meisner C, Hentschel B, Platten M, Schilling A, Wiestler B, et al. Prognostic or predictive value of MGMT promoter methylation in gliomas depends on IDH1 mutation. *Neurology* 2013;81:1515-22. doi: 10.1212/WNL.0b013e3182a95680.
  35. Kaloshi G, Benouaich-Amiel A, Diakite F, Taillibert S, Lejeune J, Laigle-Donadey F, et al. Temozolomide for low-grade gliomas: predictive impact of 1p/19q loss on response and outcome. *Neurology* 2007;68:1831-6. doi: 10.1212/01.wnl.0000262034.26310.a2.
  36. Chang S, Zhang P, Cairncross JG, Gilbert MR, Bahary JP, Dolinskas CA, et al. Phase III randomized study of radiation and temozolomide versus radiation and nitrosourea therapy for anaplastic astrocytoma: results of NRG Oncology RTOG 9813. *Neuro Oncol* 2017;19:252-8. doi: 10.1093/neuonc/now236.
  37. Brown TJ, Bota DA, van Den Bent MJ, Brown PD, Maher E, Aregawi D, et al. Management of low-grade glioma: a systematic review and meta-analysis. *Neurooncol Pract* 2019;6:249-58. doi: 10.1093/nop/npy034.
  38. Mellinghoff IK, van den Bent MJ, Blumenthal DT, Touat M, Peters KB, Clarke J, et al. Vorasidenib in IDH1- or IDH2-Mutant Low-Grade Glioma. *N Engl J Med* 2023;389:589-601. doi: 10.1056/NEJMoa2304194.
  39. Leighton C, Fisher B, Bauman G, Depiero S, Stitt L, MacDonald D, et al. Supratentorial low-grade glioma in adults: an analysis of prognostic factors and timing of radiation. *J Clin Oncol* 1997;15:1294-301. doi: 10.1200/JCO.1997.15.4.1294.
  40. Klein M, Engelberts NH, van der Ploeg HM, Kasteleijn-Nolst Trenité DG, Aaronson NK, Taphoorn MJ, et al. Epilepsy in low-grade gliomas: the impact on cognitive function and quality of life. *Ann Neurol* 2003;54:514-20. doi: 10.1002/ana.10712.

---

#### DISCLAIMER

Articles published in JPMA and Supplements of JPMA do not represent the views of the editor or editorial Board. Authors are solely responsible for the opinions expressed and the accuracy of the data.

The contribution of each author towards the published research included in this supplement is the responsibility of the authors and their institutions. It is expected to be in accordance and compliance with the ICMJE Guidelines.

Any questions/queries raised by readers should be directed to the corresponding author.

## Consensus guidelines for the management of adult high-grade gliomas for low- and middle-income countries

Syed Ather Enam<sup>1</sup>, Hafiza Fatima Aziz<sup>2</sup>, Saqib Kamran Bakhshi<sup>3</sup>, Ahmed Altaf<sup>4</sup>, Kaynat Siddiqui<sup>5</sup>, Asim Hafiz<sup>6</sup>, Adeeba Zaki<sup>7</sup>, Muhammad Osama<sup>8</sup>, Ahmed Gilani<sup>9</sup>,

**Pakistan Brain Tumour Consortium:** Authors list at the end of the supplement

### Abstract

High-grade glioma (HGG), a formidable and often incurable disease, presents an even greater challenge in low- and middle-income countries (LMICs) where resources and medical expertise are scarce. This scarcity not only exacerbates the suffering of patients but also contributes to poorer clinical outcomes. Particularly in LMICs, the underrepresentation of the population in clinical trials and the additional hurdles posed by financial constraints underscore an urgent need for context-specific management strategies. In response, we have rigorously evaluated recent guidelines from leading medical societies, adapting them to suit the specific needs and limitations of the local context in Pakistan. This effort, undertaken in collaboration with local physicians, aims to provide a comprehensive, standardised approach to diagnose, treat, and follow-up with HGG patients. By focussing on the best available clinical evidence and judicious use of limited resources, we strive to improve patient care and outcomes in these challenging settings.

**Keywords:** Patient care, societies, medical, physicians, glioma, brain tumour,

**DOI:** <https://doi.org/10.47391/JPMA.S3.GNO-12>

### Introduction

Gliomas account for about 80% of all central nervous system (CNS) and malignant brain tumours.<sup>1</sup> These tumours are further divided into astrocytoma and oligodendroglioma. The grade attributes clinical prognosis. Histologically, an increased proliferative index, anaplasia, necrosis, and microvascular proliferation delineate high (3 or 4) from low (1 or 2) grade glioma as per WHO 2021 classification.<sup>2</sup> Molecular analysis for isocitrate dehydrogenase (IDH), TERT promoter

<sup>1-5</sup>Department of Neurosurgery, The Aga Khan University, Karachi, Pakistan.

<sup>6-7</sup>Department of Oncology, Aga Khan University Hospital, Pakistan. <sup>8</sup>Dr. Ruth K. M. Pfau, Civil Hospital Karachi, Pakistan. <sup>9</sup>Department of Pathology, University of Colorado, Children's Hospital Colorado, USA.

**Correspondence:** Syed Ather Enam **Email:** [ather.enam@aku.edu](mailto:ather.enam@aku.edu)

mutations, EGFR gene amplification, and combined gain of entire chromosome 7 and loss of entire chromosome 10 have recently been incorporated for the grading system.<sup>3</sup>

High-grade glioma (HGG) is the most common primary CNS tumour, with an annual incidence ranging from 5-10 per 100 000 populations.<sup>4-5</sup> Incidence increases with age; the mean age for grade 3 gliomas is 40 to 64 years, while grade 4 is more common in the elderly aged 75 to 84 years.<sup>5-6</sup> Over the last decade, the understanding of HGG, primarily due to the widespread use of next-generation sequencing, has led to the evolution of diagnostic and therapeutic recommendations.<sup>7</sup> Although minuscule but progressively increased survival is attributed to the implementation of the Stupp regimen that serves to be the current standard of care.<sup>8,9</sup>

The survival outcome of HGG in low to middle-income countries (LMICs) is comparable to those in high-income countries (HICs).<sup>10</sup> However, the limited literature, absence of clinical trials, and high treatment costs highlight the health care disparities that exist on practical grounds. A significant number of individuals forgo seeking medical care at various stages, including before seeking care, during treatment and after treatment, which contributes to a substantial proportion of dropouts, skewing the reported outcome. It is ascribed to a lack of awareness, delayed medical attention, prolonged waiting time, lack of specialised facilities, and financial constraints.<sup>11-15</sup> These limitations, along with a lack of consensus among physicians regarding the treatment algorithm, potentiate the fallout.

The dire need for practical guidelines that could include LMICs' limitations without significantly compromising the outcome, is the way forward for managing HGG. We proposed these guidelines by incorporating the most up-to-date evidence-based practices and reflecting the unique challenges faced by patients and healthcare providers.

## Methodology

The literature search of the high-quality data on high-grade gliomas was done on different databases including PubMed, Google Scholar, Scopus, and Embase. The most relevant and high-quality studies were analyzed to develop the evidence-based recommendations. An expert panel was convened consisting of specialists and leading experts within the field of neuro-oncology to identify the gaps in diagnosis and management of HGG within Pakistan. This group was tasked with identifying best-practice recommendations and their application within the context of Pakistan as an LMIC. Recommendations were collated, reviewed, and debated regarding utility and evidence-based practices in a process that has been previously detailed.<sup>16</sup>

## Initial evaluation

Clinical presentation of brain tumours varies, with symptoms ranging from headache to neurological deficits, depending on tumour location, size, and disease extent. The most common symptoms include headache (50-60%), seizures (20-50%), and focal neurological deficits (20-40%) such as memory dysfunction, motor weakness, visual impairment, speech deficit, and cognitive or personality changes.<sup>1,17-19</sup> A comprehensive physical, neurological, and systemic examination is crucial. Factors like being elderly, rapid disease progression, short disease history, and complicating conditions such as an immunocompromised state or a history of cancer are important in differential diagnosis, potentially indicating conditions like metastasis, lymphoma, or bacterial and fungal abscesses. In LMICs, where cost is a major concern, thorough history-taking and clinical examination are key in guiding diagnostic investigations.

MRI is the gold standard for diagnosing HGG. The standard MRI protocol for brain tumours includes T1 and T2-weighted, fluid-attenuated inversion recovery (FLAIR) sequences, with and without gadolinium-based contrast.<sup>20</sup> HGGs are hypointense on T1 and show heterogeneous post-contrast enhancement, while being hyperintense on T2 and FLAIR sequences, regardless of histological grade. Glioblastomas typically exhibit central necrosis with irregular rim enhancement, while oligodendrogliomas may have internal calcification. HGGs often cross the midline, especially glioblastomas. Advanced imaging techniques like diffusion-weighted imaging (DWI), Apparent diffusion coefficient (ADC), perfusion scans, and MR spectroscopy provide additional information but usually don't alter management plans significantly, making them optional for cost containment. These features are crucial in challenging diagnoses, such

as differentiating recurrence from radiation necrosis or distinguishing HGGs from abscesses or lymphomas.

In cases of suspected HGG, a multidisciplinary approach is essential for management. In LMICs, however, such multidisciplinary teams and tumour boards are often lacking. Surgeons typically receive initial referrals. Relevant history and imaging usually help rule out other differentials like metastatic lesions, making surgical excision the primary intervention. For complex cases, consultation with a Neuro-Oncology Tumour Board (NOTB) is advised before surgery. Post-surgery, cases should be discussed in the NOTB, involving a team of neurosurgeons, neuroradiologists, oncologists, and palliative care physicians. This multidisciplinary discussion is vital for a holistic approach to improve patient outcomes.

## Management

Quality of life, overall survival, and progression-free survival are key outcomes in HGG treatment. In LMICs, the quality of life is especially critical due to financial constraints and limited healthcare resources, impacting both patients and the wider community. Treatment strategies in LMICs need to address these challenges when dealing with incurable diseases.

The typical treatment for HGGs involves maximal safe tumour resection followed by chemoradiotherapy. However, in LMICs, factors like low literacy, underdeveloped healthcare systems, and economic issues often lead to delayed medical intervention. Many patients present at advanced disease stages where effective surgery is not feasible, or they have comorbidities complicating treatment. While age is a known predictor of poor outcomes<sup>21</sup>, recent surgical advancements are improving prospects for older patients, though these are less evident in LMICs.<sup>22</sup> Here, a conservative approach focussing on quality of life is often preferred over treatments offering minimal survival benefit. For such patients, alternative or palliative care may be more suitable.

Surgical intervention decisions for HGG patients should be based on a multifactorial assessment. Important considerations include Karnofsky Performance Status/Eastern Cooperative Oncology Group (ECOG) performance score, tumour location and extent, and patient frailty. This approach aims to balance survival extension with quality of life maintenance, a crucial consideration in resource-limited settings.

## Surgical adjuncts

The field of glioma surgery has advanced significantly in

recent years with the development of surgical adjuncts and microsurgical techniques. These advancements have allowed for the maximal safe resection of tumours while minimizing morbidity by preserving eloquent areas. Neuronavigation, functional MRI, tractography, intraoperative MRI and ultrasound, somatosensory evoked potentials, electrocorticography, and fluorescence-guided resections, are readily available in specialized Centers and, when combined with awake craniotomy, have added a new milestone in glioma surgery. However, the availability of these advanced surgical tools remains limited in LMICs, primarily due to their high cost. Therefore, it is strongly recommended that centres catering to neuro-oncology cases in LMICs equip themselves with at least any affordable magnification (preferably a microscope), intraoperative ultrasound, and an anaesthesia team capable of performing an awake craniotomy. The implementation of these tools in LMICs could lead to several benefits, including reduced hospital stays and overall costs.<sup>23-24</sup> Additionally, the use of these surgical adjuncts and microsurgical techniques, in conjunction with awake craniotomy, allows for early postoperative neurological evaluation, speedy recovery, and minimized hospital stay, making it particularly beneficial in developing countries.<sup>23, 25, 26</sup> By broadening the extent of maximal safe resection while minimizing morbidity, these tools have the potential to significantly improve outcomes for patients with gliomas in LMICs

### **Surgical objective**

The objectives of surgical intervention are:

1. Cytoreduction
2. Relieving of mass effect and reduction of ICP
3. Obtain adequate tissue for histopathological and molecular analysis

Overall survival (OS) and progression-free survival (PFS) of the patients with HGG correlate with the extent of resection.<sup>27</sup> Resection of at least 97% of the lesion or more tends to increase the overall survival.<sup>28</sup> The concept of supra-marginal resection (SMR) has recently been popularized over gross total resection in low-grade glioma, however, in HGG the evidence is still evolving.<sup>29</sup> However, the importance of preserving eloquent areas and hence the functional capacity of an individual dictates the extent of resection.

With the use of basic surgical adjuncts like navigation systems and ultrasound, along with deep anatomical knowledge and capacity for awake craniotomy, outcomes are comparable in terms of the extent of resection, quality

of life, and overall survival.<sup>30, 31</sup> A neurosurgeon working in an LMIC must be trained enough to predict the extent of resection considering the location of the lesion and hence the goal of surgery. Immediate post-op MRI is obligatory to document the extent of resection, and intra-operative assessment is often overestimated and should not be considered. We recommend maximum safe resection of the lesion.

### **Supra marginal resection (SMR)**

Gross total resection of enhancing lesions along with any resection of non-contrast-enhanced disease is referred to as SMR.<sup>32</sup> SMR may be considered in cases where the lesion is small and situated in non-eloquent areas of the brain. Right frontal and right anterior temporal lesions are identified as non-eloquent areas amenable to SMR.<sup>31</sup> A number of methods have been identified such as resection of FLAIR signals beyond enhancing areas, anatomical resection through normal white matter, and fluorescence-guided resection beyond gross tumour visualization.<sup>32</sup> SMR for glioblastoma GBM has been established as a crucial approach that provides a significant overall and progression-free survival advantage to eligible patients.<sup>29, 33, 34</sup>

### **Gross total resection (GTR)**

It is defined as the complete excision of a contrast-enhancing lesion. GTR is an ideal extent of resection in a significant number of patients. The literature highlights the crucial role of GTR as a favourable prognostic factor, independent of other factors that can affect the patient's outcome. This finding has been consistently reported in several other series in the relevant literature.<sup>35</sup>

### **Partial resection (PR)**

Any resection more than a biopsy but not achieving GTR is considered PR. GTR is not advised in lesions involving eloquent areas, major white matter tracts, and deep brain nuclei, hence maximum safe resection is an ideal approach for such lesions. Partial resection, irrespective of the size of the residual lesion, does increase overall survival.<sup>36</sup> This effect is subtle, only adding a few months in HGG compared to LGG. With molecular advancement and their role in glioma outcome, partial resection is linked with better overall survival in patients with MGMT-unmethylated IDH-wild type glioblastoma compared to biopsy alone.<sup>37</sup>

### **Biopsy**

In patients with extensive, multicentric, or multifocal disease, advanced age, poor functional status, and high surgical risk, a biopsy is a recommended course of action. However, it is crucial to minimize potential sampling

errors. Typically, a biopsy is planned for contrast enhancing areas. Extent of resection, presenting KPS, age, MGMT methylation status all play a significant role in the outcome of multifocal glioblastoma.<sup>38</sup>

### Post-operative follow-up

First post-op MRI with and without contrast is recommended within 72 hours of surgery for any extent of intra-op resection.<sup>39</sup> This is meant to distinguish post-surgical contrast enhancement from residual tumour and serves as a baseline for future disease progression and response to adjuvant therapy. Lesions where only a biopsy was taken, do not require immediate post-op MRI. The extent of resection on post-op MRI in high-grade glioma is distinguished with contrast enhancement. However, tumour cells are infiltrated beyond contrast-enhancing boundaries and FLAIR hyperintensities are as important and need to be followed.<sup>40,41</sup> The cost of MRI is a potential factor and its significance has frequently been overshadowed in comparison to the cost. The potential of low field MRI can be explored as a cost cutting strategy specially in LMICs.<sup>42</sup>

Lost-to-follow-up; is one of the major dilemmas in the management of tumour patients in LMICs. Surgeons, as the first in line for patients' care, need to take responsibility till the oncologist takes over. All patients must be presented to the NOTB within a week of surgery.

### Histopathology

Histopathology is essential in oncology diagnostics and management, including determining chemo and radiotherapy strategies. Surgeons must correctly handle biopsy or resection specimens, typically placing them in 10% formalin and promptly sending them to the pathology lab at room temperature. These specimens, ideally no less than 0.5 cubic cm, undergo various processing steps like dehydration, de-rigidification, and staining with Haematoxylin and Eosin (H&E) preparation. A separate fresh specimen can be sent for intraoperative consultation. Pathologists provide rapid assessments within 20-30 minutes, identifying specimen adequacy and characterizing the tumour type, aiding in immediate surgical decision-making.

Tumour grading involves evaluating mitotic rate, necrosis, and microvascular proliferation. Specific criteria vary by tumour type; for instance, oligodendroglioma needs over 5 mitoses per 10 High-Power Fields (HPFs) for a grade 3 designation, unlike astrocytoma which requires fewer mitoses. Following morphological analysis, immunohistochemical stains are used to determine lineage (like astrocytoma vs. oligodendroglioma using ATRX and P53 stains), proliferation rate (using Ki67/MIB1

stain), and oncogenic drivers (IDH1,2, H3 K27M, BRAF V600E, etc.). These biomarkers are crucial in diagnosis and prognosis determination.

While next-generation sequencing and DNA methylation analysis are gold standards in molecular tumour analysis, they remain expensive and less accessible, particularly in low- and middle-income countries (LMICs). Immunohistochemical surrogates for molecular alterations, such as IDH1 R132H, BRAF V600E, H3 K27M, and H3 G34R/V, are used instead, boasting over 90% sensitivity and specificity and utilizing existing lab infrastructure.<sup>43</sup> Additionally, markers for mismatch repair (MMR) genes can identify MMR in over 80% of cases of Lynch syndrome and constitutional mismatch repair defect.<sup>44</sup> The adoption of these surrogate markers is recommended until more affordable molecular techniques are widely available.

### Adjuvant treatment

Concurrent chemoradiotherapy (CCRT) is essential in managing high-grade gliomas (HGG). To mitigate the risk of residual disease and recurrence, it's recommended to start chemoradiotherapy within 6 weeks post-surgery. Initiating treatment earlier than 3 weeks may be harmful. Thus, a 6-week delay is advised.<sup>45,46</sup>

The standard protocol involves administering radiotherapy (XRT) with concurrent Temozolomide (TMZ), followed by monthly TMZ cycles from day 1 to 5 every 28 days, continuing until disease progression or the onset of unacceptable toxicities. Post-gross total resection (GTR), adjuvant TMZ for 6 months is advised for glioblastoma, as per the Stupp trial. For Grade III Oligodendroglioma or Astrocytoma, adjuvant monthly TMZ is recommended for 12 months.<sup>47</sup> Alternatively, a PCV (Procarbazine, Lomustine, and Vincristine) regimen can be used, though it's associated with recurrent cytopenia and increased hospital visits, adding financial strain. TMZ is generally easier to administer and better tolerated.

In low- and middle-income countries (LMICs), the choice of regimen should prioritize the availability and cost-effectiveness of chemotherapeutic agents. Physicians must also be vigilant about drug quality due to often inadequate drug regulation. During CCRT with TMZ, the risk of pneumocystis pneumonia is increased due to selective lymphopenia; therefore, antimicrobial prophylaxis with Septran DS is recommended. Patient compliance and baseline health are also important considerations. Prerequisites for therapy include<sup>48</sup>:

- ANC > 1.5 x 10<sup>9</sup>/L
- PLT > 100 x 10<sup>9</sup>/L

**Table-1:** Summary of Recommendations for High-Grade Gliomas

<b>Radiology</b>	<ul style="list-style-type: none"> <li>• ‘Minimum required’ MRI protocol:               <ul style="list-style-type: none"> <li>o Imaging on at least 0.5T.</li> <li>o Sequences: Axial T2 and coronal or axial FLAIR sequence; pre-contrast T1 and contrast-enhanced T1.</li> </ul> </li> <li>• Tumor location, tumor margins, enhancement pattern, tumor size, edema and presence of hemorrhage/mineralization.</li> <li>• ADC and DWI: Helpful to rule out differential diagnoses such as abscess, if needed.</li> <li>• Postoperative MRI is recommended within 72 hours of surgery. If delayed, then an MRI should be performed after 6 weeks.               <ul style="list-style-type: none"> <li>o To identify the extent of resection.</li> <li>o To have a baseline to compare successive imaging.</li> <li>o Not required after biopsy.</li> </ul> </li> <li>• Systemic workup if suspecting a metastatic lesion.</li> <li>• Based on radiological features, early coordination with the radiation oncologist for registration can potentially reduce delays in post-op radiation therapy in high-volume centers.</li> </ul>
<b>Surgery</b>	<ul style="list-style-type: none"> <li>• SMR: Excision beyond contrast enhancement; achievable in localized lesions in non-eloquent areas, with potential survival benefit.</li> <li>• GTR: Excision of all contrast-enhancing parts; a benchmark for the extent of resection.</li> <li>• STR/debulking: In eloquent areas where GTR is not possible.</li> <li>• Biopsy: Extensive disease or locations with high surgical risks.</li> <li>• Awake resection is advised if expertise is available.</li> </ul>
<b>Neuropathology</b>	<ul style="list-style-type: none"> <li>• Hematoxylin and eosin (H&amp;E) preparation for               <ul style="list-style-type: none"> <li>o Establish astrocytic or oligodendroglia lineage.</li> <li>o Distinguish low-grade glioma from high-grade gliomas based on evaluation of cytological atypia, cellularity, mitotic count, presence/ absence of necrosis and vascular proliferation.</li> </ul> </li> <li>• Immunohistochemical stains GFAP, Olig2, IDH1 R132H, ATRX,               <ul style="list-style-type: none"> <li>o p-53, stains stratify these tumors.</li> </ul> </li> <li>• For diffuse glioma with morphological features of Oligodendrogloma, 1p/19q co-deletion is to be tested by FISH or refer to reference labs for the same, if not available at the same centre.</li> <li>• Consider IDH1 and IDH2 PCR testing if IHC is inconclusive for the same.</li> </ul>

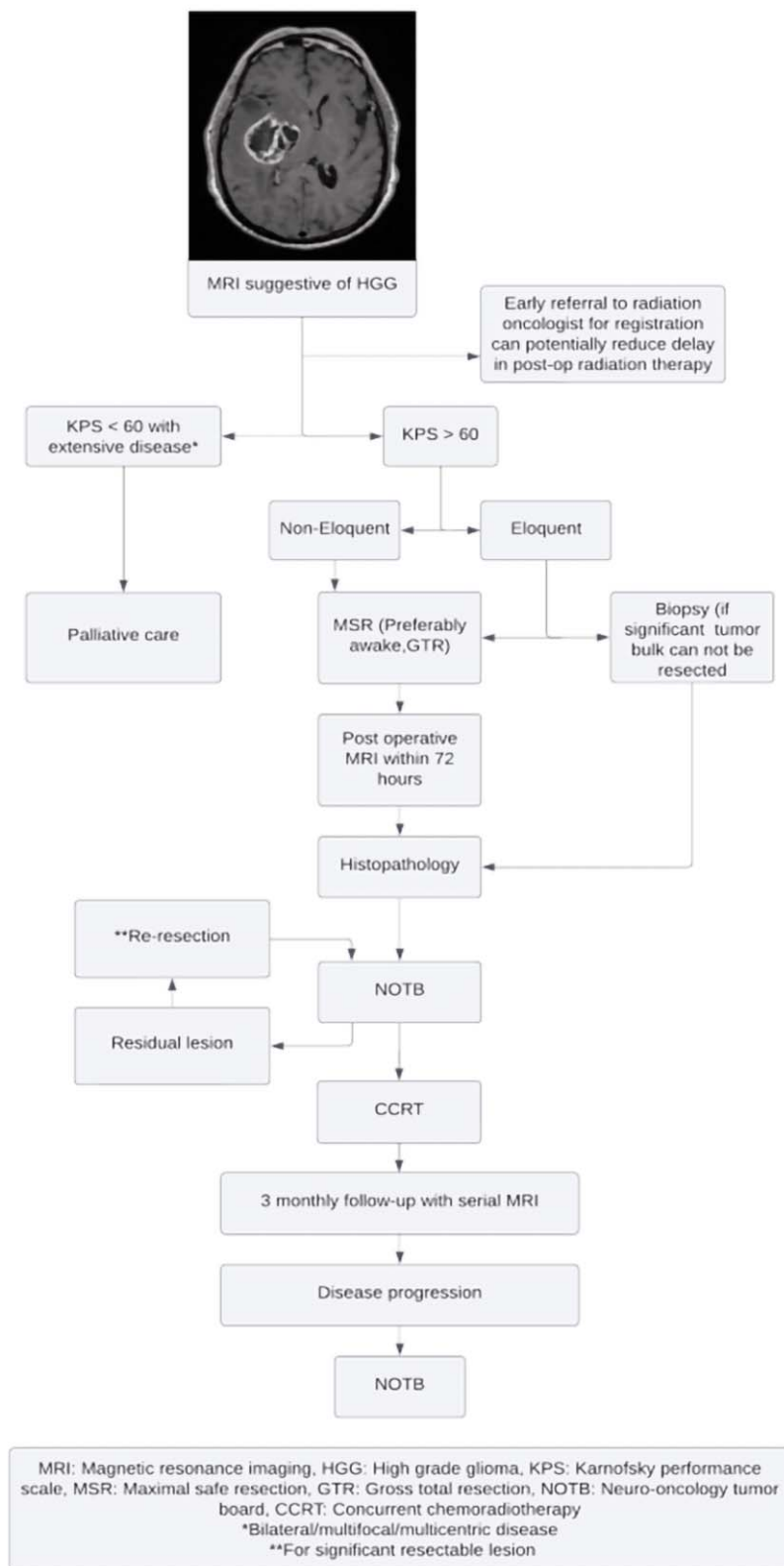
Continued on next page...

Continued from previous column...

<b>Medical and Radiation Oncology</b>	<ul style="list-style-type: none"> <li>• Focal brain irradiation therapy with concomitant chemotherapy TMZ (75mg/m<sup>2</sup>) within six weeks after surgery is recommended, followed by monthly TMZ (150-200mg/m<sup>2</sup>).</li> <li>• Conformal radiation techniques, such as 3DCRT or IMRT/VMAT, are recommended for focal brain irradiation.</li> <li>• The recommended radiation dosage is 59.4-60 Gy in 30-33 fractions given at 1.8-2 Gy per fraction for five days a week for 6-6.5 weeks.</li> <li>• Peer review of radiation treatment plans by site-specific specialists is an integral and essential component of quality assurance and should be a part of radiation therapy services to improve patient care.</li> <li>• In case of GTR:               <ul style="list-style-type: none"> <li>o Glioblastoma: Adjuvant monthly TMZ for 6 months.</li> <li>o Oligodendrogloma GIII/ Astrocytoma GIII/ /Astrocytoma GIV: Adjuvant monthly TMZ for 12 months.</li> </ul> </li> <li>• In case of STR or biopsy:               <ul style="list-style-type: none"> <li>o Monthly TMZ will be continued until disease progression or unacceptable toxicities.</li> <li>o PCV can be considered in Oligodendrogloma, but TMZ is easy to administer and has better patient tolerance.</li> </ul> </li> </ul>
<b>Follow-up</b>	<ul style="list-style-type: none"> <li>• First follow-up at post-op day 10 for wound assessment, stitch removal, discussion related to histopathology and NOTB recommendations.</li> <li>• The neurosurgeon needs to connect the patient with radiation and medical oncologists.</li> <li>• Lifelong follow-up with MRI 3 monthly with medical oncologist/neurosurgeon.</li> <li>• Redo surgery can be considered in case of recurrence/disease progression after risk stratification in NOTB.</li> </ul>

MRI: Magnetic resonance imaging, FLAIR: Fluid-attenuated inversion recovery, ADC: Apparent diffusion coefficient, DWI: Diffusion-weighted imaging, SMR: Supra marginal resection, GTR: Gross total resection, STR: Subtotal resection, GFAP: Glial fibrillary acidic protein, IDH: Isocitrate dehydrogenase, ATRX:  $\alpha$  thalassemia/mental retardation syndrome X-linked, FISH: fluorescence in situ hybridization, PCR: Polymerase chain reaction, IHC: Immunohistochemistry, TMZ: Temozolomide, 3DCRT: 3-dimensional conformal radiation therapy, IMRT: Intensity-modulated radiation therapy, VMAT: Volumetric modulated arc therapy, Gy: Gray, PCV: Procarbazine, Lomustine, and Vincristine, NOTB: Neuro-oncology tumor board

- Serum creatinine  $\leq 1.5$  times the upper limit of normal
- Total bilirubin  $\leq 1.5$  times the upper limit of normal
- AST/ALT  $< 3$  times the upper limit of normal



**Figure-1:** Management of HGG algorithm.

TMZ should be administered at 75 mg/m<sup>2</sup>/day from the start of XRT until its last day. 8 After 4 weeks of CCRT, monthly TMZ cycles should begin, and for PCV, each cycle should be repeated every 6-8 weeks. TMZ dosage is 150-200 mg/m<sup>2</sup>/day for 1-5 days every 28 days.<sup>8</sup>

The regimens are as follows<sup>49</sup>:

- Glioblastoma with GTR: 6 cycles of monthly TMZ
- Grade 3 Oligodendroglioma with GTR: 12 cycles of monthly TMZ
- High-grade Oligodendroglioma with PCV: 6 cycles

Due to their vascular nature, HGGs are sometimes treated with bevacizumab alongside radiation and TMZ. This improves progression-free survival but doesn't significantly impact overall survival and carries increased toxicity risks, limiting its routine use in newly diagnosed glioblastoma patients.<sup>50</sup>

Monitoring during treatment should include<sup>51</sup>:

- MRI brain with contrast 6-8 weeks post-CCRT, then every 3 months during monthly TMZ or earlier if symptomatic.
- CBC with differentials and serum creatinine every two weeks during CCRT and before each monthly cycle.
- Liver Function Tests before each monthly TMZ cycle.
- Weekly neurological exams.

For all HGGs, conformal radiation therapy at 1.8-2 Gy/fraction/day, 5 days a week to a total dose of 59.4-60 Gy over 30-33 fractions in 6-6.5 weeks is recommended.<sup>8</sup> In elderly patients or those with low performance status, hypo-fractionated radiation regimens may be considered.<sup>8</sup>

### Recurrent high-grade glioma

HGG carries a poor prognosis, despite optimal standard treatment; nearly all cases of high-grade glioma progress.

Repeat surgery, alternate chemotherapeutic agents and in certain cases re-radiation can be considered in a select subset of patients. Surgery remains the mainstay treatment in recurrent HGG.<sup>52-53</sup> However, our experience does not align with existing literature and carries guarded prognosis.

Second-line chemotherapy Includes: Bevacizumab, Temozolomide re-challenge, PCV. High-Grade gliomas are highly vascular tumours with noteworthy angiogenesis, an anti-angiogenetic agent such as bevacizumab can be used in recurrent disease. Bevacizumab can be used alone or in combination with irinotecan.<sup>8</sup> This therapy has been shown to increase overall survival and progression-free survival in various phase II and phase III trials. The usual dosage is 10mg/kg every 14 days for every 28 days' cycle.<sup>51</sup> The available options with doses are as follows;

1. TMZ: The recommended dose for TMZ is 150-200 mg/m<sup>2</sup>/day, from day 1 till day 5, for every 28 days until disease progression or unacceptable toxicity.<sup>8,54</sup>

2. Bevacizumab: BVC can be given alone or in combination with irinotecan.<sup>51,55</sup> The recommended dose of BVC is 10 mg/kg every 2 or 3 weeks until disease progression. Irinotecan can be administered at a dose of 125 mg/m<sup>2</sup> every 2 or 3 weeks.<sup>51</sup> If the patient is on enzyme-inducing antiepileptics drugs dose of irinotecan should be increased to 340mg/m<sup>2</sup>

3. PCV combination regimen can be used if a patient progress on TMZ and Bevacizumab combination.

The role of re-irradiation in the management of recurrent HGG is evolving. A multidisciplinary approach is mandatory for appropriate patient selection considering disease-free intervals from previous treatment, performance status, and the biological nature of the tumour. Peer review treatment planning, and previous radiation treatment details including but not limited to dose to the surrounding normal structures, mode of delivery, patient tolerance and current disease volume are essential components required for the re-irradiation decision-making process.<sup>56</sup> The optimal dose fractionation regimen remains unclear and further research is needed to strategize the management of this patient.

The recurrence sets in with the financial and emotional exhaustion of the patient as well as family. Added survival of a few months must calculate the risk based on several poor prognostic factors such as age, performance status, ependymal involvement and last but not the least indispensable use of limited finance.

## Conclusion

Formulated for physicians working in resource-limited settings, these guidelines serve as a practical roadmap based on valuable experience (Table 1 and Figure 1). Their implementation has significant potential to improve focused outcomes and aims to nurture a stronger emphasis on multidisciplinary care within LMICs, such as Pakistan.

**Disclaimer:** None.

**Conflict of Interest:** None.

**Funding Disclosure:** None.

## References

1. Weller M, Wick W, Aldape K, Brada M, Berger M, Pfister SM, et al. Glioma. *Nat Rev Dis Primers* 2015;1:15017. doi: 10.1038/nrdp.2015.17.
2. Louis DN, Perry A, Wesseling P, Brat DJ, Cree IA, Figarella-Branger D, et al. The 2021 WHO Classification of Tumors of the Central Nervous System: a summary. *Neuro Oncol* 2021;23:1231-51. doi: 10.1093/neuonc/noab106.
3. Brat DJ, Aldape K, Colman H, Holland EC, Louis DN, Jenkins RB, et al. cIMPACT-NOW update 3: recommended diagnostic criteria for "Diffuse astrocytic glioma, IDH-wildtype, with molecular features of glioblastoma, WHO grade IV". *Acta Neuropathol* 2018;136:805-10. doi: 10.1007/s00401-018-1913-0.
4. Bray F, Ferlay J, Soerjomataram I, Siegel RL, Torre LA, Jemal A. Global cancer statistics 2018: GLOBOCAN estimates of incidence and mortality worldwide for 36 cancers in 185 countries. *CA Cancer J Clin* 2018;68:394-424. doi: 10.3322/caac.21492.
5. Ostrom QT, Gittleman H, Fulop J, Liu M, Blanda R, Kromer C, et al. CBRUS Statistical Report: Primary Brain and Central Nervous System Tumors Diagnosed in the United States in 2008-2012. *Neuro Oncol* 2015;17(Suppl 4):iv1-62. doi: 10.1093/neuonc/nov189.
6. Miller KD, Ostrom QT, Kruchko C, Patil N, Tihan T, Cioffi G, et al. Brain and other central nervous system tumor statistics, 2021. *CA Cancer J Clin* 2021;71:381-406. doi: 10.3322/caac.21693.
7. Luthra R, Chen H, Roy-Chowdhuri S, Singh RR. Next-Generation Sequencing in Clinical Molecular Diagnostics of Cancer: Advantages and Challenges. *Cancers (Basel)* 2015;7:2023-36. doi: 10.3390/cancers7040874.
8. Stupp R, Brada M, van den Bent MJ, Tonn JC, Pentheroudakis G. High-grade glioma: ESMO Clinical Practice Guidelines for diagnosis, treatment and follow-up. *Ann Oncol* 2014;25(Suppl 3):iii93-101. doi: 10.1093/annonc/mdu050.
9. Stupp R, Mason WP, van den Bent MJ, Weller M, Fisher B, Taphoorn MJ, et al. Radiotherapy plus concomitant and adjuvant temozolomide for glioblastoma. *N Engl J Med* 2005;352:987-96. doi: 10.1056/NEJMoa043330.
10. Dy LF, Ong EP, Espiritu AI, Spears J, Omar AT. Survival times of patients with glioblastoma in low- and middle-income countries: a systematic review and meta-analysis. *Neurosurg Rev* 2022;45:3393-403. doi: 10.1007/s10143-022-01844-x.
11. Datta NR, Samiei M, Bodis S. Radiation therapy infrastructure and human resources in low- and middle-income countries: present status and projections for 2020. *Int J Radiat Oncol Biol Phys* 2014;89:448-57. doi: 10.1016/j.ijrobp.2014.03.002.
12. Abdel-Wahab M, Fidarova E, Polo A. Global Access to Radiotherapy in Low- and Middle-income Countries. *Clin Oncol (R*



- Coll Radiol) 2017;29:99-104. doi: 10.1016/j.clon.2016.12.004.
13. Zubizarreta EH, Fidarova E, Healy B, Rosenblatt E. Need for radiotherapy in low and middle income countries – the silent crisis continues. *Clin Oncol (R Coll Radiol)* 2015;27:107-14. doi: 10.1016/j.clon.2014.10.006.
  14. The World Bank. Out-of-pocket expenditure (% of current health expenditure). [Online] 2023 [Cited 2023 March 21]. Available from URL: <https://data.worldbank.org/indicator/SH.XPD.OOPC.CH.ZS>
  15. Uyl-de Groot CA, Stupp R, van der Bent M. Cost-effectiveness of temozolomide for the treatment of newly diagnosed glioblastoma multiforme. *Expert Rev Pharmacoecon Outcomes Res* 2009;9:235-41. doi: 10.1586/erp.09.15.
  16. Bajwa MH, Shah MM, Mustansir F, Gauhar F, Baig E, Zafar SN, et al. A Guideline On Guidelines – Neuro-Oncology Guideline Standards For Low And Middle-Income Countries. *J Pak Med Assoc* 2024;74(Suppl 3):s87-92. Doi: 10.47391/JPMA.S3.GNO-10.
  17. Davies E, Clarke C. Early symptoms of brain tumours. *J Neurol Neurosurg Psychiatry* 2004;75:1205-6. doi: 10.1136/jnnp.2003.033308.
  18. IJerman-Korevaar M, Snijders TJ, de Graeff A, Teunissen SCCM, de Vos FYF. Prevalence of symptoms in glioma patients throughout the disease trajectory: a systematic review. *J Neurooncol* 2018;140:485-96. doi: 10.1007/s11060-018-03015-9.
  19. Miotto EC, Junior AS, Silva CC, Cabrera HN, Machado MA, Benute GR, et al. Cognitive impairments in patients with low grade gliomas and high grade gliomas. *Arq Neuropsiquiatr* 2011;69:596-601. doi: 10.1590/s0004-282x2011000500005
  20. Drevelegas A. Imaging Modalities in Brain Tumors. In: Drevelegas A, eds. *Imaging of Brain Tumors with Histological Correlations*. Heidelberg, Germany: Springer-Verlag Berlin Heidelberg, 2002; pp 11-25. Doi: 10.1007/978-3-662-04951-8\_2
  21. Altieri R, Zenga F, Ducati A, Melcarne A, Cofano F, Mammi M, et al. Tumor location and patient age predict biological signatures of high-grade gliomas. *Neurosurg Rev* 2018;41:599-604. doi: 10.1007/s10143-017-0899-8.
  22. Barbagallo GMV, Altieri R, Garozzo M, Maione M, Di Gregorio S, Visocchi M, et al. High Grade Glioma Treatment in Elderly People: Is It Different Than in Younger Patients? Analysis of Surgical Management Guided by an Intraoperative Multimodal Approach and Its Impact on Clinical Outcome. *Front Oncol* 2021;10:e631255. doi: 10.3389/fonc.2020.631255.
  23. Lu VM, Phan K, Rovin RA. Comparison of operative outcomes of eloquent glioma resection performed under awake versus general anesthesia: A systematic review and meta-analysis. *Clin Neurol Neurosurg* 2018;169:121-7. doi: 10.1016/j.clineuro.2018.04.011.
  24. Blanshard HJ, Chung F, Manninen PH, Taylor MD, Bernstein M. Awake craniotomy for removal of intracranial tumor: considerations for early discharge. *Anesth Analg* 2001;92:89-94. doi: 10.1097/0000539-200101000-00018.
  25. Sacko O, Lauwers-Cances V, Brauge D, Sesay M, Brenner A, Roux FE. Awake craniotomy vs surgery under general anesthesia for resection of supratentorial lesions. *Neurosurgery* 2011;68:1192-8. doi: 10.1227/NEU.0b013e31820c02a3.
  26. Bakhshi SK, Baig E, Laghari AA, Khan DA, Junaid M, Ahmed J, et al. Awake craniotomy vs. general anesthesia for excision of brain tumors; first case control study from a low-and middle-income country. *Brain Tumor Res Treat* 2022;10(Suppl):s 432. Doi: 10.14791/btrt.2022.10.F-1281.
  27. Stummer W, Pichlmeier U, Meinel T, Wiestler OD, Zanella F, Reulen HJ. Fluorescence-guided surgery with 5-aminolevulinic acid for resection of malignant glioma: a randomised controlled multicentre phase III trial. *Lancet Oncol* 2006;7:392-401. doi: 10.1016/S1470-2045(06)70665-9.
  28. Lacroix M, Abi-Said D, Fourney DR, Gokaslan ZL, Shi W, DeMonte F, et al. A multivariate analysis of 416 patients with glioblastoma multiforme: prognosis, extent of resection, and survival. *J Neurosurg* 2001;95:190-8. doi: 10.3171/jns.2001.95.2.0190.
  29. Wach J, Vychopen M, Kühnapfel A, Seidel C, Güresir E. A Systematic Review and Meta-Analysis of Supramarginal Resection versus Gross Total Resection in Glioblastoma: Can We Enhance Progression-Free Survival Time and Preserve Postoperative Safety? *Cancers (Basel)* 2023;15:1772. doi: 10.3390/cancers15061772.
  30. Gerritsen JKW, Viëtor CL, Rizopoulos D, Schouten JW, Klimek M, Dirven CMF, et al. Awake craniotomy versus craniotomy under general anesthesia without surgery adjuncts for supratentorial glioblastoma in eloquent areas: a retrospective matched case-control study. *Acta Neurochir (Wien)* 2019;161:307-15. doi: 10.1007/s00701-018-03788-y.
  31. Zhang N, Yu Z, Hameed NUF, Xu G, Song Y, Wu B, et al. Long-Term Functional and Oncologic Outcomes of Glioma Surgery with and without Intraoperative Neurophysiologic Monitoring: A Retrospective Cohort Study in a Single Center. *World Neurosurg* 2018;119:e94-105. doi: 10.1016/j.wneu.2018.07.051.
  32. Khalafallah AM, Rakovec M, Bettogowda C, Jackson CM, Gallia GL, Weingart JD, et al. A Crowdsourced Consensus on Supratotal Resection Versus Gross Total Resection for Anatomically Distinct Primary Glioblastoma. *Neurosurgery* 2021;89:712-19. doi: 10.1093/neuros/nyab257.
  33. Jackson C, Choi J, Khalafallah AM, Price C, Bettogowda C, Lim M, et al. A systematic review and meta-analysis of supratotal versus gross total resection for glioblastoma. *J Neurooncol* 2020;148:419-31. doi: 10.1007/s11060-020-03556-y.
  34. Incekara F, Koene S, Vincent AJPE, van den Bent MJ, Smits M. Association Between Supratotal Glioblastoma Resection and Patient Survival: A Systematic Review and Meta-Analysis. *World Neurosurg* 2019;127:617-24.e2. doi: 10.1016/j.wneu.2019.04.092.
  35. Brown TJ, Brennan MC, Li M, Church EW, Brandmeir NJ, Rakszawski KL, et al. Association of the Extent of Resection With Survival in Glioblastoma: A Systematic Review and Meta-analysis. *JAMA Oncol* 2016;2:1460-9. doi: 10.1001/jamaoncol.2016.1373.
  36. Sanai N, Berger MS. Glioma extent of resection and its impact on patient outcome. *Neurosurgery* 2008;62:753-64. doi: 10.1227/01.neu.0000318159.21731.cf.
  37. Hallaert G, Pinson H, Vanhauwaert D, Van den Broecke C, Van Roost D, Boterberg T, et al. Partial resection offers an overall survival benefit over biopsy in MGMT-unmethylated IDH-wildtype glioblastoma patients. *Surg Oncol* 2020;35:515-9. doi: 10.1016/j.suronc.2020.10.016.
  38. Baro V, Cerretti G, Todoverto M, Della Puppa A, Chioffi F, Volpin F, et al. Newly Diagnosed Multifocal GBM: A Monocentric Experience and Literature Review. *Curr Oncol* 2022;29:3472-88. doi: 10.3390/curroncol29050280.
  39. Albert FK, Forsting M, Sartor K, Adams HP, Kunze S. Early postoperative magnetic resonance imaging after resection of malignant glioma: objective evaluation of residual tumor and its influence on regrowth and prognosis. *Neurosurgery* 1994;34:45-61. doi: 10.1097/00006123-199401000-00008.
  40. Eidel O, Burth S, Neumann JO, Kieslich PJ, Sahm F, Jungk C, et al. Tumor Infiltration in Enhancing and Non-Enhancing Parts of Glioblastoma: A Correlation with Histopathology. *PLoS One* 2017;12:e0169292. doi: 10.1371/journal.pone.0169292.
  41. Lasocki A, Gaillard F. Non-Contrast-Enhancing Tumor: A New Frontier in Glioblastoma Research. *AJNR Am J Neuroradiol* 2019;40:758-65. doi: 10.3174/ajnr.A6025.
  42. Altaf A, Baqai MWS, Urooj F, Alam MS, Aziz HF, Mubarak F, et al. Intraoperative use of ultra-low-field, portable magnetic resonance imaging - first report. *Surg Neurol Int* 2023;14:212. doi: 10.25259/SNI\_124\_2023.

43. Tanboon J, Williams EA, Louis DN. The Diagnostic Use of Immunohistochemical Surrogates for Signature Molecular Genetic Alterations in Gliomas. *J Neuropathol Exp Neurol* 2016;75:4-18. doi: 10.1093/jnen/nlv009.
44. Wimmer K, Kratz CP, Vasen HF, Caron O, Colas C, Entz-Werle N, et al. Diagnostic criteria for constitutional mismatch repair deficiency syndrome: suggestions of the European consortium 'care for CMMRD' (C4CMMRD). *J Med Genet* 2014;51:355-65. doi: 10.1136/jmedgenet-2014-102284.
45. Hegi ME, Diserens AC, Gorlia T, Hamou MF, de Tribolet N, Weller M, et al. MGMT gene silencing and benefit from temozolomide in glioblastoma. *N Engl J Med* 2005;352:997-1003. doi: 10.1056/NEJMoa043331.
46. Solimando DA Jr, Waddell JA. Procarbazine, Lomustine, and Vincristine (PCV) Regimen for Central Nervous System Tumors. *Hosp Pharm* 2017;52:98-104. doi: 10.1310/hpj5202-98.
47. van den Bent MJ, Baumert B, Erridge SC, Vogelbaum MA, Nowak AK, Sanson M, et al. Interim results from the CATNON trial (EORTC study 26053-22054) of treatment with concurrent and adjuvant temozolomide for 1p/19q non-co-deleted anaplastic glioma: a phase 3, randomised, open-label intergroup study. *Lancet* 2017;390:1645-53. doi: 10.1016/S0140-6736(17)31442-3.
48. Stupp R, Mason WP, van den Bent MJ, Weller M, Fisher B, Taphoorn MJ, et al. Radiotherapy plus concomitant and adjuvant temozolomide for glioblastoma. *N Engl J Med* 2005;352:987-96. doi: 10.1056/NEJMoa043330.
49. Solimando DA Jr, Waddell JA. Procarbazine, Lomustine, and Vincristine (PCV) Regimen for Central Nervous System Tumors. *Hosp Pharm* 2017;52:98-104. doi: 10.1310/hpj5202-98.
50. Khasraw M, Ameratunga MS, Grant R, Wheeler H, Pavlakis N. Antiangiogenic therapy for high-grade glioma. *Cochrane Database Syst Rev* 2014;2014:CD008218. doi: 10.1002/14651858.CD008218.pub3.
51. Rahmathulla G, Hovey EJ, Hashemi-Sadraei N, Ahluwalia MS. Bevacizumab in high-grade gliomas: a review of its uses, toxicity assessment, and future treatment challenges. *Onco Targets Ther* 2013;6:371-89. doi: 10.2147/OTT.S38628.
52. Birk HS, Han SJ, Butowski NA. Treatment options for recurrent high-grade gliomas. *CNS Oncol* 2017;6:61-70. doi: 10.2217/cns-2016-0013.
53. Robin AM, Lee I, Kalkanis SN. Reoperation for Recurrent Glioblastoma Multiforme. *Neurosurg Clin N Am* 2017;28:407-28. doi: 10.1016/j.nec.2017.02.007.
54. Han SJ, Rolston JD, Molinaro AM, Clarke JL, Prados MD, Chang SM, et al. Phase II trial of 7 days on/7 days off temozolomide for recurrent high-grade glioma. *Neuro Oncol* 2014;16:1255-62. doi: 10.1093/neuonc/nou044.
55. Vredenburgh JJ, Desjardins A, Reardon DA, Friedman HS. Experience with irinotecan for the treatment of malignant glioma. *Neuro Oncol* 2009;11:80-91. doi: 10.1215/15228517-2008-075.
56. Kazmi F, Soon YY, Leong YH, Koh WY, Vellayappan B. Re-irradiation for recurrent glioblastoma (GBM): a systematic review and meta-analysis. *J Neurooncol* 2019;142:79-90. doi: 10.1007/s11060-018-03064-0.

---

**DISCLAIMER**

Articles published in JPMA and Supplements of JPMA do not represent the views of the editor or editorial Board. Authors are solely responsible for the opinions expressed and the accuracy of the data.

The contribution of each author towards the published research included in this supplement is the responsibility of the authors and their institutions.

It is expected to be in accordance and compliance with the ICMJE Guidelines.

Any questions/queries raised by readers should be directed to the corresponding author.

## NARRATIVE REVIEW

## Consensus guidelines for the management of vestibular schwannoma for low- and middle-income countries

Syed Ather Enam<sup>1</sup>, Muhammad Shakir<sup>2</sup>, Ahsan Ali Khan<sup>3</sup>, Muniba Tahir<sup>4</sup>, Kaynat Siddiqui<sup>5</sup>, Muhammad Shahzad Shamim<sup>6</sup>, Mohammad Hamza Bajwa<sup>7</sup>, Asim Hafiz<sup>8</sup>, Ahmed Gilani<sup>9</sup>, Faiza Urooj<sup>10</sup>

**Pakistan Brain Tumour Consortium:** Authors list at the end of the supplement

### Abstract

Vestibular Schwannoma (VS), previously known as acoustic neuroma, constitutes the majority of tumours found in the cerebellopontine angle (CPA). Most guidelines for managing CPA tumours have been developed by high-income countries (HICs). However, these guidelines often fall short in addressing the unique challenges encountered in low- and middle-income countries (LMICs), such as Pakistan. In LMICs, issues related to a limited healthcare workforce, inadequate infrastructure, and constrained financial resources hinder the effective implementation of these HIC-derived guidelines. Additionally, it has been observed that VS tends to present at a larger size in LMICs compared to HICs. Given that VS is the predominant type of CPA tumour and other types are covered under separate guidelines, this article aims to provide practical, context-specific recommendations for the screening, diagnosis, and management of Vestibular Schwannoma in LMIC settings. Our focus is to bridge the gap in care strategies and adapt them to the resource constraints and clinical realities of LMICs.

**Keywords:** Neuroma, acoustic, cerebellopontine angle, health care, vestibular schwannoma, radiosurgery, tumours

**DOI:** <https://doi.org/10.47391/JPMA.S3.GNO-13>

### Introduction

The cerebellopontine angle (CPA), located in the posterior cranial fossa, forms a triangular space that houses cranial nerves V, VI, VII, VIII, along with the anterior inferior cerebellar artery, making it a key anatomical landmark. Notably, CPA tumours account for 5 to 10% of all intracranial tumours. Among these, vestibular

<sup>1-3,5-7</sup>Department of Neurosurgery, The Aga Khan University, Karachi, Pakistan.

<sup>4</sup>Dow University of Health and Sciences, Karachi, Pakistan. <sup>8</sup>Section of Radiation Oncology, The Aga Khan University, Karachi, Pakistan. <sup>9</sup>Department of Pathology, University of Colorado, Children's Hospital Colorado, USA. <sup>10</sup>The Aga Khan Medical College and University, Karachi, Pakistan.

**Correspondence:** Syed Ather Enam **Email:** [ather.enam@aku.edu](mailto:ather.enam@aku.edu)

schwannomas (VS) represent the majority (75 to 85%), followed by meningiomas (10–15%) and epidermoid (7–8%).<sup>1-3</sup>

Patients with VS commonly experience unilateral sensorineural hearing loss (94%) and tinnitus (83%), with vertigo and unsteadiness also reported in 17–75% of cases.<sup>4</sup> The diagnostic process for CPA tumours involves a thorough medical history, physical examination, audiometric testing, and radiographic assessment. The contrast-enhanced T1-weighted MRI sequence stands as the diagnostic gold standard, supplemented by preoperative CT scans for detailed evaluation of the petrous bone's anatomy.<sup>5-7</sup>

The management of VS, a comparatively rare condition, poses significant challenges to neurosurgeons and otologists.<sup>8</sup> Emphasizing early detection and a multidisciplinary treatment approach has been linked to improved outcomes.<sup>9</sup> However, a study in Pakistan reveals that advanced stage tumours, indicative of delayed presentation, are quite prevalent, often hindering the possibility of curative resection. Moreover, patients with tumours larger than 4 cm exhibit significantly higher postoperative morbidity.<sup>10</sup>

Given the significant impact of VS and the current lack of consensus on treatment modalities, this paper advocates for the development of evidence-based guidelines for the diagnosis and management of VS, particularly tailored to the resource constraints of low- and middle-income countries (LMICs). The primary goal is to establish practical, evidence-based management protocols adaptable to the healthcare systems in these regions, keeping in mind the challenges of late presentation and associated complications in such settings.

### Methodology

The literature search for high-quality data on vestibular schwannoma was done on different databases, including PubMed, Google Scholar, Scopus, and Embase. The most relevant and high-quality studies were analyzed to develop evidence-based recommendations. An expert panel was convened consisting of specialists and leading

experts within the field of neuro-oncology to identify the gaps in diagnosis and management of vestibular schwannoma within Pakistan. This group was tasked with identifying best-practice recommendations and their application within the context of Pakistan as an LMIC. Recommendations were collated, reviewed, and debated regarding utility and evidence-based practices in a process that has been previously detailed.<sup>11</sup>

### Initial evaluation

MRI is recommended for screening of asymmetrical sensorineural hearing loss (with  $\geq 10$  dB of interaural difference at 2 or more consecutive frequencies or  $\geq 15$  dB at one frequency) subjective asymmetric tinnitus, and sudden SNHL (Sensorineural Hearing Loss).<sup>5,8,12</sup> However, screening with MRI is not always feasible in LMICs owing to limited resources, workforce, infrastructure, and financing. If MRI scan is accessible, we recommend using it for screening. Nevertheless, if accessibility or affordability are barriers, we suggest using the auditory brainstem response (ABR) or fast-spin echo MRI as a substitute for screening of VS. ABR (sensitivity of 100% and specificity of 61.9%) and fast-spin echo MRI (sensitivity of 100% and a specificity of 100%) are widely available and cost-effective tools.<sup>13–15</sup>

The recommended modality of choice for the diagnosis of VS is MRI (contrast-enhanced T1-weighted and high-resolution T2-weighted). The tumour can be found using standard T1, T2, FLAIR, and DWI MR sequences acquired in the axial, coronal, and sagittal planes.<sup>16</sup> To assess the preoperative anatomy of the petrous bone, a complementary CT scan might be used.<sup>17</sup> We recommend MRI (contrast-enhanced T1-weighted and high-resolution T2-weighted MRI) and CT scan for the preoperative detection of VS. If an MRI scan is unavailable or not possible then as the bare minimum, we suggest a high-resolution CT scan with or without contrast.

### Surgical management

Observation is recommended in cases of small, asymptomatic tumours with normal cranial nerve function. If a watch and wait approach is taken, MRI should be obtained annually for 5 years, with the interval lengthening after that if the tumor is stable. SRS can be used as an alternative to observation to stop tumor growth and maintain long-term nerve function. However, there is still a negligible chance of nerve function or quality of life deteriorating. Surgery is also an option if the primary goal of management is the long-term preservation of nerve function, but there is a considerable risk of functional decline, up to 50%. Therefore, we recommend against operating on these patients. Therapy

option should be discussed with patient to prevent further deterioration of small tumours exhibiting vestibular and/or auditory symptoms. In these contexts, SRS provides a higher rate of hearing preservation and a lower risk for facial paresis than surgery. The goal of therapy can be the cure or tumour control while maintaining facial nerve function in patients with small tumours and total hearing loss. In these cases, any option is acceptable. Since no function is ever really jeopardized, observation is typically the best course of action. SRS or surgery both have a low chance of causing facial nerve injury and may offer long-term control or a cure. SRS is the primary choice if tumor control is deemed sufficient by the patient since it preserves facial nerve function and has a lower risk profile than surgery.<sup>8,16</sup>

Patients with medium-sized tumours (<3 cm), surgery or radiosurgery can be recommended at a reasonably similar level. SRS has a better risk profile than surgery, albeit surgery can remove the tumor completely. All possibilities should be carefully explained to the patients.<sup>8</sup>

In a retrospective bicentric cohort study, Tatagiba et al,<sup>18</sup> compared SRS and microsurgical for treating sporadic VS in two specialized neurosurgical centres, using data from 901 patients treated between 2005 and 2011. The study utilised the Koos classification to categorize the tumours: Koos I indicates an intracanalicular tumour, Koos II represents a tumour extending into the cistern but not reaching the brainstem, Koos III denotes a tumour reaching the brainstem surface, and Koos IV describes a tumour deforming the brainstem surface and shifting the fourth ventricle. The findings showed that overall, microsurgery had superior tumour control with a 7% recurrence rate, compared to 11% for SRS. In smaller tumours, classified as Koos I (intracanalicular) and II (extending into the cistern), both treatments were equally effective. However, in larger VS, classified as Koos III (reaching the brainstem surface) and IV (deforming the brainstem surface), microsurgery was more effective, with a clear correlation between the extent of resection and recurrence-free survival. While facial and hearing deterioration were similar for both treatments in smaller tumours (Koos I and II), these side effects were more pronounced in microsurgery for larger tumours (Koos III and IV). Additionally, microsurgery was more effective in improving symptoms like tinnitus, vertigo, imbalance, and trigeminal issues in these larger tumours. The study concludes that SRS is comparable to microsurgery in smaller VS (Koos I and II) but less effective in larger ones (Koos III and IV), suggesting that combination therapy should be limited to residual tumours not exceeding Koos II size.<sup>18</sup>

Patients with larger sporadic VS tumour sizes should be warned about the higher-than-average risk of loss of serviceable hearing when undergoing microsurgical resection.<sup>19</sup> Long-lasting eighth cranial nerve symptoms are frequent in patients with large tumours with brainstem compression (>3 cm). These patients frequently also exhibit other symptoms such as facial nerve paresis and gait ataxia. Surgery is the only treatment that can decompress the brainstem and stretched cranial nerves, which is the main goal of therapy. A sizeable risk of loss or impairment of cranial nerve function is associated with surgery for large tumours. For this reason, subtotal resection (maximal safe resection) of the tumour followed by SRS or observation to reduce the tumour bulk is a viable approach.<sup>8,19</sup>

In small, asymptomatic VS (<2.5cm), we recommend observation with an annual MRI for 5 years, and the interval lengthening after that if the tumour is stable. In small VS with auditory or vestibular symptoms, we suggest SRS owing to its higher rate of hearing and facial nerve preservation. If SRS facilities and expertise are not available, then we advise surgery. In cases of medium-sized VS (<3 cm), we propose SRS or surgery depending on the patient's preference, centre resources, and neurosurgeon expertise. For patients with large sporadic VS, we recommend subtotal resection (maximal safe resection) and postop SRS due to the high rate of hearing and facial nerve preservation (95% and 60%) with limited regrowth of tumour (5%).<sup>20</sup> The surgical approach depends upon the surgeon's preference. The most often surgical approach used is the retro sigmoid craniotomy and intracapsular maximal safe resection. The other surgical approaches include presigmoid translabyrinthine and sigmoid retrolabyrinthine. The translabyrinthine approach is suitable for patients with no functional baseline hearing as it would result in permanent hearing loss. However, sigmoid retro-labyrinthine can provide excellent visualization and control over the tumour without significantly compromising functional hearing.

### **Intraoperative cranial nerve monitoring**

To enhance long-term facial nerve function following vestibular Schwannoma surgery routine use of intraoperative cranial nerve monitoring is required. Monitoring of the facial nerve consisting of direct electrical stimulation, and free-running electromyography to increase the rate of functional preservation. Evoked facial motor potentials are currently being examined.<sup>8,21</sup> When attempting to preserve hearing, brainstem auditory evoked responses are recommended.<sup>19</sup> Electromyography of the lower cranial nerves is suggested in cases of large lesions.<sup>8,22</sup> We

recommend Intraoperative cranial nerves monitoring if the center has the relevant modalities and trained workforce.

### **Pathologic assessment**

Histopathologic evaluation is relatively straightforward and relies upon the examination of haematoxylin and eosin (H&E) preparation. Immunohistochemical stains may be performed to distinguish from spindle cell meningioma, which can occasionally be present in this location. There is no recommendation on the prognostic significance of Antoni A versus B histologic patterns and mitotic figures due to the paucity of adequate data. Similarly, recommendations cannot be framed for the prediction of the clinical behaviour of VS in terms of light microscopic features (other than Antoni A versus B), KI-67 labelling index, proliferating cell nuclear antigen labelling index, and degree of vascular endothelial growth factor expression due to a scarcity of able data.<sup>23</sup>

### **Radiation therapy**

The International Stereotactic Radiosurgery Society (ISRS) recommends an option of single fraction radiosurgery (11-14 Gy) or fractionated stereotactic radiotherapy for small to moderate size VS without significant mass effect.<sup>24</sup> Since there is no difference in radiographic control with different doses, it is recommended to use (<13Gy, range 12-14 Gy) for single fraction SRS doses in order to preserve hearing and mitigate the risk of developing new cranial nerve deficits.<sup>25</sup>

VS is among the rare pathologies that do not necessitate a histopathological diagnosis prior to stereotactic radiosurgery (SRS). The presence of an intracanalicular extension into the internal auditory canal, accompanied by contrast enhancement on imaging, is a definitive indicator of VS. In cases of small VS, particularly when there is no evident mass effect on the brainstem, SRS can be confidently administered based solely on MRI findings.

There are no studies that compare the differences in the outcomes between Gamma Knife (GK), LINAC-based radiosurgery, CyberKnife, and proton beam.<sup>25</sup> Ideally, the time frame for follow-up imaging following SRS should consider clinical indications, a patient's unique situation, and institutional guidelines. The evaluation of recurrence over a long period of time with repeated MRIs is recommended. Regarding the time frame for these investigations, no recommendations are proposed.<sup>25</sup>

### **Hearing reservation**

The likelihood of successful hearing preservation should be discussed with patients who had functional hearing in the ipsilateral ear and are considering stereotactic

**Table-1:** Summary of Recommendations for Vestibular Schwannoma.

<b>Radiology</b>	<ul style="list-style-type: none"> <li>• MRI brain with and without contrast.</li> <li>• 'Minimum required' MRI protocol:               <ul style="list-style-type: none"> <li>◦ Imaging on at least 0.5T.</li> <li>◦ Sequences: Axial T2 and coronal or axial FLAIR sequence; pre-contrast T1 and contrast-enhanced T1.</li> </ul> </li> <li>• Tumor location, size, margins, enhancement pattern, relation with critical neurovascular structures, and presence of hemorrhage/mineralization.</li> <li>• First postoperative MRI is recommended after 3 months.               <ul style="list-style-type: none"> <li>◦ To identify the extent of resection.</li> <li>◦ To have a baseline to compare successive imaging.</li> </ul> </li> </ul>
<b>Neurosurgery and Radiation Oncology</b>	<ul style="list-style-type: none"> <li>• Small (&lt;2.5cm) asymptomatic VS: Observation and serial follow-up with imaging and hearing assessment.</li> <li>• Small (&lt;2.5cm) symptomatic VS: SRS/surgery/observation based on multiple factors (availability of expertise, risk assessment, baseline hearing status, patient's perception, social situation, financial considerations, and support system).</li> <li>• Symptomatic large VS (&gt;2.5cm): Maximal safe resection followed by postop SRS/SRT/ Fractionated SRT/observation.</li> <li>• For Patients with good baseline hearing undergoing SRS, a single fraction (&lt;13 Gy) is recommended to preserve hearing and avoid facial palsy.</li> <li>• Intraoperative cranial nerve monitoring is recommended for patients undergoing surgical resection.</li> <li>• Cases need to be managed in centres with site-specific clinical expertise and high volume.</li> </ul>
<b>Neuropathology</b>	<ul style="list-style-type: none"> <li>• Hematoxylin and eosin (H&amp;E) preparation.</li> <li>• Immunohistochemical stain GFAP, S-100 and/or SOX-10 if histology is not characteristic.</li> </ul>
<b>Follow-up</b>	<ul style="list-style-type: none"> <li>• First follow-up at post-op day 10 for wound assessment, stitch removal, and discussion related to histopathology/NOTB recommendations.</li> <li>• MRI every six months for the first year, and thereafter annually or biannually based on clinical signs and symptoms for 10 years and every 2-3 years.</li> <li>• Redo surgery can be considered in case of recurrence/disease progression after risk stratification in NOTB.</li> </ul>

MRI: Magnetic resonance imaging, FLAIR: Fluid-attenuated inversion recovery, VS: Vestibular Schwannoma, SRS: Stereotactic radiosurgery, SRT: Stereotactic Radiation Therapy, Gy: Gray, GFAP: Glial fibrillary acidic protein, NOTB: Neuro-oncology tumor board.

radiosurgery. The hearing preservation depends on good preoperative word recognition and/or pure tone thresholds with various cut-points reported, small tumour size, marginal tumour dosage  $\leq 12$  Gy and cochlear dose  $\leq 4$  Gy are the most reliable prognostic factors linked to maintenance of functional hearing. Age and gender are not reliable indicators of the success of hearing preservation.<sup>7</sup>

### Post-operative management and prognosis

During surgery, lower cranial nerves are more prone to damage, specifically IX, X, XI, and XII, which will lead to difficulty in swallowing, stridor, and inability to protect the airway postoperatively. If the stridor is so severe that it causes respiratory distress, then endotracheal intubation is recommended. Emergency tracheostomy and cricothyrotomy can also be used as alternative techniques in patients with difficult endotracheal intubation. Tracheostomy is considered the long-term management in persistent stridor postoperatively.<sup>26</sup>

The recurrence rate of VS ranges from 0.51% to 9.2%. Long-term follow-up is necessary after the resection of the tumour, an MRI study reported 22 months as doubling time for residual fragments of the tumour. Moreover, tumour recurrence happens after a decade in the case of gross total resection (GTR), and recurrence is seen after 2.7 years in the case of subtotal resection (STR). The study revealed recurrence occurs when the post-operatively latest MRI image shows a >5mm increase in the size of the residual tumour.<sup>27</sup>

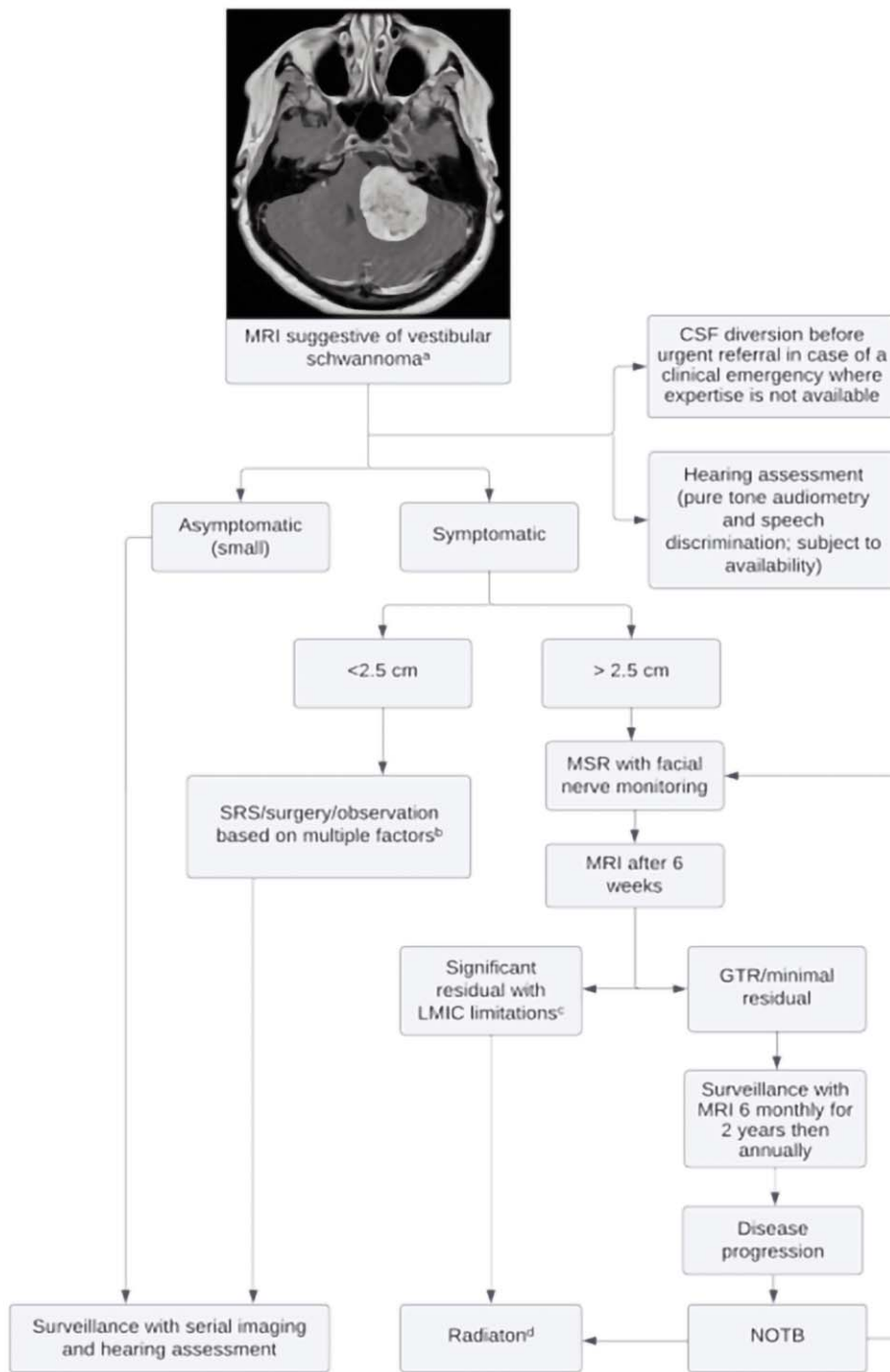
### Emerging therapies for the treatment

Bevacizumab has a favourable impact on hearing and tumour growth and is a promising therapy option for patients with bilateral (NF2) or unilateral VS.<sup>28-30</sup> Lapatinib can be used in NF2 to improve hearing and reduce the size of the VS. However, the use of erlotinib or everolimus is not recommended in NF2. To improve postoperative facial nerve outcomes, nimodipine perioperative therapy should be taken into consideration (or hydroxyethyl starch may be added).<sup>31</sup>

### Conclusion

Created to assist healthcare professionals operating in areas with limited resources, these guidelines offer a practical framework derived from valuable insights (refer to Table 1 and Figure 1). By putting these guidelines into practice, there is substantial potential for enhancing specific outcomes and fostering a greater focus on collaborative healthcare in low- and middle-income countries (LMICs), like Pakistan.

**Knowledge gaps:** One of the most common issues



MRI: Magnetic resonance imaging, CSF: Cerebrospinal fluid, MSR: Maximal safe resection, GTR: Gross total resection, NOTB: Neuro-oncology tumor board, SRS: Stereotactic radiosurgery  
<sup>a</sup>Vestibular schwannoma associated with NF2 does not follow this algorithm.  
<sup>b</sup>Serviceable hearing, availability of expertise, risk assessment, patient's perception, social situation, financial considerations, and support system  
<sup>c</sup>LMIC limitations (cost of serial follow-ups, lost to follow, limited access to specialized health care due to distance, lack of social support)  
<sup>d</sup>Conventional/ISRT/SRS

Figure-1: Management algorithm for Vestibular schwannoma.

faced in the LMICs is the judicious use of SRS. There are no guidelines/recommendations on the appropriate utilization of SRS and we need more efforts and prospective high-quality studies to obtain scientific evidence in this regard.

**Disclaimer:** None.

**Conflict of Interest:** None.

**Funding Disclosure:** None.

## References

- Samii M, Gerganov VM. Tumors of the cerebellopontine angle. *Handb Clin Neurol* 2012;105:633-9. doi: 10.1016/B978-0-444-53502-3.00013-6.
- Huang MY, Vermeulen S. Clinical perspectives regarding patients with internal auditory canal or cerebellopontine angle lesions: surgical and radiation oncology perspectives. *Semin Ultrasound CT MR* 2003;24:124-32. doi: 10.1016/s0887-2171(03)90034-5.
- Zamani AA. Cerebellopontine angle tumors: role of magnetic resonance imaging. *Top Magn Reson Imaging* 2000;11:98-10. doi: 10.1097/00002142-200004000-00005.
- Andersen JF, Nilsen KS, Vassbotn FS, Møller P, Myrseth E, Lund-Johansen M, et al. Predictors of vertigo in patients with untreated vestibular schwannoma. *Otol Neurotol* 2015;36:647-52. doi: 10.1097/MAO.0000000000000668.
- Hentschel M, Scholte M, Steens S, Kunst H, Rovers M. The diagnostic accuracy of non-imaging screening protocols for vestibular schwannoma in patients with asymmetrical hearing loss and/or unilateral audiovestibular dysfunction: a diagnostic review and meta-analysis. *Clin Otolaryngol* 2017;42:815-23. doi: 10.1111/coa.12788.
- De Foer B, Kenis C, Van Melkebeke D, Vercruyse JP, Somers T, Pouillon M, et al. Pathology of the vestibulocochlear nerve. *Eur J Radiol* 2010;74:349-58. doi: 10.1016/j.ejrad.2009.06.033.
- Carlson ML, Vivas EX, McCracken DJ, Sweeney AD, Neff BA, Shepard NT, et al. Congress of Neurological Surgeons Systematic Review and Evidence-Based Guidelines on Hearing Preservation Outcomes in Patients With Sporadic Vestibular Schwannomas. *Neurosurgery* 2018;82:E35-9. doi: 10.1093/neuros/nyx511.
- Goldbrunner R, Weller M, Regis J, Lund-Johansen M, Stavrinos P, Reuss D, et al. EANO guideline on the diagnosis and treatment of vestibular schwannoma. *Neuro Oncol* 2020;22:31-45. doi: 10.1093/neuonc/noz153.
- Kawauchi D, Ohno M, Miyakita Y, Takahashi M, Yanagisawa S, Omura T, et al. Early Diagnosis and Surgical Intervention Within 3 Weeks From Symptom Onset Are Associated With Prolonged Survival of Patients With Glioblastoma. *Neurosurgery* 2022;91:741-8. doi: 10.1227/neu.0000000000002096.
- Kazim SF, Shamim MS, Enam SA, Bari ME. Microsurgical excisions of vestibular schwannomas: A tumor-size-based analysis of neurological outcomes and surgical complications. *Surg Neurol Int* 2011;2:41. doi: 10.4103/2152-7806.78516.
- Bajwa MH, Shah MM, Mustansir F, Gauhar F, Baig E, Zafar SN, et al. A Guideline On Guidelines – Neuro-Oncology Guideline Standards For Low And Middle-Income Countries. *J Pak Med Assoc* 2024;74(Suppl 3):s87-92. Doi: 10.47391/JPMA.S3.GNO-10.
- Sweeney AD, Carlson ML, Shepard NT, McCracken DJ, Vivas EX, Neff BA, et al. Congress of Neurological Surgeons Systematic Review and Evidence-Based Guidelines on Otologic and Audiologic Screening for Patients With Vestibular Schwannomas. *Neurosurgery* 2018;82:E29-31. doi: 10.1093/neuros/nyx509.
- Koors PD, Thacker LR, Coelho DH. ABR in the diagnosis of vestibular schwannomas: a meta-analysis. *Am J Otolaryngol* 2013;34:195-204. doi: 10.1016/j.amjoto.2012.11.011.
- Rupa V, Job A, George M, Rajshekhar V. Cost-effective initial screening for vestibular schwannoma: auditory brainstem response or magnetic resonance imaging? *Otolaryngol Head Neck Surg* 2003;128:823-8. doi: 10.1016/S0194-59980300358-9.
- Marx SV, Langman AW, Crane RC. Accuracy of fast spin echo magnetic resonance imaging in the diagnosis of vestibular schwannoma. *Am J Otolaryngol* 1999;20:211-6. doi: 10.1016/s0196-0709(99)90002-9.
- Dunn IF, Bi WL, Mukundan S, Delman BN, Parish J, Atkins T, et al. Congress of Neurological Surgeons Systematic Review and Evidence-Based Guidelines on the Role of Imaging in the Diagnosis and Management of Patients With Vestibular Schwannomas. *Neurosurgery* 2018;82:E32-4. doi: 10.1093/neuros/nyx510.
- Renowden S. Imaging of the cerebello-pontine angle. *Pract Neurol* 2014;14:e2. doi: 10.1136/practneurol-2014-000949.
- Tatagiba M, Wang SS, Rizk A, Ebner F, van Eck ATCJ, Naros G, et al. A comparative study of microsurgery and gamma knife radiosurgery in vestibular schwannoma evaluating tumor control and functional outcome. *Neurooncol Adv* 2023;5:vdad146. doi: 10.1093/noonjnl/vdad146.
- Hadjipanayis CG, Carlson ML, Link MJ, Rayan TA, Parish J, Atkins T, et al. Congress of Neurological Surgeons Systematic Review and Evidence-Based Guidelines on Surgical Resection for the Treatment of Patients With Vestibular Schwannomas. *Neurosurgery* 2018;82:E40-3. doi: 10.1093/neuros/nyx512.
- Starnoni D, Giammattei L, Cossu G, Link MJ, Roche PH, Chacko AG, et al. Surgical management for large vestibular schwannomas: a systematic review, meta-analysis, and consensus statement on behalf of the EANS skull base section. *Acta Neurochir (Wien)* 2020;162:2595-617. doi: 10.1007/s00701-020-04491-7.
- Acioly MA, Liebsch M, de Aguiar PH, Tatagiba M. Facial nerve monitoring during cerebellopontine angle and skull base tumor surgery: a systematic review from description to current success on function prediction. *World Neurosurg* 2013;80:e271-300. doi: 10.1016/j.wneu.2011.09.026.
- Vivas EX, Carlson ML, Neff BA, Shepard NT, McCracken DJ, Sweeney AD, et al. Congress of Neurological Surgeons Systematic Review and Evidence-Based Guidelines on Intraoperative Cranial Nerve Monitoring in Vestibular Schwannoma Surgery. *Neurosurgery* 2018;82:E44-6. doi: 10.1093/neuros/nyx513.
- Sughrue ME, Fung KM, Van Gompel JJ, Peterson JEG, Olson JJ. Congress of Neurological Surgeons Systematic Review and Evidence-Based Guidelines on Pathological Methods and Prognostic Factors in Vestibular Schwannomas. *Neurosurgery* 2018;82:E47-8. doi: 10.1093/neuros/nyx514.
- Tsao MN, Sahgal A, Xu W, De Salles A, Hayashi M, Levivier M, et al. Stereotactic radiosurgery for vestibular schwannoma: International Stereotactic Radiosurgery Society (ISRS) Practice Guideline. *J Radiosurg SBRT* 2017;5:5-2.
- Germano IM, Sheehan J, Parish J, Atkins T, Asher A, Hadjipanayis CG, et al. Congress of Neurological Surgeons Systematic Review and Evidence-Based Guidelines on the Role of Radiosurgery and Radiation Therapy in the Management of Patients With Vestibular Schwannomas. *Neurosurgery* 2018;82:E49-51. doi: 10.1093/neuros/nyx515.
- Arulvelan A, Gayatri P, Smita V, Nair SN. A retrospective analysis of stridor after vestibular schwannoma surgery. *J Neurosurg Anesthesiol* 2014;26:17-21. doi: 10.1097/ANA.0b013e3182945267.
- Panigrahi M, Kumar D, Vooturi S, Madigubba S. MIB Index as Predictor of Recurrence in Sporadic Vestibular Schwannomas. *World Neurosurg* 2018;120:e1203-7. doi: 10.1016/j.wneu.2018.09.039.



28. Morris KA, Golding JF, Axon PR, Afridi S, Blesing C, Ferner RE, et al. Bevacizumab in neurofibromatosis type 2 (NF2) related vestibular schwannomas: a nationally coordinated approach to delivery and prospective evaluation. *Neurooncol Pract* 2016;3:281-9. doi: 10.1093/nop/npv065.
29. Morris KA, Golding JF, Blesing C, Evans DG, Ferner RE, Foweraker K, et al. Toxicity profile of bevacizumab in the UK Neurofibromatosis type 2 cohort. *J Neurooncol* 2017;131:117-24. doi: 10.1007/s11060-016-2276-9.
30. Li KL, Djoukhadar I, Zhu X, Zhao S, Lloyd S, McCabe M, et al. Vascular biomarkers derived from dynamic contrast-enhanced MRI predict response of vestibular schwannoma to antiangiogenic therapy in type 2 neurofibromatosis. *Neuro Oncol* 2016;18:275-82. doi: 10.1093/neuonc/nov168.
31. Van Gompel JJ, Agazzi S, Carlson ML, Adewumi DA, Hadjipanayis CG, Uhm JH, et al. Congress of Neurological Surgeons Systematic Review and Evidence-Based Guidelines on Emerging Therapies for the Treatment of Patients With Vestibular Schwannomas. *Neurosurgery* 2018;82:E52-4. doi: 10.1093/neuros/nyx516.

---

**DISCLAIMER**

Articles published in JPMA and Supplements of JPMA do not represent the views of the editor or editorial Board. Authors are solely responsible for the opinions expressed and the accuracy of the data.

The contribution of each author towards the published research included in this supplement is the responsibility of the authors and their institutions. It is expected to be in accordance and compliance with the ICMJE Guidelines.

Any questions/queries raised by readers should be directed to the corresponding author.

## NARRATIVE REVIEW

**Consensus guidelines for the management of pediatric medulloblastoma in low- and middle-income countries**

Naureen Mushtaq<sup>1</sup>, Syed Ather Enam<sup>2</sup>, Mohammad Hamza Bajwa<sup>3</sup>, Fatima Mustansir<sup>4</sup>, Erum Baig<sup>5</sup>, Fatima Gauhar<sup>6</sup>, Afia Arif<sup>7</sup>, Ahsan Ali Khan<sup>8</sup>, Syed Ahmer Hamid<sup>9</sup>, Gohar Javed<sup>10</sup>, Fatima Mubarak<sup>11</sup>, Bilal Mazhar Qureshi<sup>12</sup>, Khurram Minhas<sup>13</sup>, Salman Kirmani<sup>14</sup>, Shahzadi Resham<sup>15</sup>, Asif Bashir<sup>16</sup>, Irfan Yousaf<sup>17</sup>, Ahmed Gilani<sup>18</sup>, Eric Bouffet<sup>19</sup>

**Pakistan Brain Tumour Consortium:** (Authors list at the end of the supplement)

**Abstract**

The management of medulloblastoma, a pediatric brain tumor, has evolved significantly with the advent of genomic subgrouping, yet morbidity and mortality remain high in LMICs like Pakistan due to inadequate multidisciplinary care infrastructure. This paper aims to establish evidence-based guidelines tailored to the constraints of such countries. An expert panel comprising neuro-oncologists, neurosurgeons, radiologists, radiation oncologists, neuropathologists, and pediatricians collaborated to develop these guidelines, considering the specific challenges of pediatric brain tumor care in Pakistan. The recommendations cover various aspects of medulloblastoma treatment, including pre-surgical workup, neurosurgery, neuropathology, chemotherapy, radiation therapy, and supportive care. They offer both minimum required and additional optional protocols for more advanced centers, ensuring comprehensive patient management with attention to complications and complexities encountered in Pakistan. The paper's consensus guidelines strive for uniformity in healthcare delivery and address significant gaps in diagnosis, treatment, and follow-up of pediatric medulloblastoma patients.

<sup>1,7</sup>Department of Paediatric Oncology, The Aga Khan University, Karachi, Pakistan. <sup>2,3,8,10</sup>Department of Neurosurgery, The Aga Khan University, Karachi, Pakistan. <sup>4</sup>Department of Surgery, Washington University School of Medicine, St. Louis, Missouri, USA. <sup>5</sup>Department of Surgery, University of Pennsylvania, USA. <sup>6</sup>The Aga Khan Medical College and University, Karachi, Pakistan. <sup>9</sup>Department of Paediatrics, The Indus Hospital, Karachi, Pakistan. <sup>11</sup>Department of Radiology, The Aga Khan University, Karachi, Pakistan. <sup>12</sup>Department of Radiation Oncology, The Aga Khan University, Karachi, Pakistan. <sup>13</sup>Department of Histopathology, The Aga Khan University, Karachi, Pakistan. <sup>14,15</sup>Department of Paediatrics, The Aga Khan University, Karachi, Pakistan. <sup>16</sup>Punjab Institute of Neurosciences, Lahore General Hospital, Pakistan. <sup>17</sup>Department of Surgical Oncology, Shaukat Khanum Memorial Cancer Hospital and Research Centre, Lahore, Pakistan. <sup>18</sup>Department of Pathology, University of Colorado, Children's Hospital Colorado, USA. <sup>19</sup>Department of Haematology/Oncology, The Hospital for Sick Children, Toronto, Canada

**Correspondence:** Naureen Mushtaq **Email:** naureen.mushtaq@aku.edu

**Keywords:** Medulloblastoma, neuropathology, neurosurgery, radiation oncologists, brain neoplasms, paediatricians, morbidity, genomics

**DOI:** <https://doi.org/10.47391/JPMA.S3.GNO-14>

**Introduction**

After acute leukemia, brain tumors are the most common malignancy in the pediatric population. The improvement of outcomes in acute lymphoblastic leukemia (ALL) patients in LMICs reflects the vast benefit achieved through relative affordable and easily accessible diagnostic and management protocols. However, the management of brain tumors requires a complex multidisciplinary and multifaceted approach, with the inclusion of neuroradiologists, pediatric neurosurgeons, neuropathologists, radiation oncologists and pediatric neuro-oncologists. The machinery required for diagnosis (magnetic resonance imaging (MRI), and histological, molecular and genetic techniques) and management (operating rooms (OR), radiation therapy facilities) are a limiting factor in countries with constrained resources. In Pakistan, there are only a few centers capable of properly treating pediatric brain tumors.

Medulloblastoma is the most common pediatric malignant brain tumor and is a significant cause of mortality and morbidity in this age-group, particularly in low- and middle-income countries (LMICs). To date, this disease has been stratified according to clinical and histological subtypes (classic, nodular/desmoplastic and anaplastic/large cell). With the advent of molecular subtyping and signatures identified for specific brain tumors, medulloblastoma can be sub-grouped through gene expression profiling, micro RNA profiling and methylation assay into 4 distinct groups: Wingless (WNT), Sonic hedgehog (SHH), Group 3, and Group 4. This new molecular classification has profound therapeutic and prognostic implications. Outcomes for medulloblastoma have significantly improved within high-income countries (HICs) due to the implementation of evidence-based guidelines and the availability of diagnostic and

therapeutic infrastructure.<sup>1,2</sup>

In light of these circumstances, it is necessary for updated guidelines to be developed and implemented within LMICs such as Pakistan that allow for the differences in infrastructure and gaps in healthcare facilities, while still aiming to improve morbidity and mortality of medulloblastoma cases. The intention of this paper is to provide 'minimum acceptable' guidelines for management as well as recommendations for 'preferable but optional' modalities. There is also a greater need for collaboration within multidisciplinary teams to improve patient care. The goal is to ultimately cover these lapses in care of patients with the necessary specialists in each respective field, and for practical implementation of these guidelines across the spectrum of healthcare facilities.

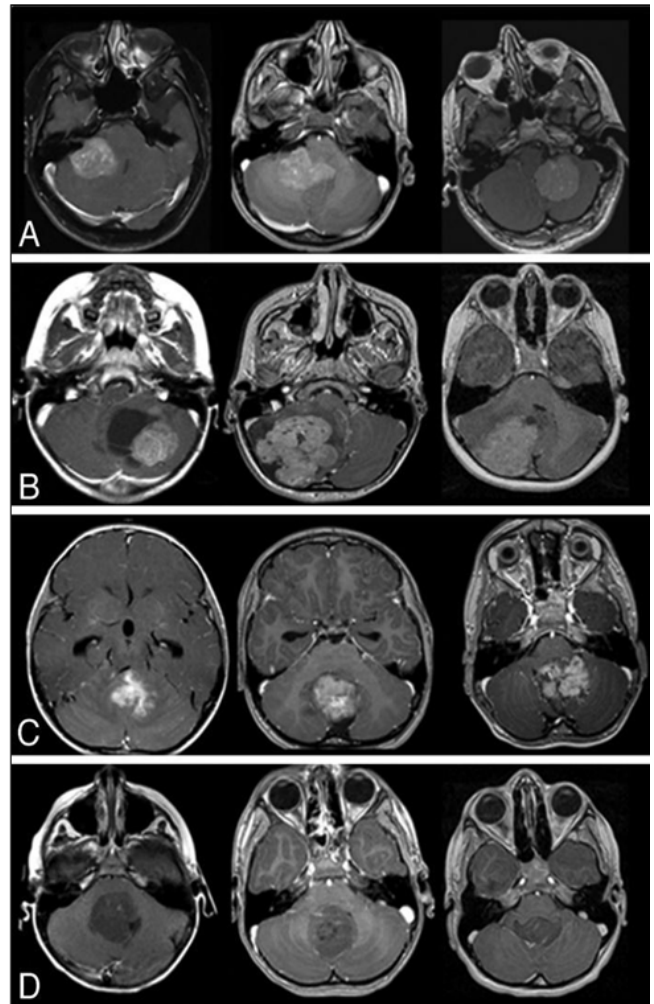
## Methodology

The literature search of the high-quality data on pediatric medulloblastoma was done in March 2023, on different databases including PubMed, Google Scholar, Scopus, and Embase. The most relevant and high-quality studies were analyzed to develop the evidence-based recommendations. An expert panel was convened consisting of specialists and leading experts within the field of neuro-oncology to identify the gaps in the diagnosis and management of pediatric medulloblastoma within Pakistan. This group was tasked with identifying best-practice recommendations and their application within Pakistan as an LMIC. Recommendations were collated, reviewed and debated regarding utility and evidence-based practices, in a process that has been previously detailed.<sup>3</sup>

## Initial evaluation

**Clinical presentation:** Pediatric patients with medulloblastoma more commonly present with obstructive hydrocephalus and raised intracranial pressure than symptoms due to local mass effect of posterior fossa lesion. Anatomically, medulloblastoma may present acutely with posterior fossa symptoms of headache, nausea, vomiting, and gait abnormalities. Clinicians should be on the lookout for warning signs of obstructive hydrocephalus causing raised intracranial pressure; visual blurring, severe intractable vomiting, and drowsiness are common giveaways. Focal neurological deficits may include rare cranial neuropathy (cranial nerve VI), or lower limb weakness secondary to spinal metastasis. The next step would be for clinicians in the clinic or ER to refer patients for neuro-imaging. Characteristic MR imaging features are shown in Figure 1.

**Neuroradiology:** Diagnosis would be predicated on



**Figure-1:** Characteristic MR imaging features according to medulloblastoma molecular subgroups. In the top row, characteristic location of WNT tumors in the CP/CPA region is shown. In the second row, SHH tumors are predominantly located in the cerebellar hemispheres. In the third row, group 3 tumors are located in the midline/fourth ventricle and show enhancement and ill-defined features against the adjacent brain parenchyma. In the fourth row, group 4 tumors are also located in the midline fourth ventricle but tend to show minimal or no enhancement.<sup>11</sup>

MRI scans, preferably MRI brain as well as whole spine to rule out spinal dissemination. These studies should be done on all patients with contrast, with symptoms highly-suspicious for medulloblastoma, or prior imaging that would suggest so. Often, patients will have rudimentary imaging studies done and then referred towards high-volume centers for surgical management. Therefore, the center responsible for the surgery should obtain and review all prior imaging and ensure a full MRI brain and spine study is done. Ideally, assessment for preoperative patients should include scans within 5 days prior to surgery. Given below are our recommendations for minimum required protocols and preferable protocols

**Table-1:** Radiology reporting guidelines for medulloblastoma<sup>11</sup>

Tumor Location	Midline vermian/fourth ventricle, cerebellar hemisphere, or cerebellar peduncle/cerebellopontine angle cistern (CP/CPA).
Tumor Margin	Ill-defined if >50% of the margin could not be distinguished from the surrounding cerebellar parenchyma on the basis of all imaging sequences.
Enhancement Pattern	Minimal/none if <10% was estimated to enhance. Solid if >90% of the tumor volume was estimated to enhance. Heterogeneous if varying degrees of enhancement were seen in 10%–90% of the tumor volume on the basis of radiologist's visual assessments.
Tumor Size	Should be given in three dimensions and try best to give volume. Formula for tumor volume is: Tumor volume= length x width <sup>2</sup> /2, where length represents the largest tumor diameter and width represents the perpendicular tumor diameter. Measurements should be taken on post contrast or T2W/FLAIR.
Hemorrhage/ Mineralization	Low signal on 2D gradient recalled-echo or bright on T1W should be used to detect.
Other Key Findings	Cysts/Cavities, Intracranial/leptomeningeal seeding, signs of necrosis as suggested by ring enhancement.

that may be possible at larger centers. However, minimum requirements for neuro-imaging should be met to optimize surgical planning and further management afterwards:

**Minimum required MRI protocol:** All patients should undergo brain MR imaging of at least at 0.5T. Mandatory sequences: Axial T2 and Coronal or axial FLAIR sequence. Pre-contrast T1 spin-echo and contrast-enhanced T1, followed by 2 planes of contrast-enhanced T1 spin-echo (TR/TE, 600–700/20 ms; 5-mm section thickness, 0.5 skip). All, patients should undergo DWI; b-value of 1000 s/mm<sup>2</sup>; 3 directions; 4-mm thickness, 0 skip)

**Preferable (Optional) protocols:** SWI/GRE/T2

**Reporting guidelines:** In order for accurate radiological reporting, it is essential that radiologists conform to a set pattern for reports, so as to ensure adequate interpretation for any physicians who may require interpretation of the imaging study in the future (Table 1). Tumor location, tumor margins, enhancement pattern, tumor size and presence of hemorrhage and mineralization are features that must be included in a radiological report for medulloblastoma.

## Neurosurgery

### Initial management for hydrocephalus:

Surgical resection of tumor and opening of the CSF pathway is the ideal treatment since it ameliorates symptoms along with emergent symptoms. If there is a delay in surgery, then CSF drainage can be employed initially via an external ventricular drainage (EVD), preferably with a long subcutaneous tunnel or an endoscopic third ventriculostomy (ETV) can be chosen. For both procedures, rapid decompression and over-drainage should be avoided.

Even though ETV and EVD exist as safer drainage procedures, in Pakistan and other LMICs, ventriculo-peritoneal shunts (VPS) are often preferred to drain CSF into the abdominal cavity. This may be because it leads to a temporary relief of symptoms. In such instances, parents of these patients tend to ignore the primary disease and fail to follow up. Adversely, this leads to significant tumor growth including seeding into CSF spaces. Moreover, lifelong shunt dependency, reverse herniation of the superior vermis into the quadrigeminal cistern, and seeding of the tumor in the abdominal cavity are concerns for neurosurgeons dealing with such cases. VPS placement in pediatric patients is associated with multiple associated morbidities, especially shunt infection that can delay definitive surgery, and hence should be avoided. In rare circumstances, where lack of neurosurgical facilities and inadequate nutritional status (malnutrition, infection) of the patient prohibit tumor surgery, VPS may be considered. In this case the neurosurgeon must closely monitor the patient and plan for tumor resection soon after the VPS. Ideally, ETV should always be preferred over VPS.

### Pre-operative preparations:

Pre-operative planning is a multi-disciplinary task. Parents' counselling with the pediatric neuro-oncologist is a vital part of surgical preparation. The surgery should be undertaken by an institute with adequate facilities and expert staff for intra- and post-operative care. The neurosurgeon performing the surgery need not be a pediatric neurosurgeon but should have expertise and experience in posterior fossa tumor surgery. Anesthesia team should have experience of handling pediatric neurosurgical cases; management of intra-operative volume loss, intravenous fluid and blood transfusion when required. A team of pediatricians should be appointed for the patient

for post-operative management along with the neurosurgery team. Often, it is beneficial for pediatric teams to be taken in consultation pre-operatively so that they may be aware of the preoperative planning and give recommendations where needed. Ideally, extensive laboratory investigations may be done before surgery.<sup>4</sup> However, if there are no overt signs of organ dysfunction seen, surgeons can proceed with baseline investigations (CBC, Creatinine, LFTs).

## Principles of surgery and technique

**Patient positioning:** Surgical excision of the tumor can either be done in a prone, Concorde or sitting position of the patient. Concorde position while the patient is prone provides the best surgical access and view of the tumor in the aqueductal region. The sitting position provides a clear operative field due to CSF and blood drainage. However, it does not provide any additional significant benefits. If the surgeon, the O.R. team including the anesthesiologist are more familiar with sitting position then surgery can be done in this position of the patient. There is a significant risk of air embolism, hypotension, supratentorial subdural hematoma and pneumocephalus; hence the surgical team should be cautious. Even in prone position alone, patient is at risk of associated edema of the face due to pooling of venous blood in the dural sinuses and tumor bed. This can be prevented by putting the patient in a slight reversed Trendelenburg position (head elevated above the level of the heart).

## Surgical procedure

**Surgical exposure:** A standard midline incision with suboccipital craniotomy can be used for ideal access to the tumor. If the CSF diversion was not performed before tumor surgery, a decision to place an EVD temporarily is reasonable. This can be done preferably through Frazier's point in the occipital region. A sample of 20-30 cc of CSF for cytology can be considered at this juncture.

Dissection of the muscle tissue has to be carried out in the midline raphe to avoid excessive blood loss. Every attempt should be made to leave a cuff of muscles at the level of inion extending laterally and avoiding exposing the skull to the point where the aponeurosis ends. This cuff of muscle provides a good closure to prevent post-operative CSF leak or formation of pseudomeningocele. Besides posterior fossa craniotomy, the surgeon should decide about the removal of C-1 arch, depending on the extent of the disease and need of exposure for visualization.

**Surgical technique:** Every effort should be made to

achieve gross total resection (GTR) of the tumor if possible, but in many cases attachment of the tumor to the obex or the floor of the fourth ventricle may prevent GTR, in these cases the strategy should be to attempt Maximum Safe Resection (MSR). It is best to define the extent of the tumor initially, and to temporarily plug the opening of cerebral aqueduct to prevent blood entering into rest of the ventricular system. For very large tumors, defining the extent of the tumor may have to be delayed until significant tumor debulking has been achieved. Microscope should be used with micro-surgical fine instruments. Ultrasonic aspirator, video/Doppler ultrasound may act as adjunct depending upon the availability and individual tumor characters. To minimize the chance of cerebellar mutism, it is best to avoid splitting the vermis and removal of tumor from the roof of the fourth ventricle and the cerebellar peduncles is done with a lot of caution and deliberation. With appropriate positioning of the cranium, the tumor can be excised through the foramen of Magendie, which is usually enlarged by the tumor. Closure of the dura is best done with the help of a patch obtained from the aponeurosis obtained by sub-galeal dissection further cranial to the muscle cuff at the inion. Water-tight closure of the dura minimizes formation of pseudomeningocele and CSF leak.

Operative notes should describe in detail, sites where the surgeon believes the tumor to still remain. Tumor tissue taken as biopsy or collected by surgical vacuum sucker in a sterile trap should be submitted to the pathology lab for frozen section (if facility is available) and histopathology.

**Post-operative complications:** Post-operative complications can occur either intra-operatively or within 6 hours of the procedure (immediate), within 72 hours (early) or after 72 hours (delayed). These include, but are not limited to, hemorrhage, venous air embolism, wound dehiscence, CSF leak, brainstem dysfunction and infection.

**Post-operative care:** The patient should be extubated in the O.R. post-operatively and kept under observation for 24-48 hours in a high dependency unit or pediatric intensive care unit. The EVD should be drained at 15-18 cm and ideally pulled out after 48 hours after ascertaining that the CSF is clear of blood and CSF pressure remains low. Post-operative observation and management of the patient should be under the care of the team of neurosurgery, pediatrics along with pediatric neuro-oncology.

Post-operative Neuroimaging and Testing: Within the first 48 hours post-operatively, a postoperative MRI of the

**Table-2:** Medulloblastoma: Classification based on 2016 WHO Classification of CNS tumors.<sup>7</sup>

	<b>WNT</b>	<b>SHH</b>	<b>Group 3</b>	<b>Group 4</b>
<b>Percentage of MB</b>	<b>10%</b>	<b>30%</b>	<b>25%</b>	<b>35%</b>
<b>Location</b>	<b>4<sup>th</sup> ventricle near brainstem</b>	<b>Cerebellum</b>	<b>4<sup>th</sup> ventricle near brainstem</b>	
Pathway of genetic alteration	Aberrant activation of the WNT signaling pathway, often caused by activating mutations in exon 3 of the CTNNB1 gene. They also show loss of chromosome 6.	Aberrant activation of the SHH signaling pathway. Germline or somatic mutations in components of the SHH pathway, such as PATCHED1 (PTCH1) and SUPPRESSOR OF FUSED (SUFU). Focal amplifications of MYCN and GLI2 are also reported. Mutations in the telomerase reverse transcriptase (TERT) promoter are frequently found in adult SHH MBs. Further divided into four subtypes - SHH α, SHH β, SHH γ, SHH δ.	Transcriptional signatures resembling photoreceptors and gamma aminobutyric acid-secreting (GABAergic) neurons. Amplification of the MYC oncogene, Unstable genomes, with multiple chromosomal gains and losses. Among these, one of the most common is coordinate loss of chromosome 17p and gain of chromosome 17q—called isochromosome 17q (i17q). Further divided into 3 subtypes - Group 3a, Group 3β, Group 3γ.	Groups 4a and 4γ have focal CDK6 amplification, chromosome 8p loss, and chromosome 7q gain. Group 4a also exhibits MYCN amplification, whereas Group 4γ does not. Group 4β is enriched in SNCAIP duplication and PRDM6 overexpression.
Comments	Most favorable outcome; rarely metastatic		Most aggressive of the four subgroups. Nearly 50% of Group 3MB patients exhibit metastatic dissemination at diagnosis.	Frequently metastatic at diagnosis and have intermediate outcomes.
Histology	Mostly classic	Desmoplastic/nodular in 50% of cases with remainder mostly being classic	Classic or anaplastic/large cell	Classic

patient should be obtained. If MRI is delayed by 72 hours, then MRI should be delayed by 3 weeks but not more than 4 weeks.

MRI brain with contrast (MRI is preferred) and MRI spine with gadolinium if possible these examinations should be performed within 72 hours (if not done before), or between 18-21 days post-op. This is believed to minimize the chances of post-op change being confused with residual tumor. Lumbar CSF cytology examination should be obtained pre-operatively or within 31 days after surgery. The optimal time for obtaining CSF is 2-3 weeks following surgery. Ventricular CSF (either pre- or post-op) may be used if a postoperative spinal tap is contraindicated. CSF should be sampled post-op and prior to starting radiotherapy, for cell count, cytology, glucose and protein (if not already performed at the time of surgery).

Once the patient has been shifted back to the ward, regular interval testing of CBC, differential and platelet count is necessary to watch for postoperative bleeding or

infection. A regular neurological examination should be well-documented and reviewed by the surgeon daily. Further monitoring is necessary as management progresses.<sup>5</sup>

### Neuropathology

The microscopic appearance of medulloblastoma often consists of densely packed small round undifferentiated cells with mild to moderate nuclear pleomorphism and a high mitotic count. Morphologic variants of medulloblastoma based on histopathological analysis include classic, desmoplastic/nodular, large cell/anaplastic and medulloblastoma with extensive nodularity (MBEN). A diagnosis of "medulloblastoma, not otherwise specified (NOS)" is appropriate when an embryonal neural tumor is located in the fourth ventricle or cerebellum and the nature of biopsied tissue prevents classification of the tumor.<sup>6</sup>

As previously mentioned, the pathology can be divided into 4 subgroups: WNT-activated, SHH-activated and non-WNT/non-SHH (Group 3 and Group 4). The current

integrated classification of medulloblastoma takes into account histological subtype, molecular subgrouping, WHO grading, and genetic information.<sup>7</sup> When molecular analysis is limited or not feasible, histopathological classification can be relied upon due to its clinical utility.

Molecular profiling studies are the gold standard for accurate characterization of medulloblastoma subgroups. Techniques such as real-time reverse transcriptase polymerase chain reaction (RT-PCR), profiling a set of marker genes at the RNA level using nanoString assay, differential expression of a select set of micro-RNAs or surrogate immunohistochemistry (IHC) markers can be used for molecular sub-grouping. However, all of these methods are not available everywhere. Fortunately, surrogate immunohistochemical markers, along with histological types, clinical and radiological data, can be used to subgroup most cases of medulloblastomas.

We recommend an immunohistochemical panel consisting of GAB1, beta-catenin, Filamin A and YAP1 be used as surrogate for medulloblastoma classification.<sup>8</sup> One caveat to using IHC as a surrogate for molecular analysis is that IHC cannot be used to classify Group 3 and Group 4 medulloblastomas. To assess p53 mutation status in cases of SHH subgroup, p53 immunostain can be used as surrogate to molecular studies. Table 2 elaborates on this further.

## Chemotherapy

Chemotherapy is an important component of the multidisciplinary management of medulloblastomas. Its timely initiation can allow for a reduced dose of CSI in

**Table-3:** Chemotherapy Regimens for Medulloblastoma<sup>12</sup>

	Number of cycles and duration	Drugs	Dosage	Days and route of administration	Monitoring
Regimen I Average risk Medulloblastoma, during radiation therapy	6 doses administered at weekly intervals	Vincristine	1.5 mg/m <sup>2</sup>	Day 1 (intravenously)	CBC Comprehensive metabolic panel Total bilirubin ALT and AST
Regimen II Average risk Medulloblastoma, maintenance chemotherapy for patients aged >5 years	6 cycles administered at 4 weekly intervals	Vincristine Cisplatin Lomustine	1.5 mg/m <sup>2</sup> 75 mg/m <sup>2</sup> 275 mg/m <sup>2</sup>	Day 1 (intravenously) Day 1 (intravenously) Day 1 (orally)	CBC Comprehensive metabolic panel Total bilirubin ALT and AST Serum creatinine GFRAudiogram
Regimen III High risk Medulloblastoma, maintenance therapy	6 cycles administered at 4 weekly intervals	Vincristine Cisplatin Cyclophosphamide	1.5 mg/m <sup>2</sup> 75 mg/m <sup>2</sup> 1000 mg/m <sup>2</sup>	Day 1 (intravenously) Day 1 (intravenously) Days 2 and 3 (intravenously)	CBC Comprehensive metabolic panel Total bilirubin ALT and AST Serum creatinine GFR Audiogram

average-risk patients and improve survival in high-risk patients. As such, chemotherapy can be administered adjuvant to radiation therapy or surgery, concurrent with radiation therapy, pre-irradiation in infants to defer radiation therapy and as salvage therapy in relapsed or recurrent disease.

Average-risk patients are those who have minimal volume of non-disseminated disease and no evidence of metastatic spread in head, spine or CSF. Patients with brain stem involvement are also eligible to be labelled average-risk. High-risk patients are those with metastatic medulloblastoma or non-metastatic medulloblastoma with >1.5 cm<sup>2</sup> residual tumor. Those patient with diffusely anaplastic medulloblastoma are categorized as high-risk regardless of metastatic disease or residual tumor.<sup>9</sup>

We recommend three different chemotherapy regimens for treating patients with medulloblastoma, based on their risk status (Table 3). The chemotherapeutic drugs in use are vincristine, cisplatin, lomustine and cyclophosphamide. Each of these drugs can result in various adverse effects. Vincristine can lead to neurotoxicity, hepatotoxicity and jaw pain. Cyclophosphamide and lomustine may cause hematopoietic toxicity, leading to neutropenia and thrombocytopenia. Additionally, hemorrhagic cystitis is a known side effect of cyclophosphamide. Cisplatin may cause nephrotoxicity, manifested by a decrease in creatinine clearance and glomerular filtration rate (GFR), ototoxicity, and hypomagnesemia. Therefore, laboratory monitoring before, during and after the initiation of these chemotherapeutic agents is necessary. A complete blood

**Table-4:** Summary of Recommendations for Pediatric Medulloblastoma.

<b>Radiology</b>	<ul style="list-style-type: none"> <li>• Complete MRI brain and whole spine.</li> <li>• 'Minimum required' MRI brain protocol:               <ul style="list-style-type: none"> <li>o Imaging on at least 0.5T.</li> <li>o Sequences: Axial T2 and coronal or axial FLAIR sequence; pre-contrast T1 and contrast enhanced T1.</li> </ul> </li> <li>• Tumor location, tumor margins, enhancement pattern, tumor size, and presence of hemorrhage/mineralization.</li> <li>• Postoperative MRI is recommended in the first 48 hours after surgery. If delayed by 72 hours, then MRI should be delayed by 3 weeks but not more than 4 weeks.               <ul style="list-style-type: none"> <li>o To identify the extent of resection.</li> <li>o To have a baseline to compare successive imaging.</li> <li>o Not required after biopsy.</li> </ul> </li> </ul>
<b>Neurosurgery</b>	<ul style="list-style-type: none"> <li>• Surgical goals: Resection of tumor and opening of the CSF pathway.</li> <li>• Gross total resection should be attempted where possible. However, in case of tumor adherence to the surrounding critical structures i.e. obex or floor of the fourth ventricle, maximum safe resection should be performed.</li> <li>• Abstain from the VPS as a temporizing procedure unless there is a significant risk of deterioration due to hydrocephalus. Consider referring the patient to a facility where surgical resection can be done along with CSF diversion if needed.</li> <li>• In case of delay in surgical intervention, CSF drainage (VPS or ETV) should be considered.</li> </ul>
<b>Neuropathology</b>	<ul style="list-style-type: none"> <li>• There are 4 subgroups (WNT-activated, SHH-activated, and non-WNT/non-SHH [Group 3 and Group 4]) based on histological subtype and molecular subgrouping.</li> <li>• Hematoxylin and Eosin (H&amp;E) slides to assess histological subtype.</li> <li>• Reticulin stain for evaluating the possibility of Nodular/desmoplastic histological type.</li> <li>• Immunohistochemical panel consisting of GFAP, Olig-2, and Synaptophysin to differentiate Medulloblastoma from gliomas.</li> <li>• GAB1, <math>\beta</math>-catenin, Filamin A, and YAP1 are recommended as a surrogate to molecular studies for differentiating WNT and SHH subgroups from group 3 and group 4.</li> <li>• p53 immunostain is recommended as a surrogate to molecular studies in cases of the SHH group.</li> </ul>
<b>Pediatric Oncology</b>	<ul style="list-style-type: none"> <li>• Three different chemotherapy regimens are</li> </ul>

Continued on next column...

Continued from previous column...

	<p>recommended for treating patients with Medulloblastoma (MB), based on their risk status. *</p> <p><b>Regimen I – Average Risk MB (during radiation)</b></p> <ul style="list-style-type: none"> <li>• Vincristine, a total of 6 doses weekly intervals.</li> </ul> <p><b>Regimen II – Average Risk MB (maintenance)</b></p> <ul style="list-style-type: none"> <li>• Vincristine + Cisplatin + Lomustine, 6 cycles at 28 days intervals.</li> </ul> <p><b>Regimen III – High-Risk MB (maintenance)</b></p> <ul style="list-style-type: none"> <li>• Vincristine + Cisplatin + Cyclophosphamide, 6 cycles at 28 days intervals.</li> </ul>
<b>Radiation oncology</b>	<ul style="list-style-type: none"> <li>• Radiation therapy should begin within four weeks of definitive surgery and should not be delayed beyond 7 weeks.</li> <li>• Standard Dose: Reduced dose CSI 23.4 Gy @ 1.8 Gy per fraction followed by a tumor bed boost 30.6 cGy @ 1.8 Gy per fraction to a total dose of 54 Gy.</li> <li>• High Risk: Standard dose CSI 36 Gy @ 1.8 Gy per fraction followed by posterior fossa boost to a total dose of 54-55.8 Gy.</li> <li>• Craniospinal axis irradiation is complex and requires robust quality assurance processes like peer review for radiation treatment planning and delivery.</li> </ul>
<b>Follow-up</b>	<ul style="list-style-type: none"> <li>• First follow-up at post-op day 10 for wound assessment, stitch removal, discussion related to histopathology, and NOTB recommendations.</li> <li>• Follow-up with serial MRI brain 3 monthly and neuro-axis MRI 6 monthly with a pediatric oncologist.</li> </ul>

MRI: Magnetic resonance imaging, FLAIR: Fluid-attenuated inversion recovery, CSF: Cerebrospinal fluid, VPS: Ventriculoperitoneal shunt, ETV: Endoscopic third ventriculostomy, WNT: Wingless and integrated, SHH: Sonic hedgehog, GFAP: Glial fibrillary acidic protein, GAB1: GRB2 Associated Binding Protein 1, YAP1: Yes-Associated Protein 1, CSI: Craniospinal irradiation, Gy: Gray, NOTB: Neuro-oncology tumor board.

count (CBC) with a differential count should be acquired, and an absolute neutrophil count (ANC) of >1000 and platelet count of >100,000 should be observed before initiating therapy. Total bilirubin levels and alanine transaminase and aspartate transaminase levels should be checked, too. Total bilirubin <1.5 mg/dl and AST and ALT <2.5 times the upper limit of normal are needed to begin therapy. Furthermore, serum creatine and GFR should be monitored. Serum creatine <1.5 mg/dl and GFR > 50 ml/min/m<sup>2</sup> are required to proceed. An audiogram should also be acquired to assess ototoxicity. A comprehensive metabolic panel can alert the physician to any other metabolic derangements.



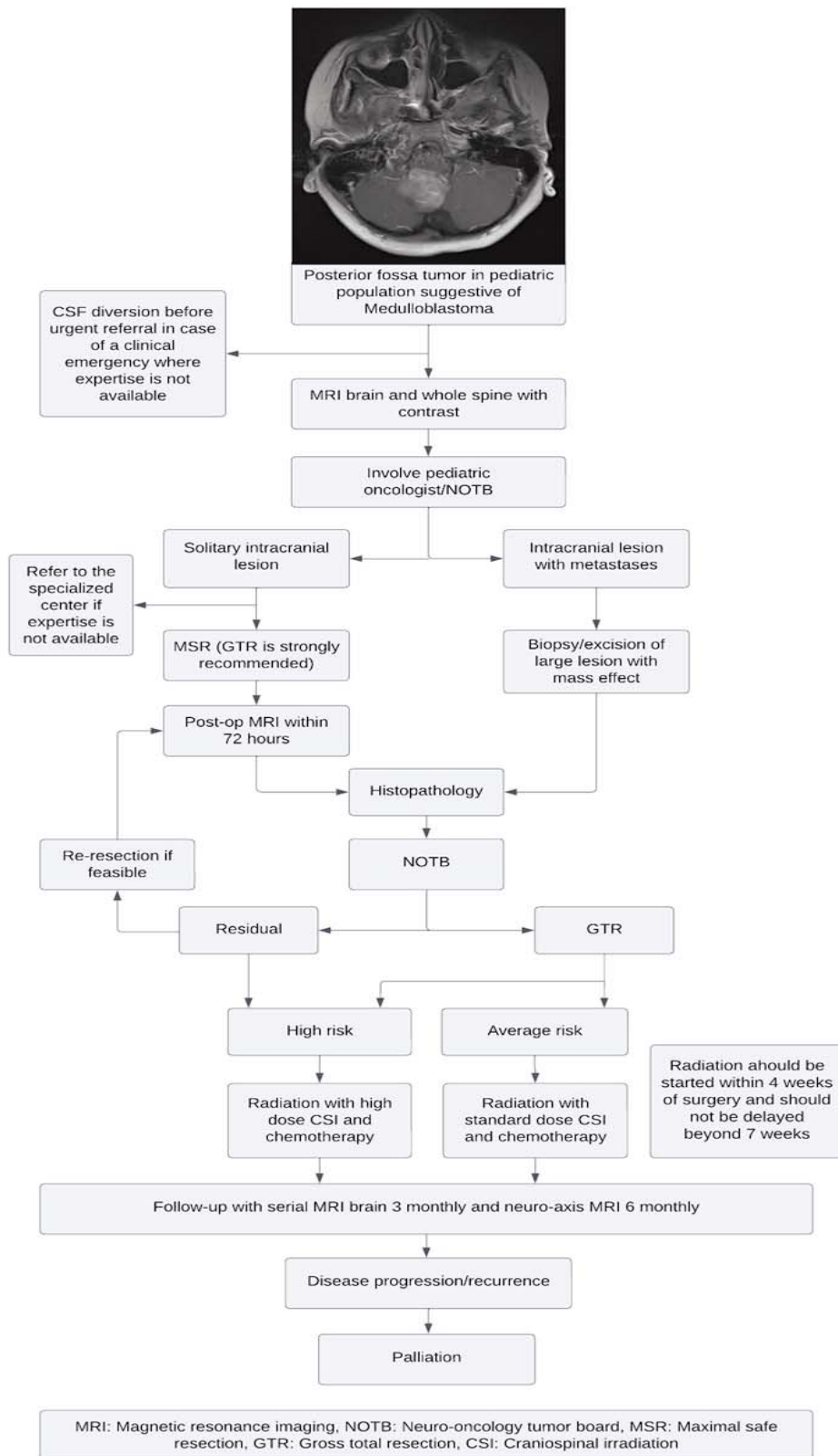


Figure-2: Management of Medulloblastoma algorithm.

## Radiation therapy

Radiation therapy (RT) for medulloblastoma consists of craniospinal axis irradiation (CSI) followed by boost to the primary site. 3D image-based RT treatment planning and computer-controlled delivery systems (conformal radiation therapy) improve disease control and functional outcomes for children with brain tumors. Administration methods include 3D conformal radiation therapy (3D-CRT), intensity modulated radiation therapy (IMRT) and craniospinal radiation therapy.

## Guidelines and requirements for the Use of IMRT

Radiation therapy should begin within four weeks of definitive surgery and should not be delayed beyond 7 weeks. Patients who start radiotherapy beyond 7 weeks of surgery are considered high risk, requiring higher dose of craniospinal irradiation of 36 Gy.

Radiation therapy should be delivered using photons on Linear Accelerator with photon energy less than 6 MV. CT based planning should be done on all patients. Pre-operative and post-operative MRI scans can be used primarily (co-registered with CT planning data) or adjunctively in the treatment planning process. For cranio-spinal and posterior fossa irradiation, the patient may be treated in a prone or supine position. A supine position is preferred for patients being treated under general anesthesia. Immobilization devices such as head holders or custom molds are also recommended. Deep sedation or general anesthesia is generally encouraged for young children. In treatment planning, shielding of critical structures should be considered.

## Supportive Care during Chemotherapy and Irradiation

CBCs should be obtained weekly. Patients who develop a fever greater than 38.5°C should be evaluated for neutropenia and infection. Patients with an ANC < 500/μl or an indwelling catheter require blood cultures and empiric antibiotics. Granulocyte colony stimulating factor (G-CSF) can also be considered according to institutional guidelines. It is recommended that the platelet count be maintained > 30,000/μL. Irradiated and Pall filtered blood products should be used. Transfusions are recommended when hemoglobin falls below 9 gm/dL. The preferred antiemetic is ondansetron. Corticosteroid use as an antiemetic should be avoided if possible. Patients should be started on trimethoprim/sulfamethoxazole (TMP/SMX) at 5mg/kg/day dosed 2-3x/week or per primary care institution's protocol for *Pneumocystis carinii* prophylaxis. Any patient with greater than 10% weight loss should be provided nutritional support either enterally or via a

central venous catheter with parenteral hyperalimentation. All patients should have their magnesium checked prior to each cycle. Endocrine evaluations should be done at diagnosis, completion of radiation therapy, completion of treatment, 6 months following the completion of treatment and then annually unless otherwise indicated.<sup>10</sup>

## Conclusion

These guidelines give recommendations that are needed to fill in the gaps in healthcare when considering pediatric medulloblastoma (Table 4 and Figure 2). Individual practitioners as well as physician groups should remain cognizant of the necessity to properly evaluate and follow up with such patients in order to ensure complete treatment. Guidelines which are "preferred by optional" should be taken into consideration when infrastructure is available. However, our guidelines emphasize crucial recommendations first in order to bridge the gaps the authors have identified in the care of such patients. With the consensus of all stakeholders, there is greater value in providing these comprehensive recommendations, in order to encourage greater focus on multidisciplinary care with LMICs such as Pakistan

## Acknowledgement

The information in this article has been uploaded by the same authors as a preprint on the Pakistan Society of Neuro-oncology website.

**Disclaimer:** None.

**Conflict of Interest:** None.

**Funding Disclosure:** These guidelines are supported by our sponsor, the Sanofi Espoir Foundation, for capacity-building of pediatric neuro-oncology in Pakistan.

## References

1. Baqai MWS, Tariq R, Shah Z, Bajwa MH, Shamim MS. Quality of life in survivors of pediatric medulloblastoma: a systematic review and meta-analysis. *Childs Nerv Syst* 2023;39:1159-71. doi: 10.1007/s00381-023-05886-4.
2. Tariq R, Saeed Baqai MW, Shamim MS. Quality of Life in Paediatric Survivors of Medulloblastoma. *J Pak Med Assoc* 2022;72:2339-40. doi: 10.47391/JPMA.22-111.
3. Bajwa MH, Shah MM, Mustansir F, Gauhar F, Baig E, Zafar SN, et al. A Guideline On Guidelines – Neuro-Oncology Guideline Standards For Low And Middle-Income Countries. *J Pak Med Assoc* 2024;74(Suppl 3):s87-92. Doi: 10.47391/JPMA.S3.GNO-10.
4. Mahapatra S, Amsbaugh MJ. *Medulloblastoma*. Treasure Island, FL: StatPearls Publishing; 2024.
5. Martin AM, Raabe E, Eberhart C, Cohen KJ. Management of pediatric and adult patients with medulloblastoma. *Curr Treat Options Oncol* 2014;15:581-94. doi: 10.1007/s11864-014-0306-4.
6. Orr BA. Pathology, diagnostics, and classification of medulloblastoma. *Brain Pathol* 2020;30:664-78. doi: 10.1111/bpa.12837.
7. Louis DN, Perry A, Reifenberger G, von Deimling A, Figarella-

- Branger D, Cavenee WK, et al. The 2016 World Health Organization Classification of Tumors of the Central Nervous System: a summary. *Acta Neuropathol* 2016;131:803-20. doi: 10.1007/s00401-016-1545-1.
8. Ellison DW, Dalton J, Kocak M, Nicholson SL, Fraga C, Neale G, et al. Medulloblastoma: clinicopathological correlates of SHH, WNT, and non-SHH/WNT molecular subgroups. *Acta Neuropathol* 2011;121:381-96. doi: 10.1007/s00401-011-0800-8.
  9. Ramaswamy V, Remke M, Bouffet E, Bailey S, Clifford SC, Doz F, et al. Risk stratification of childhood medulloblastoma in the molecular era: the current consensus. *Acta Neuropathol* 2016;131:821-31. doi: 10.1007/s00401-016-1569-6.
  10. Heikens J, Michiels EM, Behrendt H, Endert E, Bakker PJ, Fliers E. Long-term neuro-endocrine sequelae after treatment for childhood medulloblastoma. *Eur J Cancer* 1998;34:1592-7. doi: 10.1016/s0959-8049(98)00212-3.
  11. Perreault S, Ramaswamy V, Achrol AS, Chao K, Liu TT, Shih D, et al. MRI surrogates for molecular subgroups of medulloblastoma. *Am J Neuroradiol* 2014;35:1263-9. doi: 10.3174/ajnr.A3990.
  12. Parkes J, Hendricks M, Ssenyonga P, Mugamba J, Molyneux E, Schouten-van Meeteren A, et al. SIOP PODC adapted treatment recommendations for standard-risk medulloblastoma in low and middle income settings. *Pediatr Blood Cancer* 2015;62:553-64. doi: 10.1002/pbc.25313.
- 

**DISCLAIMER**

Articles published in JPMA and Supplements of JPMA do not represent the views of the editor or editorial Board. Authors are solely responsible for the opinions expressed and the accuracy of the data.

The contribution of each author towards the published research included in this supplement is the responsibility of the authors and their institutions. It is expected to be in accordance and compliance with the ICMJE Guidelines.

Any questions/queries raised by readers should be directed to the corresponding author.

## Consensus guidelines for the management of craniopharyngioma in low- and middle-income countries

Syed Ather Enam<sup>1</sup>, Naureen Mushtaq<sup>2</sup>, Muhammad Usman Khalid<sup>3</sup>, Mohammad Hamza Bajwa<sup>4</sup>, Ahsan Ali Khan<sup>5</sup>, Sehar Salim Verani<sup>6</sup>, Anam Tariq<sup>7</sup>, Ahmed Gilani<sup>8</sup>, Bilal Mazhar Qureshi<sup>9</sup>

**Pakistan Brain Tumour Consortium:** Authors list at the end of the supplement.

### Abstract

Craniopharyngiomas are benign, extra-axial epithelial tumours originating from the pituitary stalk, impacting areas such as the hypothalamus, optic chiasm, and various cranial nerves. These tumours present unique surgical challenges due to their proximity to critical neurovascular structures. Management typically involves maximal safe resection as the primary approach. However, in low- and middle-income countries (LMICs), factors like late presentation, higher risks of endocrine and visual complications, frequent recurrence, and potential for incomplete resection complicate treatment. These challenges are exacerbated by limited access to specialised expertise and surgical equipment, increasing the risk of damage during surgery compared to High-Income Countries. This manuscript outlines management guidelines tailored for LMICs, emphasizing that a combination of surgical resection and chemoradiation therapy, as advised by a neuro-oncology tumour board, often yields the best outcomes.

**Keywords:** Craniopharyngioma, optic chiasm, pituitary gland, hypothalamus, neoplasms, glandular, epithelial

**DOI:** <https://doi.org/10.47391/JPMA.S3.GNO-15>

### Introduction

Craniopharyngiomas are extra-axial, benign, epithelial tumours<sup>1</sup> that arise from the pituitary stalk and involve the hypothalamus, pre-chiasmatic cistern, and sub-frontal spaces, third ventricle, foramen magnum, optic chiasm, cranial nerves, sub-temporal spaces, and blood vessels.<sup>2-4</sup> The annual incidence of craniopharyngiomas is around

<sup>1,3-5</sup>Department of Neurosurgery, The Aga Khan University, Karachi, Pakistan.

<sup>2</sup>Department of Paediatric Oncology, The Aga Khan University, Karachi, Pakistan. <sup>6</sup>Department of Surgery, The Aga Khan University Hospital, Karachi, Pakistan. <sup>7</sup>Werribee Mercy Hospital, Melbourne, Victoria, Australia.

<sup>8</sup>Department of Pathology, University of Colorado, Children's Hospital Colorado, USA. <sup>9</sup>Section of Radiation Oncology, The Aga Khan University, Karachi, Pakistan.

**Correspondence:** Syed Ather Enam **Email:** [ather.enam@aku.edu](mailto:ather.enam@aku.edu)

0.5 to 2 cases per million individuals, which represent 1.2-4% of all paediatric intracranial tumours and 13% of all sellar tumours.<sup>5-7</sup> A bimodal age distribution has been reported, with peaks occurring in childhood (5 to 14 years) and adulthood (50 to 75 years). These tumours are more common in Japan and Africa, but no gender predilection has been reported.<sup>8-11</sup>

In low- and middle-income countries (LMICs), the lack of resources and socio-economic imbalance serve as limitations for the management of craniopharyngioma, especially when the tumour can have long term implications on the quality of life of patients.<sup>12-14</sup> Treatment outcomes are also significantly inferior in LMICs as compared to high-income countries.<sup>15</sup> Delayed diagnosis can make the management challenging and complex.<sup>16</sup> Our aim is to formulate guidelines for appropriate diagnosis and management strategies for LMICs such as Pakistan.

### Methodology

The literature search for high-quality data on craniopharyngioma was done in March 2023, on different databases, including PubMed, Google Scholar, Scopus, and Embase. The most relevant and high-quality studies were analysed to develop evidence-based recommendations. An expert panel was convened consisting of specialists and leading experts within the field of neuro-oncology to identify the gaps in the diagnosis and management of craniopharyngioma within Pakistan. This group was tasked with identifying best-practice recommendations and their application within the context of Pakistan as an LMIC. Recommendations were collated, reviewed, and debated regarding utility and evidence-based practices in a process that has been previously detailed.<sup>17</sup>

### Clinical presentation

Craniopharyngiomas usually present with non-specific symptoms such as headache and nausea; however, when the tumour has grown to a size of at least 3 cm, significant symptoms start appearing. These include visual disturbances, endocrine abnormalities, and growth

hormone deficiency.<sup>6, 18</sup> Endocrine abnormalities may include hypothyroidism (characterised by obesity, constipation, lethargy, and cold intolerance), diabetes insipidus (affecting approximately 15% of the patients, with symptoms such as polyuria and polydipsia, indicating the involvement of the infundibulum of the pituitary stalk),<sup>5,14, 19-21</sup> adrenal failure (orthostatic hypotension, hypoglycaemia, hyperkalaemia, cardiac arrhythmias, lethargy, confusion, anorexia, nausea, and vomiting)<sup>1,19</sup> and other issues such as decreased growth rate, obesity, sexual retardation (manifested as decreased libido, impotence, amenorrhoea), and behavioural changes (hyperphagia and emotional immaturity). Headache and visual disturbances occur due to the mass effect of the tumour, secondary to obstructive hydrocephalus, contributing to increased intracranial pressure and damage to the optic chiasm, respectively. Lastly, elderly patients also present with a cognitive decline and somnolence.<sup>1, 5, 10</sup>

After a thorough clinical history, a general and neurological examination should be performed. In the neurological examination, signs suggesting increased intracranial pressure can be identified.<sup>22</sup> Assessment of the visual acuity (using Snellen's chart and Teller grating cards), visual field, colour vision (using the Ishihara test), and fundoscopy to rule out atrophy and oedema is essential.<sup>23</sup> It is recommended to use growth charts specifically in children, to monitor weight, height, body mass index to monitor for growth rate, use of Tanner staging to assess the development of secondary sexual characteristics,<sup>24</sup> and an evaluation for signs of other hormonal abnormalities, such as oedema, anaemia, altered mental function, orthostatic hypotension, etc.<sup>25</sup>

## Initial workup

### Neuro radiology

Craniopharyngiomas have a heterogeneously enhancing radiological appearance. They most commonly manifest as suprasellar lesions with diverse development patterns and with intrasellar extension. Childhood craniopharyngiomas show intra-tumoural calcifications and a solid and cystic component.<sup>26-30</sup> A lack of calcification can be confusing; hypothalamic low-grade glioma and suprasellar germ cell tumours are the main radiological differential diagnosis. In this case, a biopsy or resection is necessary for a diagnosis.<sup>14</sup>

Only 20% of the tumours are entirely suprasellar, with predominantly intrasellar lesions are present in less than 5%.<sup>29</sup> They typically surround neurovascular systems in the interpeduncular and suprasellar cisterns and may present as totally solid lesions or have an accompanying

cystic component. In adults, they often develop posterior to the chiasm in adults and extend back into the third ventricle.<sup>27</sup>

Adamantinomatous craniopharyngiomas typically appear as cystic lesions with or without a solid component on a computerised tomography (CT) scan. With discernible calcifications, they display a nodular enhancement in solid lesions and a rim-like enhancement in cystic lesions. In comparison to the surrounding brain, the mixed tumours appear hypodense on a CT scan. However, because of the high protein concentration, the fluid inside the cysts appears hyper-dense. CT scans are also useful to determine the degree of skull base involvement such as erosion of the sella turcica. Papillary craniopharyngiomas usually appear as solid, are infrequently calcified, and display homogenous contrast enhancement with a thickened pituitary stalk. They infrequently occur as purely intrasellar lesions and are often suprasellar or within the third ventricle.<sup>27, 30</sup>

On T2-weighted images of magnetic resonance imaging (MRI), cysts appear as hyperintense lesions due to their high protein content, whilst the solid components are nodular. The solid lesions appear as iso- and hypo-intense on T1-weighted images and show a variable appearance on T2.

On contrast MRI, the solid part of a craniopharyngioma and the cyst wall typically show more significant enhancement than a pituitary adenoma or the normal gland. To assess the relationship between the tumour and the critical vascular structures, magnetic resonance angiography (MRA) can be useful. Specific elevated peaks of lactate and lipids on magnetic resonance spectroscopy (MRS) differentiate them from the gliomas and pituitary adenomas.<sup>14, 28</sup>

### Practical applications to assessment and preoperative planning

Evaluation of the tumour's involvement of the hypothalamus in the pre-operative MRI is essential. It aids in predicting and reducing postoperative hypothalamic morbidity and serves as a key determinant of the extent of resection as pre-operative hypothalamic involvement is recognized as a poor prognostic factor. For diagnostic and surgical planning, both MRI (T1/T2/flair sequences) and CT scans are ideal. T2 weighted MRI sequences are helpful for determining how the tumour interacts with adjacent structures, particularly the optic chiasm, mammillary body, and the third ventricle floor. These sequences are also useful to quantify the size of the tumour and the perilesional edema.<sup>27</sup> Diffusion tensor imaging tractography allows for visualization of the

hypothalamo-hypophyseal pathways.<sup>14, 27</sup>

To prepare for an endoscopic approach, a CT scan is useful for delineating the cystic sections of the tumour and skeletal features including bone erosion, hyperostosis, sphenoid sinus pneumatization, and septations. When there is a strong suspicion of venous or arterial involvement or when selecting the best surgical strategy in cases of potential problems with the cerebral or cranial base vasculature, a CT angiography can be added.

Evaluating visual function is an essential component of the diagnosis, follow-up, and prognosis of craniopharyngiomas is the evaluation of the visual function. It is crucial to carefully assess the papilloedema, optic nerve atrophy, visual field abnormalities, and visual acuity. Optical coherence tomography is an effective approach for assessing visual impairment and predicting vision recovery. The majority of craniopharyngioma patients present with anterior panhypopituitarism. Therefore, a complete endocrinological assessment is required to reach a diagnosis.<sup>27</sup>

Pituitary hormone deficiencies are present in more than 80% of children at the time of diagnosis, and additional deficiencies can develop during or after treatment. Thus, even in the absence of clinical signs, pituitary function should be assessed in all sellar/suprasellar lesions.<sup>27</sup> Assessment should include each hypothalamic-pituitary dependent hormonal axis should be evaluated including serum TSH, ACTH, morning cortisol, free T4, HGH, IGF-1, prolactin, LH, FSH, progesterone, estradiol, and testosterone levels. Evaluation of serum sodium levels, urinary specific gravity and osmolarity is important to rule out diabetes insipidus, which is seen in 10-20% of the patients.<sup>14, 27</sup> Additionally, the evaluation of visual acuity, color vision, visual field, and optic nerve discs is crucial.<sup>14</sup>

### **Surgical management**

The treatment of craniopharyngioma is challenging due to its location and involvement of the surrounding neurovascular structures. In LMICs, challenges such as late presentation, high risk of endocrine and visual complications, high recurrence rate, risk of incomplete resection, limited expertise, and surgical equipment, and the risk of damage to the surrounding structures during surgery are relatively higher than in HICs.<sup>31-33</sup> Surgical complications include diabetes insipidus, hypothalamic obesity, and visual disturbances secondary to damage to the hypothalamic stalk or optic chiasm.<sup>1, 2, 12, 13</sup>

Treatment options include surgery, radiotherapy, and intracystic therapy. The goal of surgery is to achieve safe

tumour resection, without causing further harm.<sup>34</sup> Surgical management options for craniopharyngioma include gross total resection (GTR) and subtotal resection (STR) followed by local radiation.<sup>35</sup> GTR refers to the maximal removal (95%) of the tumour. STR involves removing the tumour to the extent that it does not cause any iatrogenic complication. STR is often paired with radiotherapy to manage the part of the tumour left behind and avoid recurrences.<sup>36</sup> A review of the literature indicates that when compared with STR alone, GTR had better outcomes in terms of tumour control; however, when STR was combined with radiotherapy, it showed better outcomes as compared to GTR alone.<sup>37</sup> The literature mentions various surgical approaches for craniopharyngiomas. The selection of a surgical approach depends upon the location of the craniopharyngioma and its involvement of surrounding structures. There are two major approaches: open and endoscopic endonasal. Open approaches (craniotomy) include anteromedial, anterolateral, lateral, and intraventricular (transcortical and transcallosal) approaches. The trans-sphenoidal approach refers to the endoscopic endonasal approach (EEA), which has recently emerged in the last few decades as the preferred approach associated with its benefits.<sup>38, 39</sup>

Studies in the literature show various studies that prefer an endoscopic endonasal approach (EEA) over a transcranial approach. EEA offers better visualisation without the need to retract the brain or disrupt surrounding structures, giving direct access to the site where the tumour is located. Specifically, the tumours with a residual lesion and ones with retro-sellar interpeduncular extensions have been found to show better outcomes with EEA.<sup>40</sup> Compared to the transcranial approach, the endoscopic endonasal approach has been shown to achieve gross total resection more frequently, reduced recurrences, a lower increase in FLAIR signals postoperatively,<sup>40</sup> improvements in vision<sup>26, 41, 42</sup> and fewer complications such as cognitive loss, pseudoaneurysm,<sup>26</sup> new endocrinopathies,<sup>42</sup> seizures<sup>41</sup> and asymptomatic meningitis.<sup>43</sup> Patients undergoing open TCA needed adjuvant radiation and were associated with poor prognosis with a higher incidence of postoperative ischaemia, weight gain,<sup>26</sup> and longer length of hospitalization than EEA.<sup>44</sup> The extent of resection is also comparable in both approaches.<sup>42</sup> Additionally, EEA with a 3-dimensional view allows for better hand-eye coordination and perception of depth. Robotic-assisted EEA is the current area of practice that is being tested in different settings to compare its outcomes with other strategies.<sup>45</sup> However, it has also been noted that the endoscopic endonasal approach should be

avoided in lesions that grow into the middle cranial fossa just adjacent to the internal carotid artery,<sup>40</sup> and EEA results in increased and more frequent CSF leakage than TCA,<sup>41</sup> which requires further management.<sup>38</sup>

Lastly, for the management of hydrocephalus and increased intracranial pressure, surgical debulking or intracystic therapy is usually sufficient; however, in some cases, a pre-operative ventriculoperitoneal shunt, external ventricular drain or endoscopic septostomy may help delay surgery in paediatric populations.<sup>46</sup>

Several factors influence the decision to develop a strategy for the management of craniopharyngioma. In LMICs, the availability of expertise and resources such as surgical instruments, imaging modalities, intensive care units, radiotherapy facilities, intracystic treatment options, and support systems for the long-term management of the disease contributes to the challenge of treating a patient effectively. Therefore, a multidisciplinary approach needs to be considered for deciding management.<sup>16, 47</sup>

## Pathological assessment

### Histopathology

The World Health Organization (WHO) classifies craniopharyngiomas into two distinct etiologies, Adamantinomatous craniopharyngioma and Papillary craniopharyngiomas. They are mostly found in the suprasellar region, attached to the underlying tissue.<sup>28</sup> Adamantinomatous craniopharyngiomas are usually solid, multilobulated nodules with trabeculae of squamous epithelium bordered by columnar epithelium and abundant calcifications. On histological examination, three components are classically present: keratinizing epithelial cells often with lining of nuclei along the periphery (referred to as 'palisading' appearance), a middle layer made up of loose stellate cells, and fully keratinized epithelial cells with homogenous eosinophilic cytoplasm and degenerated/ empty nuclei (referred to as 'ghost' cells). These cells aggregate into circular bodies called 'wet' keratin (to distinguish from the 'dry' flaky keratin present in dermoid/ epidermoid cysts). Calcification of keratin is often seen. The presence of desquamated epithelial cells and cholesterol in the cyst fluid gives it a distinctive 'motor oil' appearance. Additionally, adamantinomatous craniopharyngiomas tend to adhere strongly to the surrounding tissues, which complicates complete surgical excision.<sup>28,30</sup> Histologically, the surrounding brain can show extensive gliosis with the formation of Rosenthal fibers, often making it indistinguishable from Pilocytic astrocytoma.

On the other hand, papillary craniopharyngiomas

resemble the metaplastic respiratory epithelium with a pseudopapillary structure of the epithelial cells. They are lined by ciliated squamous epithelium and goblet cells lacking surface maturation. Unlike adamantinomatous craniopharyngiomas, they arise due to the somatic mutation and lack ghost cells, and 'wet' keratin nodules.<sup>14, 26</sup> The most common biopsy techniques historically have been skull-base or image-guided needle biopsy; more recently, endoscopic transnasal biopsy has gained popularity.<sup>30</sup>

### Molecular pathology

CTNNB1 mutations are characteristic of adamantinomatous craniopharyngiomas. The beta-catenin gene coding for CTNNB1 is an adherent junctional protein and is important for the signaling of the WNT pathway. The WNT pathway recognized to control cell division, play a role in tissue formation, and embryology. Disruption leads to uncontrolled proliferation and there is associated with many neoplastic diseases. The mutated CTNNB1 protein is not phosphorylated and hence accumulates in the nucleus promoting the cell proliferation. B-catenin immunohistochemical stain can be used to test for nuclear localisation and can be used to differentiate craniopharyngiomas from other sellar tumours.

Papillary craniopharyngiomas are less invasive, have high recurrence rate and are characterised by BRAF and V600E mutations, which cause activation of the mitogen-activated protein kinase (MAPK) pathway and uncontrolled proliferation of the cells.<sup>28</sup>

### Adjuvant treatment Radiation therapy

Radiotherapy can control localised craniopharyngiomas after sub-total resection with an 80–85% success rate.<sup>48</sup> Recently a hypothalamus-sparing surgical approach followed by localised conventionally fractionated radiotherapy has become popular due to the significant complications following radical treatment. Radical excision should not be performed for larger adherent lesions evaluated in accordance with developing criteria; Radiation therapy after partial resection may slow down tumour growth without causing hypothalamic dysfunction.<sup>49, 50</sup> Recurrent, residual, and partially excised tumours are treated with radiotherapy. A 90% 10-year progression-free survival rate is seen with radiotherapy.<sup>50</sup>

Factors favouring postoperative localized radiotherapy include larger tumour size at presentation (which is > 2-4 cm) preoperative hypothalamic involvement, hydrocephalus, and younger age of the patient, since

complete surgical excision is not always attainable in these circumstances.<sup>14, 51, 52</sup> Adjuvant radiotherapy is not recommended for individuals with complete excision unless tumour regrowth occurs during follow-up and in children less than 5 years of age.<sup>14, 48, 53</sup>

Postoperative radiotherapy can have some adverse effects later in life.<sup>48</sup> Neurocognitive and neuropsychological impairment, visual deficiencies, endocrinopathies, eating issues, and sleep difficulties are some of the side effects of radiation. Due to pre-existing endocrine deficiencies at the time of diagnosis or after surgery, it is challenging to estimate the precise incidence of post-radiation endocrinopathies from the literature. The most likely affected hormone is growth hormone, while thyroxine is the most radio-resistant.<sup>53</sup> The idea that the hypothalamus is more radiosensitive to the effects of radiation than nearby pituitary tissue is supported by literature, which shows that a radiation dose of 27 Gray (Gy) to any volume of the hypothalamus increased the chance of endocrinopathy by a factor of four.<sup>28, 54</sup> Relatively few patients experience DI and hypopituitarism after restricted surgery and radiotherapy.<sup>48</sup>

Highly conformal radiation treatment planning and delivery using intensity modulated radiation technique IMRT or volumetric modulated arc therapy (VMAT) capable linear accelerators have replaced cobalt machines.<sup>14</sup> Recent advancements in radiation therapy techniques, like stereotactic radiation therapy for precise immobilisation and proton beam radiation therapy, may be able to lower the radiation dose to healthy brain tissue further while still providing effective local control.<sup>26</sup> A Multidisciplinary approach involving all stakeholders, including paediatric neurosurgeons and medical and radiation oncologists, is required for maximum clinical outcomes, and peer review is an essential step or component of this critical process.

A total dose of at least 54 Gy in 30 fractions of 1.8 Gy per fraction is recommended. Treatment shall be delivered with daily image guidance, five days a week, once daily. There is evidence suggesting better control with dose escalation.<sup>27, 28</sup> Hypofractionated treatment like stereotactic radiosurgery (SRS) is not recommended there is a special situation of very small size residual disease.

### **Intracystic/systemic therapy**

Cystic tumours that have gone untreated or that have progressed following prior treatment can benefit from intracystic therapy, especially in children under the age of five.<sup>14</sup> After maintaining the integrity of the cyst wall, intracystic interferon-alpha may also be a therapy option for primary cystic lesions to prevent the need for

alternative therapies depending upon the availability.<sup>26</sup> With an Ommaya or Rickham catheter, intracavitary agents can be instilled to treat cystic recurrences. The use of intracystic Bleomycin is not recommended due to the potential of significant neurological complications.<sup>14</sup> The most widely used agent is INF alpha.

Although systemic therapy is typically not used, a limited series has demonstrated that using subcutaneous peginterferon alpha-2b to treat cystic recurrences can produce long-lasting results.<sup>14</sup> The availability of reservoir catheters or INF treatments, pharmacological pricing, and neurosurgeon experience are the main obstacles to intracystic therapy in LMIC.<sup>14</sup>

### **Post-operative management and follow-up**

Post-operative care for craniopharyngioma can be quite intensive as the risk of developing diabetes insipidus, syndrome of inappropriate antidiuretic hormone secretion (SIADH), and cerebral salt wasting is very high. Constant monitoring of the patient for fluid balance, electrolyte and urea levels, and serum osmolality, preferably in PICU/ICU, is recommended. Postoperative antibiotic administration should include a fourth-generation cephalosporin, vancomycin, or trimethoprim-sulfamethoxazole for the first 24 to 48 hours post-surgery.<sup>40</sup> Long-term regular follow-up in clinics for examination for visual and neurologic deficits and endocrine abnormalities is recommended.<sup>55</sup>

### **Prognosis/quality of life/recurrence**

The rate of recurrence is 20–27%. Ten-year progression-free survival has been reported at 84–100% when patients undergo limited surgical resection followed by radiotherapy.<sup>11</sup> Management for recurrent craniopharyngiomas is more challenging and depends upon the patient's age at the time of recurrence and the extent of the tumour.<sup>37</sup> However, in patients who show progression of the disease only on imaging without clinical manifestations, careful observation on a regular basis is suggested. A repeat surgery increases the risk of morbidity and mortality secondary to the disruption of normal anatomical planes from previous surgery due to scarring making dissection more difficult, compounded with recurrent tumours being more closely attached to important neurovascular structures.<sup>41, 56</sup>

Some sources suggest that patients with craniopharyngioma should be offered a surgical treatment in recurrent presentation, and radiation therapy should be offered only when the second surgery fails to produce favourable outcomes.<sup>41</sup> There is conflicting evidence for a favourable approach for treating recurrent craniopharyngioma. While some



**Table-1:** Summary of Recommendations for Craniopharyngioma.

<b>Initial Evaluation</b>	<p><b>Radiology</b></p> <ul style="list-style-type: none"> <li>• MRI brain with and without contrast.</li> <li>• 'Minimum required' MRI brain protocol:             <ul style="list-style-type: none"> <li>o Imaging on at least 0.5T</li> <li>o Sequences: Axial and coronal T2 and coronal or axial FLAIR sequence; pre-contrast T1 and contrast-enhanced T1.</li> </ul> </li> <li>• CTA/MRA is recommended if there is significant lateral and posterior extension and involvement of major vessels.</li> <li>• Tumour size, location, margins, enhancement pattern, presence of mineralisation, relation with the chiasm, hypothalamus, pituitary gland and stalk, and third ventricle.</li> <li>• Postoperative MRI is recommended after 3 months.             <ul style="list-style-type: none"> <li>o To identify the extent of resection.</li> <li>o To have a baseline to compare successive imaging.</li> <li>o Not required after biopsy.</li> </ul> </li> </ul> <p><b>Endocrine evaluation</b></p> <p><b>Ophthalmology assessment</b></p> <ul style="list-style-type: none"> <li>• Visual acuity, perimetry, OCT, and fundoscopy are recommended.</li> </ul>
<b>Neurosurgery</b>	<ul style="list-style-type: none"> <li>• Surgical goals: Maximal safe resection of tumour.</li> <li>• Ommaya insertion with or without biopsy is advised in cystic lesion with high surgical risk.</li> <li>• Small asymptomatic lesions can be followed with serial MRI.</li> <li>• Redo surgery can be considered in case of recurrence/disease progression after risk stratification in NOTB.</li> </ul>
<b>Neuropathology</b>	<ul style="list-style-type: none"> <li>• Haematoxylin and eosin (H&amp;E) preparation for histological typing.</li> </ul>
<b>Medical and Radiation Oncology</b>	<ul style="list-style-type: none"> <li>• Follow regional NOTB recommendations for chemotherapy.</li> <li>• Radiation therapy is recommended after STR for residual disease or recurrence after GTR.</li> <li>• Shall be avoided in children less than 10 years old.</li> <li>• Other factors that warrant radiotherapy include preoperative hypothalamic involvement, hydrocephalus, and younger age of the patient since complete surgical excision is not always attainable in these circumstances.</li> <li>• Radiation therapy is delivered 54 Gy over 30 fractions with conventional fractionation using a highly conformal treatment delivery technique. IMRT/VMAT is preferred over 3D-CRT.</li> </ul>

Continued on next column...

Continued from previous column...

- |                  |   |
|------------------|---|
| <b>Follow-up</b> | <ul style="list-style-type: none"> <li>• First follow-up at post-op day 10 for wound assessment, stitch removal, discussion related to histopathology, and NOTB recommendations.</li> <li>• Clinical follow-up with MRI after 3 months, then 6 monthly with a paediatric oncologist and endocrinologist.</li> </ul> |
|------------------|---|

MRI: Magnetic resonance imaging, FLAIR: Fluid-attenuated inversion recovery, CTA: Computed tomography angiography, MRA: Magnetic resonance angiograms, OCT: Optical coherence tomography, NOTB: Neuro-oncology tumour board, STR: Subtotal resection, GTR: Gross total resection, IMRT: Intensity-modulated radiation therapy, VMAT: Volumetric modulated arc therapy, 3D-CRT: Three-dimensional conformal radiation therapy.

studies prefer gross total resection, there are others that show that subtotal resection followed by radiation therapy leads to better outcomes. However, radiation therapy is also associated with complications such as cognitive deficits, vasculopathy, and the development of a secondary tumour.<sup>41</sup>

Craniopharyngioma can itself present with endocrine abnormalities. However, it may also be a result of the treatment (surgery, radiosurgery, radiotherapy).<sup>37</sup> There is significant evidence of hypothalamic dysfunction, obesity, neurocognitive decline, reduced quality of life, and mortality occurring secondary to the treatment.<sup>56, 57</sup>

### Gaps in knowledge

In LMICs, the unavailability of a multidisciplinary team in tertiary care centers is the most important impediment of better management in patients with craniopharyngioma.<sup>58</sup> Further, the lack of resources such as proper pre-surgical care facilities and imaging modalities, surgical equipment, post-surgical intensive care units further increase the burden of management. Delayed presentation and massive tumour burden also leads to poor outcomes due to significant post treatment complications. No insurance and unavailability of tertiary care centers with multidisciplinary teams will make it difficult for families and patients to continue regular follow ups.<sup>59, 60</sup> All these factors have contributed to a limited literature on the outcomes and management of craniopharyngioma, especially from LMICs.

### Conclusion

Created to assist doctors practicing in areas with limited resources, these guidelines offer a pragmatic framework derived from valuable expertise (refer to Table 1 and Figure 1). Applying these guidelines could substantially enhance specific results and encourage a greater focus on collaborative care in low- and middle-income countries (LMICs) like Pakistan.

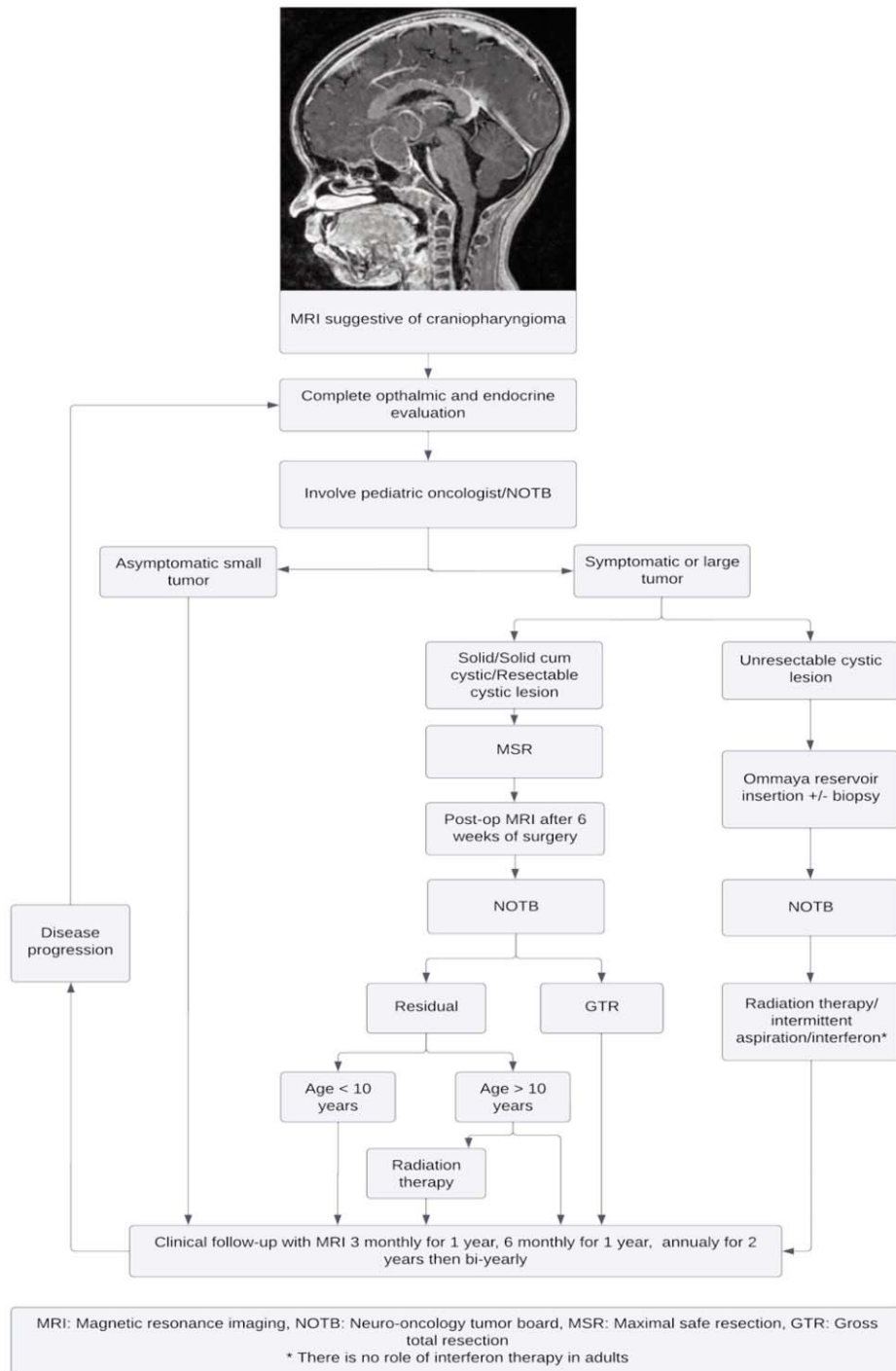


Figure-1: Management of craniopharyngioma algorithm.

**Disclaimer:** None.

**Conflict of Interest:** None.

**Funding Disclosure:** None.

**References**

1. Garnett MR, Puget S, Grill J, Sainte-Rose C. Craniopharyngioma. Orphanet J Rare Dis 2007;2:18. doi: 10.1186/1750-1172-2-18
2. Ortiz Torres M, Shafiq I, Mesfin FB. Craniopharyngioma. Treasure Island, FL: StatPearls Publishing; 2024.
3. Lithgow K, Hamblin R, Pohl U, Karavitaki N. Craniopharyngiomas.

- In: Feingold KR, Anawalt B, Blackman MR, Boyce A, Chrousos G, Corpas E, eds. *Endotext*. South Dartmouth, MA: MDText.com, Inc; 2000.
4. Prieto R, Rosdolsky M, Hofecker V, Barrios L, Pascual JM. Craniopharyngioma treatment: an updated summary of important clinicopathological concepts. *Expert Rev Endocrinol Metab* 2020;15:261-82. doi: 10.1080/17446651.2020.1770081
  5. Jane JA Jr, Laws ER. Craniopharyngioma. *Pituitary* 2006;9:323-6. doi: 10.1007/s11102-006-0413-8
  6. Müller HL. Craniopharyngioma. *Endocr Rev* 2014;35:513-4. doi: 10.1210/er.2013-1115
  7. Müller HL. The Diagnosis and Treatment of Craniopharyngioma. *Neuroendocrinol* 2020;110:753-66. Doi: 10.1159/000504512
  8. Stamm AC, Vellutini E, Balsalobre L. Craniopharyngioma. *Otolaryngol Clin North Am* 2011;44:937-52. doi: 10.1016/j.otc.2011.06.015
  9. Zoicas F, Schöfl C. Craniopharyngioma in adults. *Front Endocrinol (Lausanne)* 2012;3:46. doi: 10.3389/fendo.2012.00046
  10. Müller HL, Merchant TE, Warmuth-Metz M, Martinez-Barbera JP, Puget S. Craniopharyngioma. *Nat Rev Dis Primers* 2019;5:75. doi: 10.1038/s41572-019-0125-9
  11. Zacharia BE, Bruce SS, Goldstein H, Malone HR, Neugut AI, Bruce JN. Incidence, treatment and survival of patients with craniopharyngioma in the surveillance, epidemiology and end results program. *Neuro Oncol* 2012;14:1070-8. doi: 10.1093/neuonc/nos142
  12. Ortiz Torres M, Shafiq I, Mesfin FB. *Pediatric Craniopharyngioma*. Treasure Island FL: StatPearls Publishing; 2024.
  13. Lara-Velazquez M, Mehkri Y, Panther E, Hernandez J, Rao D, Fiester P, et al. Current Advances in the Management of Adult Craniopharyngiomas. *Curr Oncol* 2022;29:1645-71. doi: 10.3390/curroncol29030138
  14. Amayiri N, Spitaels A, Zaghoul M, Figaji A, Cavalheiro S, Muller HL, et al. SIOP PODC-adapted treatment guidelines for craniopharyngioma in low- and middle-income settings. *Pediatr Blood Cancer* 2023;70:e28493. doi: 10.1002/pbc.28493
  15. Gupta T, Achari R, Chatterjee A, Chen ZP, Mehta M, Bouffet E, et al. Comparison of Epidemiology and Outcomes in Neuro-Oncology Between the East and the West: Challenges and Opportunities. *Clin Oncol (R Coll Radiol)* 2019;31:539-48. doi: 10.1016/j.clon.2019.05.018
  16. Amayiri N, Swaidan M, Yousef Y, Halalshah H, Abu-Hijlij R, Kalaldeh S, et al. Review of management and morbidity of pediatric craniopharyngioma patients in a low-middle-income country: a 12-year experience. *Childs Nerv Syst* 2017;33:941-50. doi: 10.1007/s00381-017-3411-4
  17. Bajwa MH, Shah MM, Mustansir F, Gauhar F, Baig E, Zafar SN, et al. A Guideline On Guidelines – Neuro-Oncology Guideline Standards For Low And Middle-Income Countries. *J Pak Med Assoc* 2024;74(Suppl 3):s87-92. Doi: 10.47391/JPMA.S3.GNO-10.
  18. Di Iorgi N, Morana G, Cappa M, D'Incerti L, Garrè ML, Grossi A, et al. Expert Opinion on the Management of Growth Hormone Deficiency in Brain Tumor Survivors: Results From an Italian Survey. *Front Endocrinol (Lausanne)* 2022;13:920482. doi: 10.3389/fendo.2022.920482
  19. Wang L, Ni M, Jia W, Jia G, Du J, Li G, et al. Primary adult infradiaphragmatic craniopharyngiomas: clinical features, management, and outcomes in one Chinese institution. *World Neurosurg* 2014;81:773-82. doi: 10.1016/j.wneu.2013.02.011
  20. Huang CC, Lin KL, Wu CT, Jung SM, Wang CJ, Chen YC, et al. Clinical and endocrinological manifestations of childhood-onset craniopharyngioma before surgical removal: A report from one medical center in Taiwan. *Pediatr Neonatol* 2021;62:181-6. doi: 10.1016/j.pedneo.2020.08.014
  21. Chen Y, Hu F, Wang J, Huang K, Liu W, Tan Y, et al. Clinical Features of Craniopharyngioma With Tumoral Hemorrhage: A Retrospective Case-Controlled Study. *Front Surg* 2022;9:845273. doi: 10.3389/fsurg.2022.845273
  22. Yu J. Endocrine disorders and the neurologic manifestations. *Ann Pediatr Endocrinol Metab* 2014;19:184-90. doi: 10.6065/apem.2014.19.4.184
  23. Jariyakosol S, Peragallo JH. The Effects of Primary Brain Tumors on Vision and Quality of Life in Pediatric Patients. *Semin Neurol* 2015;35:587-98. doi: 10.1055/s-0035-1563571
  24. Crafa A, Condorelli RA, Cannarella R, Aversa A, Calogero AE, La Vignera S. Physical Examination for Endocrine Diseases: Does It Still Play a Role? *J Clin Med* 2022;11:2598. doi: 10.3390/jcm11092598
  25. González Briceño LG, Kariyawasam D, Samara-Boustani D, Giani E, Beltrand J, Bolle S, et al. High Prevalence of Early Endocrine Disorders After Childhood Brain Tumors in a Large Cohort. *J Clin Endocrinol Metab* 2022;107:e2156-6. doi: 10.1210/clinem/dgab893
  26. PDQ Pediatric Treatment Editorial Board. Childhood Craniopharyngioma Treatment (PDQ®): Health Professional Version. In: PDQ Cancer Information Summaries. Bethesda, MD: National Cancer Institute (US); 2002–2023.
  27. Varlotto JM, Flickinger JC, Kondziolka D, Lunsford LD, Deutsch M. External beam irradiation of craniopharyngiomas: long-term analysis of tumor control and morbidity. *Int J Radiat Oncol Biol Phys* 2002;54:492-9. doi: 10.1016/s0360-3016(02)02965-6
  28. Habrand JL, Ganry O, Couanet D, Rouxel V, Levy-Piedbois C, Pierre-Kahn A, et al. The role of radiation therapy in the management of craniopharyngioma: a 25-year experience and review of the literature. *Int J Radiat Oncol Biol Phys* 1999;44:255-63. doi: 10.1016/s0360-3016(99)00030-9
  29. Cossu G, Jouanneau E, Cavallo LM, Elbabaa SK, Giammattei L, Starnoni D, et al. Surgical management of craniopharyngiomas in adult patients: a systematic review and consensus statement on behalf of the EANS skull base section. *Acta Neurochir (Wien)* 2020;162:1159-77. doi: 10.1007/s00701-020-04265-1
  30. Drapeau A, Walz PC, Eide JG, Rugino AJ, Shaikhouni A, Mohyeldin A, et al. Pediatric craniopharyngioma. *Childs Nerv Syst* 2019;35:2133-45. doi: 10.1007/s00381-019-04300-2
  31. Müller HL. Childhood craniopharyngioma. *Pituitary* 2013;16:56-67. doi: 10.1007/s11102-012-0401-0
  32. Kaltsas GA, Kolomodi D, Randevara H, Grossman A. Nonneuroendocrine Neoplasms of the Pituitary Region. *J Clin Endocrinol Metab* 2019;104:3108-23. doi: 10.1210/jc.2018-01871
  33. Asha MJ, Oswari S, Takami H, Velasquez C, Almeida JP, Gentili F. Craniopharyngiomas: Challenges and Controversies. *World Neurosurg* 2020;142:593-600. doi: 10.1016/j.wneu.2020.05.172
  34. Zada G, Laws ER. Surgical management of craniopharyngiomas in the pediatric population. *Horm Res Paediatr* 2010;74:62-6. doi: 10.1159/000309349
  35. Müller HL. Consequences of craniopharyngioma surgery in children. *J Clin Endocrinol Metab* 2011;96:1981-9. doi: 10.1210/jc.2011-0174
  36. Laprie A, Hu Y, Alapetite C, Carrie C, Habrand JL, Bolle S, et al. Paediatric brain tumours: A review of radiotherapy, state of the art and challenges for the future regarding protontherapy and carbontherapy. *Cancer Radiother* 2015;19:775-89. doi: 10.1016/j.canrad.2015.05.028
  37. Murphy ES, Chao ST, Angelov L, Vogelbaum MA, Barnett G, Jung E, et al. Radiosurgery for Pediatric Brain Tumors. *Pediatr Blood Cancer* 2016;63:398-405. doi: 10.1002/pbc.25831
  38. Grewal MR, Spielman DB, Safi C, Overvest JB, Otten M, Bruce J, et al. Gross Total Versus Subtotal Surgical Resection in the Management of Craniopharyngiomas. *Allergy Rhinol (Providence)* 2020;11:2152656720964158. doi: 10.1177/2152656720964158

39. Yang I, Sughrue ME, Rutkowski MJ, Kaur R, Ivan ME, Aranda D, et al. Craniopharyngioma: a comparison of tumor control with various treatment strategies. *Neurosurg Focus* 2010;28:E5. doi: 10.3171/2010.1.FOCUS09307
40. Drapeau A, Walz PC, Eide JG, Rugins AJ, Shaikhouni A, Mohyeldin A, et al. Pediatric craniopharyngioma. *Childs Nerv Syst* 2019;35:2133-45. doi: 10.1007/s00381-019-04300-2
41. Turel MK, Tsermoulas G, Gonen L, Klironomos G, Almeida JP, Zadeh G, et al. Management and outcome of recurrent adult craniopharyngiomas: an analysis of 42 cases with long-term follow-up. *Neurosurg Focus* 2016;41:E11. doi: 10.3171/2016.9.FOCUS16299
42. Moussazadeh N, Prabhu V, Bander ED, Cusic RC, Tsiouris AJ, Anand VK, et al. Endoscopic endonasal versus open transcranial resection of craniopharyngiomas: a case-matched single-institution analysis. *Neurosurg Focus* 2016;41:E7. doi: 10.3171/2016.9.FOCUS16299
43. Komotar RJ, Starke RM, Raper DM, Anand VK, Schwartz TH. Endoscopic endonasal compared with microscopic transsphenoidal and open transcranial resection of craniopharyngiomas. *World Neurosurg* 2012;77:329-41. doi: 10.1016/j.wneu.2011.07.011
44. O'steen L, Indelicato DJ. Advances in the management of craniopharyngioma. *F1000Res* 2018;7:F1000 Faculty Rev-1632. doi: 10.12688/f1000research.15834.1
45. Cavallo LM, Solari D, Esposito F, Villa A, Minniti G, Cappabianca P. The role of the endoscopic endonasal route in the management of craniopharyngiomas. *World Neurosurg* 2014;82:S32-40. doi: 10.1016/j.wneu.2014.07.023
46. Ozgural O, Kahilogullari G, Dogan I, Al-Beyati ESM, Bozkurt M, Tetik B, et al. Single-Center Surgical Experience of the Treatment of Craniopharyngiomas With Emphasis on the Operative Approach: Endoscopic Endonasal and Open Microscopic Transcranial Approaches. *J Craniofac Surg* 2018;29:e572-8. doi: 10.1097/SCS.00000000000004592
47. Takami H, Velásquez C, Asha MJ, Oswari S, Almeida JP, Gentili F. Creative and Innovative Methods and Techniques for the Challenges in the Management of Adult Craniopharyngioma. *World Neurosurg* 2020;142:601-10. doi: 10.1016/j.wneu.2020.05.173
48. Müller HL. Diagnostics, treatment, and follow-up in craniopharyngioma. *Front Endocrinol (Lausanne)* 2011;2:70. doi: 10.3389/fendo.2011.00070
49. Ezzat S, Kamal M, El-Khateeb N, El-Beltagy M, Taha H, Refaat A, et al. Pediatric brain tumors in a low/middle income country: does it differ from that in developed world? *J Neurooncol* 2016;126:371-6. doi: 10.1007/s11060-015-1979-7
50. Mallucci C, Pizer B, Blair J, Didi M, Doss A, Upadrashta S, et al. Management of craniopharyngioma: the Liverpool experience following the introduction of the CCLG guidelines. Introducing a new risk assessment grading system. *Childs Nerv Syst* 2012;28:1181-92. doi: 10.1007/s00381-012-1787-8.
51. Clusmann H, Höllig A. Craniopharyngioma: The Benefits of a Conservative Approach. *Dtsch Arztebl Int* 2019;116:319-20. doi: 10.3238/arztebl.2019.0319
52. Kaltsas GA, Kolomodi D, Randeve H, Grossman A. Nonneuroendocrine Neoplasms of the Pituitary Region. *J Clin Endocrinol Metab* 2019;104:3108-23. doi: 10.1210/jc.2018-01871
53. Murphy ES, Chao ST, Angelov L, Vogelbaum MA, Barnett G, Jung E, et al. Radiosurgery for Pediatric Brain Tumors. *Pediatr Blood Cancer* 2016;63:398-405. doi: 10.1002/pbc.25831
54. Raco A, Raimondi AJ, D'Alonzo A, Esposito V, Valentino V. Radiosurgery in the management of pediatric brain tumors. *Childs Nerv Syst* 2000;16:287-95. doi: 10.1007/s003810050516
55. Fouda MA, Day EL, Staffa SJ, Scott RM, Marcus KJ, Baird LC. Postoperative MR imaging surveillance of pediatric craniopharyngioma: new institutional guidelines. *Childs Nerv Syst* 2021;37:853-61. doi: 10.1007/s00381-020-04901-2
56. Kaltsas GA, Kolomodi D, Randeve H, Grossman A. Nonneuroendocrine Neoplasms of the Pituitary Region. *J Clin Endocrinol Metab* 2019;104:3108-23. doi: 10.1210/jc.2018-01871
57. Asha MJ, Oswari S, Takami H, Velasquez C, Almeida JP, Gentili F. Craniopharyngiomas: Challenges and Controversies. *World Neurosurg* 2020;142:593-600. doi: 10.1016/j.wneu.2020.05.172
58. Adeleye AO, Fasanla JA, Young PH. Skull base surgery in a large, resource-poor, developing country with few neurosurgeons: prospects, challenges, and needs. *World Neurosurg* 2012;78:35-43. doi: 10.1016/j.wneu.2011.07.015
59. Fezeu F, Ramesh A, Melmer PD, Moosa S, Larson PS, Henderson F Jr. Challenges and Solutions for Functional Neurosurgery in Developing Countries. *Cureus* 2018;10:e3314. doi: 10.7759/cureus.3314
60. Servadei F, Rossini Z, Nicolosi F, Morselli C, Park KB. The Role of Neurosurgery in Countries with Limited Facilities: Facts and Challenges. *World Neurosurg* 2018;112:315-21. doi: 10.1016/j.wneu.2018.01.047.

#### DISCLAIMER

Articles published in JPMA and Supplements of JPMA do not represent the views of the editor or editorial Board. Authors are solely responsible for the opinions expressed and the accuracy of the data.

The contribution of each author towards the published research included in this supplement is the responsibility of the authors and their institutions.

It is expected to be in accordance and compliance with the ICMJE Guidelines.

Any questions/queries raised by readers should be directed to the corresponding author.

## Consensus guidelines for the management of pineal region tumours for low- and middle-income countries

Saqib Kamran Bakhshi<sup>1</sup>, Naureen Mushtaq<sup>2</sup>, Rabeet Tariq<sup>3</sup>, Moez Tariq<sup>4</sup>, Asim Hafiz<sup>5</sup>, Ahmed Gilani<sup>6</sup>, Hafiza Fatima Aziz<sup>7</sup>, Muhammad Shahzad Shamim<sup>8</sup>, Altaf Ali Laghari<sup>9</sup>, Kaynat Siddiqui<sup>10</sup>

**Pakistan Brain Tumour Consortium:** (Authors list at the end of the supplement), Syed Ather Enam<sup>11</sup>.

### Abstract

Pineal region tumours are rare and mainly arise at a younger age. They can be categorized into various types: germ cell tumours (GCT), pineal parenchymal tumours (PPT), meningiomas, gliomas, pineoblastoma, pineal parenchymal tumours of intermediate differentiation, papillary tumours of the pineal region, and SMARCB1-mutant desmoplastic myxoid tumour. Within GCT, germinomas are the most prevalent, comprising the majority of tumours in this region, while non-germinomatous GCTs are also present. In rare instances, metastases from other sites may manifest. These tumours often lead to obstructive hydrocephalus and commonly exhibit symptoms related to mass effect, including headache, nausea, vomiting, and impaired gait stability. Different subtypes of pineal region tumours exhibit distinct radiological characteristics, thus imaging remains the primary diagnostic tool. Histologic diagnosis necessitates biopsy, unless in cases of germ cell tumours, particularly germinomas, which can be identified through elevated levels of tumour markers like alpha-fetoprotein (AFP) and human chorionic gonadotropin (HCG) in both cerebrospinal fluid (CSF) and serum. While benign tumours might be effectively treated with radical resection alone, malignant tumours demand additional chemotherapy and radiotherapy following surgical removal.

**Keywords:** Pinealoma, alpha-fetoproteins, meningioma, germinoma, chorionic, gonadotropin, hydrocephalus, headache, vomiting, glioma, biopsy, nausea, gait, tumours.

**DOI:** <https://doi.org/10.47391/JPMA.S3.GNO-16>

<sup>1,7-11</sup>Department of Neurosurgery, The Aga Khan University, <sup>2</sup>Department of Paediatric Oncology, The Aga Khan University, <sup>3</sup>Jumma Research Laboratories, The Aga Khan University, <sup>4</sup>Dow Medical College, <sup>5</sup>Department of Radiation Oncology, The Aga Khan University Hospital, Karachi, Pakistan. <sup>6</sup>Department of Pathology, University of Colorado, Children's Hospital Colorado, USA

**Correspondence:** Naureen Mushtaq **Email:** [naureen.mushtaq@aku.edu](mailto:naureen.mushtaq@aku.edu)

### Introduction

The pineal region harbours various tissues, making it susceptible to a diverse group of tumours. Pineal neoplasms are rare, representing 3%-11% of childhood neurological malignancies, and less than 1% of adult brain tumours.<sup>1</sup> The tumours of the pineal parenchyma include pineocytoma, pineoblastoma, pineal parenchymal tumour of intermediate differentiation (PPTID), and papillary tumour of the pineal region (PTPR).<sup>2</sup> The WHO CNS5 recently incorporated the SMARCB1-mutant desmoplastic myxoid tumour of the pineal region.<sup>2</sup> Germ cell tumours (GCT) are the most frequent primary tumours of the region, with germinomas comprising 73%-86% of all tumours.<sup>1</sup> Other less common forms of GCT include benign lesions such as dermoid tumours, epidermoid tumours, and teratomas; and malignant tumours such as choriocarcinomas, embryonal carcinomas, and endodermal sinus tumours.<sup>3,4</sup> These can be classified into non-germinomatous GCT. Other lesions may include cysts<sup>5,6</sup>, meningiomas, ependymomas, astrocytomas, and metastases.

### Methodology

The literature search of the high-quality data on pineal region tumours was done in March 2023 on different databases including PubMed, Google Scholar, Scopus, and Embase. The most relevant and high-quality studies were analysed to develop the evidence-based recommendations. An expert panel was convened consisting of specialists and leading experts within the field of neuro-oncology to identify the gaps in the diagnosis and management of pineal region tumours within Pakistan. This group was tasked with identifying best-practice recommendations and their application within Pakistan as an LMIC. Recommendations were collated, reviewed, and debated regarding utility and evidence-based practices, in a process that has been previously detailed.<sup>7</sup>

### Initial evaluation

Pineal tumours may present with mass-effect symptoms such as headache, nausea, vomiting, and gait instability

which are often due to obstructive hydrocephalus causing a raised intracranial pressure.<sup>3,8</sup> As the pineal gland is close to the hypothalamus, compressive hypothalamic syndromes like diabetes insipidus can occur.<sup>3</sup> Hypopituitarism, extra-pyramidal signs, and hemi-syndromes can also be observed.<sup>9</sup> Up to 76% of patients present with Parinaud's syndrome due to mid-brain compression.

Intracranial choriocarcinoma, primarily in the pineal gland can present with precocious puberty. Apart from this, choriocarcinomas do not show distinct symptoms, other than those mentioned above.<sup>3</sup> Large pinealocytomas may induce Parinaud syndrome; which presents as an upward gaze palsy, convergence retraction nystagmus, and pupillary light-near dissociation.<sup>3,8</sup>

## Neuroradiology

Neuroimaging serves as the primary method for diagnosing pineal tumours as this distinguishes not only the benign growths from malignant ones but also differentiates the tumours arising from adjacent areas.<sup>10</sup>

Konovalov and Pitskhelauri (2003) divided the tumours of the pineal region into five groups based on neuroimaging i.e., MRI and CT analysis; focusing on the size, expansion, and the tumours' interaction with neighbouring

**Table-1:** Classification of Pineal region tumours based on size.

Tumour Group	Tumour extension	Tumour size
Small	Quadrigeminal cistern	< 2.5 cm
	Posterior third ventricle	< 2.5 cm
Medium	Posterior third ventricle and quadrigeminal cistern	< 4 cm
	The pineal region with expansion into lateral ventricles	> 4 cm
Giant	Whole third ventricle, fourth ventricle, and lateral ventricles	> 6 cm

structures<sup>11</sup> as described in Table 1.

Different classes of pineal region tumours give distinct radiological appearances. Table 2 describes the relevant CT, MRI, and MR spectroscopy (MRS) findings in all the primary pineal tumours.<sup>9,12,13</sup>

## Tumour markers

Alpha-fetoprotein (AFP), human chorionic gonadotropin ( $\beta$ -hCG), placental alkaline phosphatase (PLAP), human placental lactogen (HPL), and lactate dehydrogenase (LDH) are considered tumour markers for GCTs, and are useful in for the diagnosis and the measuring the

response to treatment. An increase in AFP (either serum or CSF) greater than 10 ng/ml and  $\beta$ hCG greater than 50 mIU/ml is considered marker-positive.<sup>14</sup> Germinomas are associated with elevated  $\beta$ -hCG, LDH, and PALP; however, elevated  $\beta$ -hCG levels in germinomas are not consistent and are associated with a poor prognosis. Elevations in CSF and serum AFP alone are found in pure endodermal sinus tumours, whereas increase of both hCG and AFP are found in embryonal carcinoma, and an increase in hCG alone is found in choriocarcinoma.<sup>15,16</sup> Table 3 summarizes the known serum markers of pineal GCTs.

Currently, no tumour markers are confirmatory for pineal parenchymal tumours; Melatonin, synaptophysin (Syn), and chromogranin are potential markers and are being investigated.<sup>15,16</sup> Other CSF and serum markers being investigated include human placental lactogen, octamer-binding transcription factor 4, cytokeratin, carcinoembryonic antigen, and c-kit (CD117).<sup>16</sup> Germ cell biomarkers may be more sensitive for diagnosis when compared to histopathology<sup>17</sup> thus the need for a biopsy may be excluded in several cases.

## Management

Treatment depends on histologic and molecular diagnosis. Benign tumours are cured by radical resection, whereas malignant tumours require adjuvant chemo- and radiotherapy.<sup>11,14</sup> Germinomas are an exception as they may be treated only with radiotherapy, which may or may not be combined with chemotherapy.<sup>14,18,19</sup>

## Surgical intervention

The pineal gland is extra-axial and resides deep in the brain. Pineal region tumours may need surgical intervention for biopsy, or excision of lesion and CSF diversion (HCF). However, it is worth noting that bifocal tumours (pineal and suprasellar) with classical radiological features are pathognomonic for germinomas and may not require biopsy.

If CSF or serum markers are not positive for any malignant germ cell tumour, a biopsy is necessary for accurate histopathologic diagnosis to choose appropriate treatment modalities.<sup>20</sup> An open technique may allow maximal removal of the tumour, however, stereotactic biopsy is more feasible and less invasive, thus is the standard for biopsy of pineal region tumours.<sup>20,21</sup> Based on neuro-navigation, the surgical approach can vary, including orthogonal lateral, oblique anterolateral, or posterolateral approaches. However, the optimal trajectory is a low frontal approach that avoids the internal cerebral veins. For biopsies, the Nashold side-cutting biopsy needle is considered ideal. The procedure may be conducted under local or general anaesthesia

**Table-2:** Radiological Findings.

Tumor classification	CT findings	MRI findings	MRS findings
<b>Germ cell tumours</b>			
Germinoma	Hyper-attenuated circumscribed mass.	Solid mass, iso-high intensity to gray matter in T1WI and T2WI and homogenous post-contrast enhancement. A “butterfly” shaped structure on post-contrast axial cuts.	Consistent Tau is observation with increased Lip/Cr and Cho/NAA ratios.
Teratoma	Heterogenous mass with foci of low-fat attenuation. Strong heterogenous post-contrast enhancement.	High intensity foci on T1WI and T2WI depending on fat and protein components.	Increased Lip/Cr ratio on long-echo time and relatively lower total choline and creatine levels on single voxel short-echo.
Other GCTs	High density mass of around 5 cm without calcification	Irregularly shaped, iso, low, or high intensity on T1WI, hyperintense on T2WI, homogeneous enhancement, and cystic components with perifocal oedema. Intra-tumoural haemorrhage is present in choriocarcinoma.	Insufficient data
<b>Pineal parenchymal tumours</b>			
Pineocytoma	Iso-hypoattenuating well-circumscribed lesions with mass effect.	Homogenous iso-signal T1WI and high signal T2WI lesions with robust contrast enhancement.	Insufficient data
Pineoblastoma	Large lobulated, slightly hypodense poorly demarcated homogenous mass.	Hypo-isointense heterogenous enhancing T1WI.	Increased Cho/NAA without lipid’s peak and non-specific taurine peak.
PPTID	(Imaging features are same as in pineocytomas)	Total choline peak low as compared to creatine peak.	
PTPR	Cystic mass and mildly hyperdense soft tissue components without contrast enhancement.	Circumscribed lesions with T1WI, T2WI, and post-contrast enhancement. Protein inclusions can give hyperintense T1 signal.	Insufficient data
Desmoplastic myxoid tumour of Pineal region: SMARCB1 mutant	High-density lesion in the pineal area.	Slightly intense lesion on T1WI and mixed signal on T2WI.	Insufficient data

T1 weighted images: T1WI, T2 weighted images: T2WI, PPTID: pineal parenchymal tumour of intermediate differentiation, PTPR: pineoblastoma, and papillary tumour of the pineal region.

wherever indicated.<sup>20</sup> The endoscopic approach is commonly used for biopsies and may be performed via the transventricular route. It is considered a minimally invasive procedure; thus, it reduces the exposure of the functional region and minimizes the potential for complications, however, there is a significant risk of intraventricular bleeding and CSF dissemination of the tumour.<sup>22</sup>

Open microsurgical resection may be used for the resection of benign lesions, cytoreduction prior to adjuvant therapy, or in some cases a second-look surgery may be needed to remove residual tumours.<sup>23</sup> Although establishing a diagnosis with a biopsy followed by

radiation and chemotherapy is a common practice, surgeons prefer direct radical open excision before establishing the diagnosis, for better outcomes regarding long-term recurrence-free survival in benign tumours<sup>18,24–26</sup>, as well as provision of adequate samples for biopsy. The approach may be the infratentorial supracerebellar, occipital transtentorial, transcallosal interhemispheric, or transcortical transventricular.<sup>27</sup> The transient postoperative complications include impaired extraocular movements, pupillary dysfunction, and ataxia. Haemorrhage may occur in an incompletely resected tumour. Conservative management may be done for small haemorrhages; however, a large haemorrhage requires immediate evacuation. Venous infarct can also

**Table 3:** Serum markers.

Tumor	Serum marker
Germinoma	PLAP, CD117 (membrane labeling), Cytokeratin. Pure germinoma: OCT3/4 Germinoma with STGC: HPL, $\beta$ -hCG.
Teratoma	AFP (if immature enteric type), Cytokeratin (low).
Choriocarcinoma	HPL, $\beta$ -hCG, Cytokeratin.
Yolk Sac tumour	AFP, Cytokeratin
Embryonal cell carcinoma	PLAP, OCT $\frac{3}{4}$ , CD30, Cytokeratin.

PLAP: Placental alkaline phosphatase, HCG: human chorionic gonadotropin, STGC: Syncytiotrophoblastic giant cells, AFP: Alpha fetoprotein, HPL: human placental lactogen hormone, OCT: Octamer-binding transcription factor .

occur and extend into the midbrain. Mortality is uncommon and may be due to brainstem manipulation, which can lead to cognitive impairments.<sup>27</sup> An endoscopic modification was introduced which allowed gross total resection (GTR) with decreased postoperative complications.<sup>28</sup>

Obstructive HCF is a common presentation of pineal tumours owing to the compression of the aqueduct of Sylvius. Endoscopic third ventriculostomy (accompanied by taking the biopsy samples) is the preferred strategy for management.<sup>29-31</sup> Ventriculoperitoneal shunting may be an alternative, however, it may harbour an approximate

5% risk of infection, metastasis, and malfunction.<sup>23,32</sup> Therefore, in the presence of HCP, endoscopic biopsy via the trans ventricular root should be considered, whereas, stereotactic biopsy may be used in its absence.

### Pathological assessment

The normal pineal parenchyma is loosely lobular in appearance with 95% of cells being pinealocytes, the remaining are astrocytes, both being separated by fibrovascular stroma.<sup>33,34</sup>

Normal pinealocytes show robust positivity to Synaptophysin, Neurofilament (NF), and Rhodopsin (as pinealocytes are modified neurons related to rods and

**Table-4:** Morphologic patterns of the Pineal GCTs.

Germ cell tumours	Gross Morphology	Histo-pathology	Immuno-histo-chemistry
<b>Germinoma</b>	Well-circumscribed gray-pink tissue with complete obliteration of residual pineal gland	Two-cell populations present: Tumour cells (round to polygonal, central nucleus, clear cytoplasm, mitotic figures are seen but necrosis is rare, cells in sheets and large lobules with intervening stroma) and T-cells (forming granulomas mimicking intra-cranial sarcoidosis, STGCs may be present).	PLAP, $\beta$ -hCG in tumour with STGC.
<b>Teratoma</b>	Large cystic mass	Mature teratoma presents with skin and adnexa from ectoderm, cartilage, muscle, bone, fat from mesoderm, and respiratory and enteric epithelium from endoderm. Mitotic activity is minimal or absent. Immature teratoma exhibits foetal tissue that has not fully differentiated.	AFP (immature teratoma)
<b>Choriocarcinoma</b>	Typically ovoid and well-defined mass with irregular infiltrating margins. and possible haemorrhage	Syncytiotrophoblast cells (vacuolated cytoplasm, multiple, pleomorphic, hyperchromatic nuclei with mitotic figures) and cytotrophoblastic cells (clear cytoplasm, round nucleus) are present.	$\beta$ -hCG, HPL, cytokeratin 7.
<b>Yolk Cell tumor</b>	Large irregular mass	Small cells, prominent nucleus and mitotic figures. Schiller-Duval bodies present.	AFP
<b>Embryonal Carcinoma</b>	Gland-like aggregates with papillary projections	Polygonal or round cells with clear or eosinophilic cytoplasm. Mitotic figures and necrotic foci are present.	OCT4, PLAP, and CD30 positive and c-kit negative.

PLAP: Placental alkaline phosphatase, HCG: human chorionic gonadotropin, STGC: Syncytiotrophoblastic giant cells, AFP: Alpha feto-protein, HPL: human placental lactogen hormone, OCT4: Octamer-binding transcription factor 4.



**Table-5:** Morphology and histopathology.

Tumour classification	WHO Grade	Histopathology	Immunohistochemistry
Pineocytoma	1	Two microscopic variants: Typical (displays well-differentiated cells with uniform cellularity, a diffuse or loosely lobular growth pattern, round or oval nuclei featuring 'salt and pepper' chromatin, the presence of pineocytomatous rosettes, and a scarcity of mitotic activity and necrosis) & Pleomorphic (hyperchromic bizarre nuclei and ganglionic elements, along with features of typical variant).	Syn, NF, Chromogranin A
Pineoblastoma	4	There is a presence of sheets composed of poorly differentiated cells. These cells have scanty cytoplasm, hyperchromatic nuclei with an elevated nuclear-to-cytoplasmic ratio. Additionally, there is the possibility of observing Homer-Wright rosettes (indicative of neuroblastic differentiation) or Flexner-Wintersteiner rosettes (indicative of retinoblastic differentiation). Mitotic bodies, foci of necrosis, and invasion of the adjacent tissue seen.	Syn, NF, Chromogranin A
PPTID	2 or 3	Features intermediate between pineocytoma and pineoblastoma. Sheet-like architecture, monomorphic round cells	Strong Syn staining, variable NF, negative for NeuN
PTPR	2 or 3	Similar to epithelial tissue, displaying varying degrees of papillary features alongside solid regions. Perivascular rosettes are also present. The cells have round to oval nuclei and eosinophilic cytoplasm. Mitotic activity and necrosis are observed within the tumour.	Cytokeratin (particularly CK-18), vimentin, S100
Desmoplastic myxoid tumour of Pineal region: SMARCB1 mutant	To be decided	Cord-like structures comprising small to medium-sized oval to spindle and epithelioid cells. These cells are surrounded by a matrix rich in collagen. Occasional calcifications might be observed, but instances of mitotic activity and necrosis are rare.	Loss of nuclear SMARCB1 (INI1) expression. Epithelial membrane antigen and CD34

PPTID: pineal parenchymal tumor of intermediate differentiation, PTPR: pineoblastoma, and papillary tumor of the pineal region, NF: Neurofilament, Syn: synaptophysin; SMARCB1: SWI/SNF Related, Matrix Associated, Actin Dependent Regulator of Chromatin, Subfamily B.

cones).<sup>8, 34</sup> The interstitial cells show the expression of Glial Fibrillary Acidic Protein (GFAP) and S100 protein (S-100P).<sup>34</sup>

Important differentials include differentiating pineocytoma from normal pineal or pineal cyst (normal pineal gland does not show pineocytomatous rosettes); differentiating pineoblastoma from medulloblastoma (pineal vs posterior fossa location) and atypical teratoid rhabdoid tumour (SMARCB1/ INI-1 loss should be ruled out in pineoblastoma). As mentioned above, germ cell neoplasms are frequent and should be considered by pathologists.

Younger populations are mainly affected by aggressive variants, whereas older individuals usually have benign tumours.<sup>34</sup> The morphologic patterns of the main pineal GCTs are described in Table 4.<sup>33-36</sup>

The morphologic, histopathologic, and immunologic details of pineal parenchymal tumours along with their respective WHO grades are shown in Table 5.<sup>2</sup>

## Molecular markers and cytogenetics

Several genes are involved in molecular and cytogenetic techniques to diagnose pineal gland tumours. mRNAs for the enzymes required to synthesize melatonin including Tryptophan hydroxylase (TPH), serotonin N-acetyl transferase (SNAT), and Hydroxyindole O-methyl transferase (HOMT) are found in cells of pineocytomas.<sup>33,37</sup>

In pineoblastomas, seven specific genes expressed which have a role in cellular growth (HOXD13, Hist1H4E, POU4F2, PITX2, Hist1H3D), junctional modification (DSG1) and resisting cellular senescence (TERT).<sup>38</sup> Methylation analysis categorizes pineoblastomas into four distinct molecular subgroups: Pineoblastoma with disrupted miRNA processing (Type 1) in paediatric patients, Pineoblastoma with altered miRNA processing (Type 2) in older children (both marked by mutations in DROSHA, DICER1, or DGCR8), Pineoblastoma driven by MYC/FOXR2 activation in infants, and Pineoblastoma with RB1 alterations in infants.

Analysis of four specific genes using real-time reverse transcriptase PCR (PRAME, CD24, HOXD13, and POU4F2) in PPTID effectively distinguishes between low-grade and

high-grade PPTIDs. The expression of these genes is notably higher in the latter category.<sup>38</sup> In the context of diagnosing PPTID, the presence of KBTBD4 in-frame insertions is a significant diagnostic criterion.<sup>2</sup>

A hypothesis suggests the origin of papillary tumours of the pineal region can be traced back to the sub-commissural organ.<sup>33</sup> This theory is supported by a cDNA microarray study, which revealed elevated expression levels of specific genes (ZFH4, RFX3, TTR, and CGRP) known to be active in the sub-commissural organ.<sup>38</sup>

In all instances of desmoplastic myxoid tumours in the pineal region, there is a consistent loss of nuclear SMARCB1/INI1 protein expression.<sup>35</sup> Notably, the DNA methylation profiles observed in these reported cases show clustering patterns that are closely associated with AT/RTMYC and poorly differentiated chordomas.<sup>39</sup>

It is worth noting that all molecular and cytogenetic studies may not be feasible for LMICs as they do not significantly change the management plan.

### Radiotherapy

Radiotherapy is an integral component in the management of pineal region tumours. The response to radiotherapy depends on the histological diagnosis e.g., germ cell origin or pineal parenchymal tumours.<sup>40</sup>

For pineal region germ cell tumours RT is essential for curative treatment. Because GCT is not as common in adults, therefore, the adjuvant therapy strategies are primarily informed by data derived from studies conducted on paediatric and adolescent populations. These approaches encompass various treatment volumes, including craniospinal irradiation (CSI), whole-brain irradiation (WBI), whole ventricular irradiation (WVI), or involved-field radiotherapy (IF-RT) targeting the tumour site. The determination of treatment volumes and dosage prescriptions is personalized based on factors such as histological subtypes, disease extent, the integration of chemotherapy, and the patient's response. An important goal of contemporary treatment technologies including volumetric-modulated arc therapy (VMAT) and intensity-modulated radiotherapy (IMRT) is to decrease the risk of long-term complications by reducing radiation doses to non-target brain areas.

Surgery is the main modality to deal most pineal parenchymal tumours. For low grade tumour like pineocytoma and grade 2 pineal parenchymal tumours radiotherapy is indicated if disease is unresectable or complete resection is not possible.<sup>41</sup> However, high grade tumour requires adjuvant radiation due to high risk of recurrence as studies have shown improved local control

leading to better survival.<sup>42, 43</sup> Radiation treatment volumes depends upon MRI spine and CSF cytology finding and range from craniospinal irradiation in case of CSF dissemination to focal radiotherapy for localized disease. Owing to their low incidence in adult, the appropriate treatment for pineoblastomas is not established and usually derived from paediatric treatment protocol has shown a positive outcome.<sup>44</sup> The response of radiotherapy in pineoblastomas is better in older patients and those who undergo surgery.<sup>45</sup> Radiation doses of 24-36 Gy to the entire neural axis followed by tumour bed /tumour boost to 54-60 Gy in 1.8-2 Gy fraction have been described.<sup>46</sup>

Recently stereotactic radiation therapy/radiosurgery is increasingly being used due to high precision, desired dosimetry profile, and low morbidity for small residual or recurrent tumours.<sup>47-49</sup>

### Chemotherapy

Chemotherapy has been shown to be highly effective in treating germinomas. In a phase-II trial evaluating neoadjuvant chemotherapy, the combination of carboplatin and radiotherapy exhibited significant activity in effectively treating newly diagnosed CNS germinomas, mainly in the pineal gland.<sup>50</sup> A chemotherapy regimen consisting of cisplatin and etoposide; or ifosfamide, cisplatin, and etoposide showed an excellent response.<sup>51</sup> The response to the same regime was also used to differentiate germinomas from germinoma-like and other tumours.<sup>52</sup> Shrinkage of non-germinomatous GCTs in children by chemotherapy with bleomycin, etoposide, and cisplatin before and after subtotal resection was reported.<sup>53</sup> with no deficits or recurrences.<sup>54</sup> Kellie SJ et al. assessed a regime including cyclophosphamide, etoposide, cisplatin, and bleomycin followed by two courses of etoposide, carboplatin, and bleomycin if patients had complete remission.<sup>55</sup>

Cisplatin, vinblastine, and/or bleomycin have been effective for pineal parenchymal tumours when combined with radiation.<sup>56</sup> Neoadjuvant chemotherapy with etoposide, cisplatin, and vincristine was effective in children with pineoblastoma aged 3-7 years, however, mild myelosuppression and mild to moderate high-frequency sensorineural hearing loss were the adverse effects.<sup>57</sup> Cyclophosphamide, vincristine, cisplatin, and etoposide were assessed and failed for the management of infant pineoblastomas.<sup>58</sup> There has been a case of PTPR being treated successfully with Temozolomide.<sup>59</sup>

### Follow-up

Follow-ups include clinical evaluation, imaging, and biomarker monitoring for the assessment of treatment

**Table-6:** Summary of Recommendations for Pineal Tumours

<b>Radiology</b>	<ul style="list-style-type: none"> <li>• Complete MRI brain and spine study is needed.</li> <li>• 'Minimum required' MRI brain protocol:               <ul style="list-style-type: none"> <li>o Imaging on at least 0.5T.</li> <li>o Sequences: Axial T2 and coronal or axial FLAIR sequence; pre-contrast T1 and contrast enhanced T1.</li> </ul> </li> <li>• Tumour location, tumour margins, enhancement pattern, tumour size, and presence of haemorrhage/mineralisation.</li> <li>• Postoperative MRI is recommended within 72 hours of surgery. If delayed, then MRI should be performed after 6 weeks.               <ul style="list-style-type: none"> <li>o To identify the extent of resection.</li> <li>o To have a baseline to compare successive imaging.</li> <li>o Not required after biopsy.</li> </ul> </li> </ul>
<b>Neurosurgery</b>	<ul style="list-style-type: none"> <li>• Surgical goals: Resection of tumor and opening of the CSF pathway, if needed.</li> <li>• Gross total resection should be attempted where possible. However, in case of tumour adherence to the surrounding critical structures, maximum safe resection should be performed.</li> <li>• Abstain from VP shunt as a temporising procedure unless there is a significant risk of deterioration due to hydrocephalus. Consider referring the patient to a facility where surgical resection can be done along with CSF diversion (EVD/VPS/ETV) if needed.</li> </ul>
<b>Neuropathology</b>	<ul style="list-style-type: none"> <li>• Haematoxylin and Eosin (H&amp;E) slides for histological typing.</li> <li>• Immunohistochemical stains GFAP, Olig-2, EMA, p-53, SALL4, OCT3/4, pan-cytokeratin, Ki-67 (proliferative marker) and INI-1 for possible definite characterisation of these tumours.</li> </ul>
<b>Paediatric Oncology</b>	<ul style="list-style-type: none"> <li>• Germinomas: Carboplatin and etoposide.</li> <li>• Non-germinomatous: Cisplatin, etoposide, and Ifosphamide.</li> <li>• Pineoblastoma: Cisplatin, vincristine, and cyclophosphamide (treated as high-risk medulloblastoma).</li> </ul>
<b>Radiation oncology</b>	<ul style="list-style-type: none"> <li>• Advanced radiation treatment technologies such as volumetric-modulated arc therapy [VMAT], and intensity-modulated radiotherapy [IMRT] are recommended to reduce the risk of long-term toxicity.</li> <li>• Pineoblastoma: Treated on lines of High-Risk Medulloblastoma with Craniospinal Irradiation (36 Gy) and a tumour bed boost to 54 Gy.</li> <li>• Germinoma &amp; NGGCT: Radiation treatment volume and dose depend upon the extent of residual disease at the time of radiation therapy and metastasis.</li> </ul>

Continued on next column...

Continued from previous column...

<b>Follow-up</b>	<ul style="list-style-type: none"> <li>• First follow-up at post-op day 10 for wound assessment, stitch removal, discussion related to histopathology, and NOTB recommendations.</li> <li>• Clinical follow-up with MRI every 3 months with pediatric oncologist.</li> </ul>
------------------	--

MRI: Magnetic resonance imaging, FLAIR: Fluid-attenuated inversion recovery, CSF: Cerebrospinal fluid, EVD: External ventricular drain, VPS: Ventriculoperitoneal shunts, ETV: Endoscopic third ventriculostomy, H&E: Hematoxylin and eosin, GFAP: Glial fibrillary acidic protein, EMA: dotlike epithelial membrane antigen, SALL4: Sal-like protein 4, OCT3/4: Octamer-binding transcription factor 3/4, VMAT: Volumetric modulated arc therapy, IMRT: Intensity-modulated radiation therapy, Gy: Gray, NGGCT: non-germinoma germ cell tumours, NOTB: Neuro-oncology tumour board.

outcomes. Radiologic assessment is necessary to assess the EOR and/or the response to chemo- or radiotherapy. A decrease in biomarkers corresponds to a positive response to the given treatment, whereas static or increasing levels of biomarkers show treatment failure.

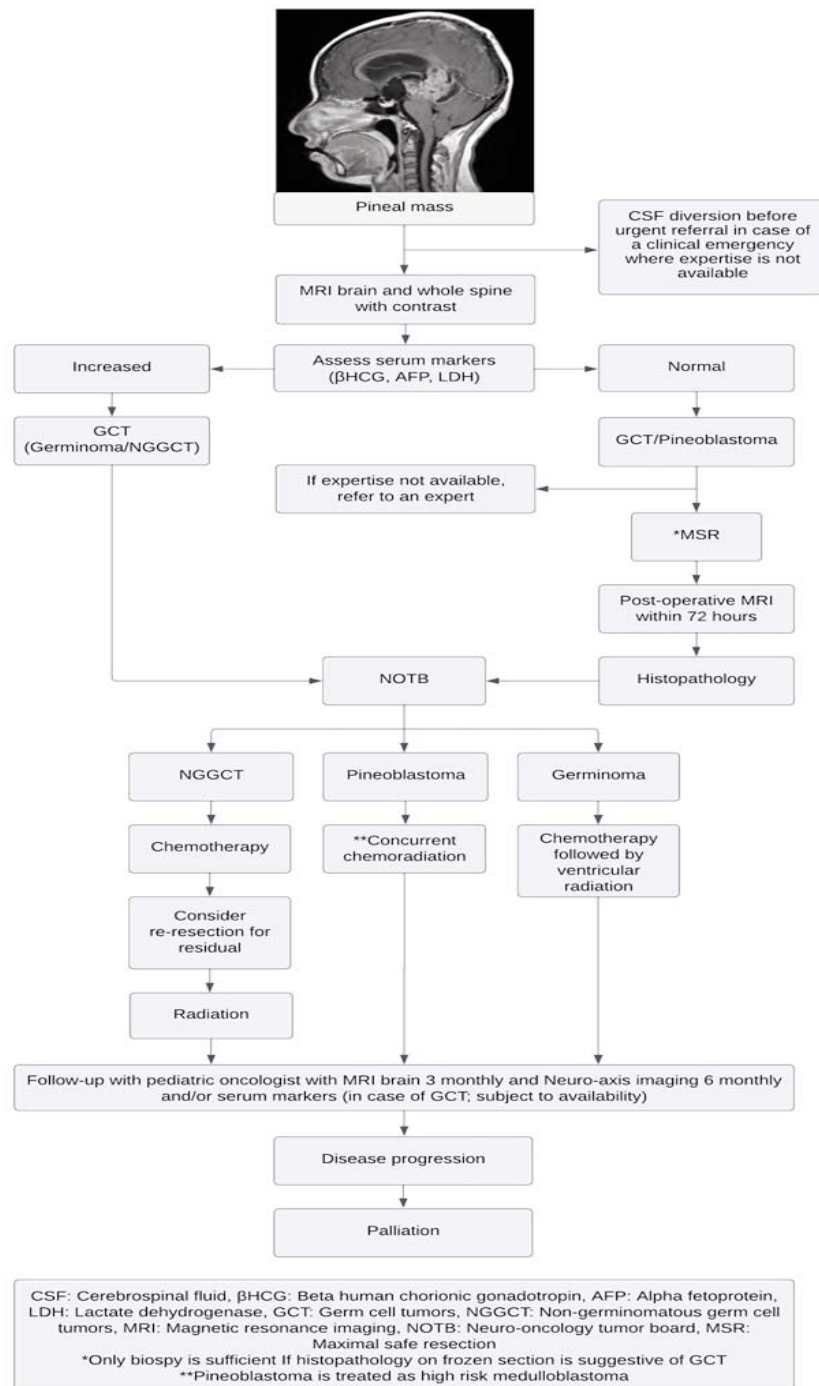
### Prognosis

Germinomas, although considered malignant, have the best prognosis and five-year survival of 90% due to a positive response to radiotherapy.<sup>60,61</sup> Choriocarcinomas have the lowest survival rate in all GCTs due to frequent haemorrhages and progressive extra-neural and CSF metastasis, with elevated levels of hCG as a marker of poor prognosis.<sup>62</sup> Teratomas have a good prognosis with complete resection.<sup>16</sup> Highly malignant GCTs include choriocarcinoma, embryonal carcinoma, and yolk sac tumour which have a three-year survival of only 27.3%; mixed-tumours with a three-year survival of 9.3%.<sup>36</sup> Overall good prognostic group of germinomas includes germinomas and mature teratoma; the intermediate prognostic group includes immature teratoma; and the poor prognostic group consists of teratoma with malignant transformations, yolk sac tumours, choriocarcinoma, and mixed GCTs consisting of a component with malignant transformation.<sup>36</sup>

Pineocytomas<sup>63</sup> and pineoblastomas<sup>64</sup> are associated with extremely poor outcomes.<sup>65,66</sup> Smaller age and metastasis are the risk factors.<sup>66,67</sup> PTPRs have a 5-year survival rate of 73% and progression-free survival rate of 27% due to frequent local recurrences.<sup>68</sup>

### Conclusion

Designed for doctors practicing in areas with limited resources, these guidelines offer a practical guide informed by valuable expertise (refer to Table 6 and Figure 1). Applying these guidelines could substantially enhance specific outcomes and promote a greater focus



**Figure-1:** Management of Pineal region tumours algorithm.

on collaborative care in low- and middle-income countries (LMICs) like Pakistan.

**Disclaimer:** None.

**Conflict of Interest:** None.

**Funding Disclosure:** None.

## References

- Villano JL, Propp JM, Porter KR, Stewart AK, Valyi-Nagy T, Li X, et al. Malignant pineal germ-cell tumors: an analysis of cases from three tumor registries. *Neuro Oncol* 2008;10:121-30. doi: 10.1215/15228517-2007-054.
- Louis DN, Perry A, Wesseling P, Brat DJ, Cree IA, Figarella-Branger D, et al. The 2021 WHO Classification of Tumors of the Central

- Nervous System: a summary. *Neuro Oncol* 2021;23:1231-5. doi: 10.1093/neuonc/noab106.
3. Favero G, Bonomini F, Rezzani R. Pineal Gland Tumors: A Review. *Cancers (Basel)* 2021;13:1547. doi: 10.3390/cancers13071547.
  4. Sugiyama K, Uozumi T, Kiya K, Mukada K, Arita K, Kurisu K, et al. Intracranial germ-cell tumor with synchronous lesions in the pineal and suprasellar regions: report of six cases and review of the literature. *Surg Neurol* 1992;38:114-20. doi: 10.1016/0090-3019(92)90088-5.
  5. Al-Holou WN, Terman SW, Kilburg C, Garton HJ, Muraszko KM, Chandler WF, et al. Prevalence and natural history of pineal cysts in adults. *J Neurosurg* 2011;115:1106-14. doi: 10.3171/2011.6.JNS11506.
  6. Choque-Velasquez J, Colasanti R, Baluszek S, Resendiz-Nieves J, Muhammad S, Ludtka C, et al. Systematic review of pineal cysts surgery in pediatric patients. *Childs Nerv Syst* 2020;36:2927-38. Doi:10.1007/s00381-020-04792-3.
  7. Bajwa MH, Shah MM, Mustansir F, Gauhar F, Baig E, Zafar SN, et al. A Guideline On Guidelines – Neuro-Oncology Guideline Standards For Low And Middle-Income Countries. *J Pak Med Assoc* 2024;74(Suppl 3):s87-92. Doi: 10.47391/JPMA.S3.GNO-10.
  8. Patel S, Rahmani B, Gandhi J, Seyam O, Joshi G, Reid I, et al. Revisiting the pineal gland: a review of calcification, masses, precocious puberty, and melatonin functions. *Int J Neurosci* 2020;130:464-75. doi: 10.1080/00207454.2019.1692838.
  9. Shah SH, Soomro IN, Hussainy AS, Hassan SH. Clinicomorphological pattern of intracranial tumors in children. *J Pak Med Assoc* 1999;49:63-5.
  10. Deiana G, Mottolese C, Hermier M, Louis-Tisserand G, Berthezene Y. Imagery of pineal tumors. *Neurochir* 2015;61:113-22. Doi:10.1016/j.neuchi.2014.10.111.
  11. Kononov AN, Pitskhelauri DI. Principles of treatment of the pineal region tumors. *Surg Neurol* 2003;59:250-68. doi: 10.1016/s0090-3019(03)00080-6.
  12. Sadashiva N, Deora H, Arumalla K, Rao S, Saini J, Shukla D, et al. Pineal Parenchymal Tumor of Intermediate Differentiation (PPTID) and Papillary Tumor of Pineal Region (PTPR): A Review. *Neurol India* 2021;69:1153-64. doi: 10.4103/0028-3886.329550.
  13. Tien RD, Barkovich AJ, Edwards MS. MR imaging of pineal tumors. *AJR Am J Roentgenol* 1990;155:143-51. doi: 10.2214/ajr.155.1.2162137.
  14. Zaazoue MA, Goumnerova LC. Pineal region tumors: a simplified management scheme. *Childs Nerv Syst* 2016;32:2041-5. doi: 10.1007/s00381-016-3157-4.
  15. Allen JC, Bruce J, Kun LE, Langford L. Pineal Region Tumors. [Online] 1970 [Cited 22 October 25]. Available from URL: [https://soc-neuro-onc.org/UploadedFiles/Levin/Levin\\_ch07\\_p193-207.pdf](https://soc-neuro-onc.org/UploadedFiles/Levin/Levin_ch07_p193-207.pdf)
  16. Carr C, O'Neill BE, Hochhalter CB, Strong MJ, Ware ML. Biomarkers of Pineal Region Tumors: A Review. *Ochsner J* 2019;19:26-31. doi: 10.31486/toj.18.0110.
  17. Nagasawa DT, Lagman C, Sun M, Yew A, Chung LK, Lee SJ, et al. Pineal germ cell tumors: Two cases with review of histopathologies and biomarkers. *J Clin Neurosci* 2017;38:23-31. doi: 10.1016/j.jocn.2016.12.024.
  18. Bruce JN, Stein BM. Surgical management of pineal region tumors. *Acta Neurochir (Wien)* 1995;134:130-5. doi: 10.1007/BF01417679.
  19. Joorna R, Kendall BE. Diagnosis and management of pineal tumors. *J Neurosurg* 1983;58:654-65. doi: 10.3171/jns.1983.58.5.0654.
  20. Zacharia BE, Bruce JN. Stereotactic biopsy considerations for pineal tumors. *Neurosurg Clin N Am* 2011;22:359-66. doi: 10.1016/j.nec.2011.05.008.
  21. Regis J, Bouillot P, Rouby-Volot F, Figarella-Branger D, Dufour H, Peragut JC. Pineal region tumors and the role of stereotactic biopsy: review of the mortality, morbidity, and diagnostic rates in 370 cases. *Neurosurgery* 1996;39:907-12. doi: 10.1097/00006123-199611000-00003.
  22. Chaussemy D, Cebulla H, Coca A, Chibarro S, Proust F, Kehrl P. Interest and limits of endoscopic approaches for pineal region tumours. *Neurochirurgie* 2015;61:160-3. doi: 10.1016/j.neuchi.2015.03.001.
  23. Bruce JN, Ogden AT. Surgical strategies for treating patients with pineal region tumors. *J Neurooncol* 2004;69:221-36. doi: 10.1023/b:neon.0000041885.09226.2d.
  24. Vaquero J, Ramiro J, Martínez R, Coca S, Bravo G. Clinicopathological experience with pineocytomas: report of five surgically treated cases. *Neurosurgery* 1990;27:612-8.
  25. Barnett DW, Olson JJ, Thomas WG, Hunter SB. Low-grade astrocytomas arising from the pineal gland. *Surg Neurol* 1995;43:70-5. doi: 10.1016/0090-3019(95)80043-g.
  26. Lapras C, Patet JD, Mottolese C, Lapras C Jr. Direct surgery for pineal tumors: occipital-transtentorial approach. *Prog Exp Tumor Res* 1987;30:268-80. doi: 10.1159/000413684.
  27. Sonabend AM, Bowden S, Bruce JN. Microsurgical resection of pineal region tumors. *J Neurooncol* 2016;130:351-66. doi: 10.1007/s11060-016-2138-5.
  28. Shahinian H, Ra Y. Fully endoscopic resection of pineal region tumors. *J Neurol Surg B Skull Base* 2013;74:114-7. doi: 10.1055/s-0033-1338165.
  29. Rieger A, Rainov NG, Brucke M, Marx T, Holz C. Endoscopic third ventriculostomy is the treatment of choice for obstructive hydrocephalus due to pediatric pineal tumors. *Minim Invasive Neurosurg* 2000;43:83-6. doi: 10.1055/s-2000-8324.
  30. Samadian M, Maloumeh EN, Shiravand S, Ebrahimzadeh K, Sharifi G, Mousavinejad A, et al. Pineal region tumors: Long-term results of endoscopic third ventriculostomy and concurrent tumor biopsy with a single entry approach in a series of 64 cases. *Clin Neurol Neurosurg* 2019;184:105418. Doi:10.1016/j.clineuro.2019.105418.
  31. Morgenstern PF, Osbun N, Schwartz TH, Greenfield JP, Tsiouris AJ, Souweidane MM. Pineal region tumors: an optimal approach for simultaneous endoscopic third ventriculostomy and biopsy. *Neurosurg Focus* 2011;30:E3. doi: 10.3171/2011.2.FOCUS10301.
  32. Gururangan S, Heideman RL, Kovnar EH, Sanford RA, Kun LE. Peritoneal metastases in two patients with pineoblastoma and ventriculo-peritoneal shunts. *Med Pediatr Oncol* 1994;22:417-20. doi: 10.1002/mpo.2950220613.
  33. Fèvre-Montange M, Vasiljevic A, Champier J, Jouvet A. Histopathology of tumors of the pineal region. *Future Oncol* 2010;6:791-809. doi: 10.2217/fon.10.28.
  34. Smith AB, Rushing EJ, Smirniotopoulos JG. From the archives of the AFIP: lesions of the pineal region: radiologic-pathologic correlation. *Radiographics* 2010;30:2001-20. doi: 10.1148/rg.307105131.
  35. Lombardi G, Poliani PL, Manara R, Berhouma M, Minniti G, Tabouret E, et al. Diagnosis and Treatment of Pineal Region Tumors in Adults: A EURACAN Overview. *Cancers (Basel)* 2022;14:3646. doi: 10.3390/cancers14153646.
  36. Matsutani M. Clinical management of primary central nervous system germ cell tumors. *Semin Oncol* 2004;31:676-83. doi: 10.1053/j.seminoncol.2004.07.010.
  37. Fèvre-Montange M, Champier J, Szathmari A, Brisson C, Reboul A, Mottolese C, et al. Histological features and expression of enzymes implicated in melatonin synthesis in pineal parenchymal tumours and in cultured tumoural pineal cells. *Neuropathol Appl Neurobiol* 2008;34:296-305. doi: 10.1111/j.1365-2990.2007.00891.x.
  38. Fèvre-Montange M, Champier J, Szathmari A, Wierinckx A,

- Mottolese C, Guyotat J, et al. Microarray analysis reveals differential gene expression patterns in tumors of the pineal region. *J Neuropathol Exp Neurol* 2006;65:675-84. doi: 10.1097/01.jnen.0000225907.90052.e3.
39. Thomas C, Wefers A, Bens S, Nemes K, Agaimy A, Oyen F, et al. Desmoplastic myxoid tumor, SMARCB1-mutant: clinical, histopathological and molecular characterization of a pineal region tumor encountered in adolescents and adults. *Acta Neuropathol* 2020;139:277-86. doi: 10.1007/s00401-019-02094-w.
40. Fuller BG, Kapp DS, Cox R. Radiation therapy of pineal region tumors: 25 new cases and a review of 208 previously reported cases. *Int J Radiat Oncol Biol Phys* 1994;28:229-45. doi: 10.1016/0360-3016(94)90162-7.
41. Ait Erraïsse M, Abboud FZ, Youssefoufi MA, Alami B, Bouhafa T, Hassouni K. Exclusive Radiotherapy for Pineal Parenchymal Tumor of Intermediate Differentiation: Case Report. *SAJ Case Rep* 2018;5:e404. doi: 10.18875/2375-7043.5.404
42. Clark AJ, Ivan ME, Sughrue ME, Yang I, Aranda D, Han SJ, et al. Tumor control after surgery and radiotherapy for pineocytoma. *J Neurosurg* 2010;113:319-24. doi: 10.3171/2009.12.JNS091683.
43. Kumar N, Srinivasa GY, Madan R, Salunke P. Role of radiotherapy in residual pineal parenchymal tumors. *Clin Neurol Neurosurg* 2018;166:91-8. doi: 10.1016/j.clineuro.2018.01.027.
44. Jin MC, Prolo LM, Wu A, Azad TD, Shi S, Rodrigues AJ, et al. Patterns of Care and Age-Specific Impact of Extent of Resection and Adjuvant Radiotherapy in Pediatric Pineoblastoma. *Neurosurgery* 2020;86:E426-35. doi: 10.1093/neuros/nyaa023.
45. Lancia A, Becherini C, Detti B, Bottero M, Baki M, Cancelli A, et al. Radiotherapy for papillary tumor of the pineal region: A systematic review of the literature. *Clin Neurol Neurosurg* 2020;190:105646. doi: 10.1016/j.clineuro.2019.105646.
46. Iorio-Morin C, Kano H, Huang M, Lunsford LD, Simonová G, Liscak R et al. Histology-Stratified Tumor Control and Patient Survival After Stereotactic Radiosurgery for Pineal Region Tumors: A Report From the International Gamma Knife Research Foundation. *World Neurosurg* 2017;107:974-82. doi: 10.1016/j.wneu.2017.07.097.
47. Li W, Zhang B, Kang W, Dong B, Ma X, Song J, et al. Gamma knife radiosurgery (GKRS) for pineal region tumors: a study of 147 cases. *World J Surg Oncol* 2015;13:304. doi: 10.1186/s12957-015-0720-5.
48. Motiei-Langroudi R, Sadeghian H, Soleimani MM, Seddighi AS, Shahzadi S. Treatment Results for Pineal Region Tumors: Role of Stereotactic Biopsy Plus Adjuvant Therapy vs. Open Resection. *Turk Neurosurg* 2016;26:336-40. doi: 10.5137/1019-5149.JTN.11759-14.1.
49. Allen JC, DaRosso RC, Donahue B, Nirenberg A. A phase II trial of preirradiation carboplatin in newly diagnosed germinoma of the central nervous system. *Cancer* 1994;74:940-4. doi: 10.1002/1097-0142(19940801)74:3<940::aid-cnrc2820740323>3.0.co;2-u.
50. Sawamura Y, Shirato H, Ikeda J, Tada M, Ishii N, Kato T, et al. Induction chemotherapy followed by reduced-volume radiation therapy for newly diagnosed central nervous system germinoma. *J Neurosurg* 1998;88:66-72. doi: 10.3171/jns.1998.88.1.0066.
51. Saito R, Kumabe T, Kanamori M, Sonoda Y, Watanabe M, Mugikura S, et al. Early response to chemotherapy as an indicator for the management of germinoma-like tumors of the pineal and/or suprasellar regions. *J Clin Neurosci* 2014;21:124-30. doi: 10.1016/j.jocn.2013.05.014.
52. Herrmann HD, Westphal M, Winkler K, Laas RW, Schulte FJ. Treatment of nongerminomatous germ-cell tumors of the pineal region. *Neurosurgery* 1994;34:524-9. doi: 10.1227/00006123-199403000-00021.
53. Knappe UJ, Bentele K, Horstmann M, Herrmann HD. Treatment and long-term outcome of pineal nongerminomatous germ cell tumors. *Pediatr Neurosurg* 1998;28:241-5. doi: 10.1159/000028658.
54. Kellie SJ, Boyce H, Dunkel IJ, Diez B, Rosenblum M, Brualdi L, et al. Primary chemotherapy for intracranial nongerminomatous germ cell tumors: results of the second international CNS germ cell study group protocol. *J Clin Oncol* 2004;22:846-53. doi: 10.1200/JCO.2004.07.006.
55. Kurisaka M, Arisawa M, Mori T, Sakamoto T, Seike M, Mori K, et al. Combination chemotherapy (cisplatin, vinblastin) and low-dose irradiation in the treatment of pineal parenchymal cell tumors. *Childs Nerv Syst* 1998;14:564-9. doi: 10.1007/s003810050273.
56. Ghim TT, Davis P, Seo JJ, Crocker I, O'Brien M, Krawiecki N. Response to neoadjuvant chemotherapy in children with pineoblastoma. *Cancer* 1993;72:1795-800. doi: 10.1002/1097-0142(19930901)72:5<1795::aid-cnrc2820720546>3.0.co;2-n.
57. Duffner PK, Cohen ME, Sanford RA, Horowitz ME, Krischer JP, Burger PC, et al. Lack of efficacy of postoperative chemotherapy and delayed radiation in very young children with pineoblastoma. *Pediatric Oncology Group. Med Pediatr Oncol* 1995;25:38-44. doi: 10.1002/mpo.2950250109.
58. Lorenzetti M, Motta F, Campanella R, Bauer D, Assi A, Arienta C, et al. Adjuvant temozolomide chemotherapy for treatment of papillary tumor of the pineal region. *World Neurosurg* 2011;76:160-3. doi: 10.1016/j.wneu.2010.10.039.
59. Kumar N, Srinivasa GY, Madan R, Salunke P. Role of radiotherapy in residual pineal parenchymal tumors. *Clin Neurol Neurosurg* 2018;166:91-8. doi: 10.1016/j.clineuro.2018.01.027.
60. Ai P, Peng X, Jiang Y, Zhang H, Wang S, Wei Y. Complete regression of adult pineoblastoma following radiotherapy: A case report and review of the literature. *Oncol Lett* 2015;10:2329-32. doi: 10.3892/ol.2015.3574.
61. Tamrazi B, Nelson M, Blüml S. Pineal Region Masses in Pediatric Patients. *Neuroimaging Clin N Am* 2017;27:85-97.
62. Shinoda J, Sakai N, Yano H, Hattori T, Ohkuma A, Sakaguchi H. Prognostic factors and therapeutic problems of primary intracranial choriocarcinoma/germ-cell tumors with high levels of HCG. *J Neurooncol* 2004;66:225-40. doi: 10.1023/b:neon.0000013499.74404.81.
63. Dislafani A, Hudgins RJ, Edwards MS, Wara W, Wilson CB, Levin VA. Pineocytomas. *Cancer* 1989;63:302-4. doi: 10.1002/1097-0142(19890115)63:2<302::aid-cnrc2820630216>3.0.co;2-d.
64. Deng X, Yang Z, Zhang X, Lin D, Xu X, Lu X, et al. Prognosis of Pediatric Patients with Pineoblastoma: A SEER Analysis 1990-2013. *World Neurosurg* 2018;118:e871-9. doi: 10.1016/j.wneu.2018.07.079.
65. Clark AJ, Sughrue ME, Ivan ME, Aranda D, Rutkowski MJ, Kane AJ, et al. Factors influencing overall survival rates for patients with pineocytoma. *J Neurooncol* 2010;100:255-60.
66. Tate M, Sughrue ME, Rutkowski MJ, Kane AJ, Aranda D, McClinton L, et al. The long-term postsurgical prognosis of patients with pineoblastoma. *Cancer* 2012;118:173-9. doi: 10.1002/cncr.26300.
67. Villà S, Miller RC, Krengli M, Abusaris H, Baumert BG, Servagi-Vernat S, et al. Primary pineal tumors: outcome and prognostic factors--a study from the Rare Cancer Network (RCN). *Clin Transl Oncol* 2012;14:827-34. doi: 10.1007/s12094-012-0869-0.
68. Fèvre-Montange M, Hasselblatt M, Figarella-Branger D, Chauveinc L, Champier J, Saint-Pierre G, et al. Prognosis and histopathologic features in papillary tumors of the pineal region: a retrospective multicenter study of 31 cases. *J Neuropathol Exp Neurol* 2006;65:1004-11. doi: 10.1097/01.jnen.0000240462.80263.13.

**DISCLAIMER**

Articles published in JPMA and Supplements of JPMA do not represent the views of the editor or editorial Board. Authors are solely responsible for the opinions expressed and the accuracy of the data.

The contribution of each author towards the published research included in this supplement is the responsibility of the authors and their institutions. It is expected to be in accordance and compliance with the ICMJE Guidelines.

Any questions/queries raised by readers should be directed to the corresponding author.

## Consensus guidelines for the management of intracranial ependymoma for low- and middle-income countries

Ahsan Ali Khan<sup>1</sup>, Muhammad Usman Khalid<sup>2</sup>, Mohammad Hamza Bajwa<sup>3</sup>, Izza Tahir<sup>4</sup>, Shahier Paracha<sup>5</sup>, Muhammad Shakir<sup>6</sup>, Bilal Mazhar Qureshi<sup>7</sup>, Naureen Mushtaq<sup>8</sup>, Ahmed Gilani<sup>9</sup>

**Pakistan Brain Tumour Consortium:** (Authors list at the end of the supplement), Syed Ather Enam.

### Abstract

This paper presents comprehensive consensus guidelines for the management of intracranial ependymoma, neoplasms arising from ependymal cells in the central nervous system's ventricular system, in low- and middle-income countries (LMICs). Acknowledging the distinct epidemiological patterns of ependymomas, notably their higher incidence in paediatric patients, and variable survival rates, these guidelines emphasize tailored management approaches for different age groups. An expert panel, comprising specialists in neuro-oncology, convened to address gaps in diagnosis and management within LMICs, considering the varying clinical presentation based on tumour size and location. Emphasizing surgical intervention as the cornerstone of treatment, the guidelines also address challenges such as intraoperative bleeding and tumour location impacting complete resection. The role of molecular subgrouping in stratifying treatment and predicting prognosis is highlighted, alongside a careful consideration of radiotherapy timing, dose, and volume based on risk factors. Chemotherapy's role, especially in paediatric cases, is explored. The paper synthesizes current research and expert opinions, including the need for standardisation, genetic testing, and exploration of less invasive treatment modalities, to address the unique healthcare infrastructure challenges in LMICs. The guidelines also emphasize multidisciplinary teams, aiming to bridge the care gap between high-income countries and LMICs, and improve survival rates and quality of life for patients with intracranial ependymoma. This article serves as a valuable resource for clinicians, researchers, and policymakers in Pakistan and beyond, facilitating the development of evidence-based strategies

in diverse healthcare settings.

**Keywords:** Nervous system, genetic, ependymoma, prognosis, ependymoma, surgery, radiotherapy.

**DOI:** <https://doi.org/10.47391/JPMA.S3.GNO-17>

### Introduction

Ependymomas originate from the ependymal cells lining the ventricular system in the central nervous system.<sup>1</sup> Ependymomas are more common in children, comprising 5.2% of all CNS tumours compared to 1.9% of adult CNS tumours.<sup>2</sup> Ependymomas in children are commonly found intracranially especially in the posterior fossa, whereas in adults they mainly affect the spinal cord.<sup>1,3</sup> Overall survival (OS) rate is significantly higher in adults compared to children with a 79% 10-year OS in adults, but it decreases in older adults 75 years and older with a 28% 10-year OS.<sup>1,2</sup>

### Methodology

The literature search of the high-quality data on intracranial ependymomas was done in March 2023 on different databases including PubMed, Google Scholar, Scopus, and Embase. The most relevant and high-quality studies were analyzed to develop the evidence-based recommendations. An expert panel was convened consisting of specialists and leading experts within the field of neuro-oncology to identify the gaps in diagnosis and management of intracranial ependymomas within Pakistan. This group was tasked with identifying best-practice recommendations and their application within the context of Pakistan as one of the low- and middle-income countries (LMICs). Recommendations were collated and reviewed for utility and evidence-based practices in LMICs.<sup>4</sup>

### Clinical presentation and evaluation

Clinical presentation of intracranial ependymomas varies depending on tumour location and size with global neurological symptoms in cases of obstructive hydrocephalus or focal symptoms due to local mass effect.<sup>5</sup> These mainly present with symptoms of headache,

.....  
<sup>1-3,6,10</sup>Department of Neurosurgery, The Aga Khan University, Karachi, Pakistan. <sup>4,5</sup>The Aga Khan Medical College and University, Karachi, Pakistan. <sup>7</sup>Department of Radiation Oncology, The Aga Khan University, Karachi, Pakistan. <sup>8</sup>Department of Paediatric Oncology, The Aga Khan University, Karachi, Pakistan. <sup>9</sup>Department of Pathology, University of Colorado, Childrens Hospital Colorado, USA.

**Correspondence:** Syed Ather Enam **Email:** [ather.enam@aku.edu](mailto:ather.enam@aku.edu)

gait disturbance along with hemiparesis and vomiting in children.<sup>4</sup> Ependymomas present with local growth, but their metastasis rate is low. Factors influencing survival in ependymoma patients include age, gain of chromosomal arm 1q, tumour location, gender, telomerase reactivation and molecular subgrouping.<sup>5,6</sup>

### Diagnostic workup

Diagnostic workup of ependymomas should be done through MRI with contrast enhancement of the entire neuroaxis and cerebrospinal fluid (CSF) cytology to identify disseminated disease.<sup>1,5</sup>

The modality of choice for ependymoma diagnosis is MRI, which appears as a well-circumscribed mass lesion. To differentiate between other neoplasms and ependymomas in the posterior fossa, diffusion-weighted imaging is advised.<sup>1</sup> Ependymomas exhibit elevated choline and reduced N-acetylaspartate in MR spectroscopy and elevated cerebral blood volume in perfusion MRI.<sup>1</sup> An enhancing mass lesion with T1 hypointensity and T2 hyperintensity is indicative of ependymomas.<sup>5</sup> T2 hypointensity is also seen on cyst walls if there is cyst formation. CT scans can be useful in diagnosing subependymomas due to their calcification.<sup>1</sup>

### Surgical management

Surgical management of ependymomas is the first-choice treatment of ependymomas. Gross total resection is linked with higher progression-free survival as well as overall survival compared to sub-total resection.<sup>7</sup> Surgical management with radiotherapy is advised for PF-EPN-A ependymomas for patients above 12 months of age. Follow-up surgery may be required for incomplete resection in the first procedure.<sup>5</sup> However, intraoperative bleeding and invasion into the basal ganglia and thalamus hinders total resection in surgical management.<sup>8</sup> Deep rooted and microinvasive ependymomas may require neuro-navigation and maximal safe resection should be the goal if the tumour cannot be resected completely.<sup>8</sup>

Surgical technique applied is dependent on tumour size and location. For the majority of ependymomas, gross total resection is preferred due to its greater prognostic value. Subtotal resection may be employed for ependymomas involving cranial nerves and the brainstem.<sup>1</sup> However, patients with subtotal resection have a higher chance of developing progressive disease.<sup>9</sup> Second-look surgery can be used for subtotally resected ependymomas.<sup>8</sup>

### Histopathology

The 2022 WHO classification of CNS tumours classifies

EPN according to a combination of histopathological and molecular features and anatomical site.<sup>10, 11</sup> The current classification lists EPN by anatomic site into supratentorial, posterior fossa and spinal. Supratentorial EPN can be further divided into those with ZFTA fusion, those with YAP1 fusion, or a “not otherwise specified [NOS]” group without any of these features. Similarly posterior fossa (PF) EPN is divided into group A (PFA) or PFB. Spinal tumours can feature MYCN amplification. Immunohistochemical surrogate of ZFTA fusion is L1CAM and that for PFA is loss of immunoreactivity for H3K27me<sup>3</sup>. If molecular subclassification is unfeasible or unsuccessful, the EPN should be classified by the anatomic site and is designated “not otherwise specified [NOS]”. Histologically distinct types include myxopapillary ependymoma and subependymoma.<sup>11</sup>

Classic histologic features of EPN include true ependymal rosettes which are characterized by arrangement of tumour cells around a central canal with a lumen and an intervening ‘nuclear-free zone’. More often, however, the tumour shows pseudo-rosettes which are marked by arrangement of tumour cells around blood vessels.<sup>6, 10-12</sup>

Myxopapillary ependymomas (MPE), are characterised by papillary structures encompassing areas that show myxoid degeneration and hyalinized blood vessels.<sup>10, 13</sup> MPE previously designated as WHO grade 1 are now considered grade 2 based on the presence of frequent recurrences in this entity. These most commonly arise in the spinal cord, predominantly in the region of the conus medullaris, the cauda equina or filum terminale.<sup>14</sup> Myxopapillary ependymoma WHO grade I is histologically characterised by cuboidal or elongated tumour cells forming fibrillary processes toward fibrovascular cores typically showing perivascular mucoid degeneration. Mitotic activity is low.<sup>1, 13</sup>

Other histologically distinct EPN variants such as papillary, clear cell or tanycytic ependymoma are no longer listed as discrete entities in CNS5. Mitotic activity is low while non-palisading necrosis may be present in a fraction of cases.<sup>1</sup>

Subependymoma is given a WHO grade 1, subependymoma, grade 2, while other EPN can be grade 2 or 3 based on histologic criteria. EPN can be assigned WHO grade 3 based upon the presence of anaplastic features including hypercellularity, increased proliferative activity including increased mitotic rate and/ or higher MIB1, and the presence of necrosis or microvascular proliferation. The current WHO classification does not specify a discrete criteria for grading of EPN and the utility of grading in EPN has been challenged.<sup>10, 11</sup>



## Molecular pathology

Recent advances show that genetic markers play a major role in stratifying treatment and predicting survival in EPN.<sup>7</sup> Hence, where possible, molecular subgrouping should be performed as part of the routine histologic workup for EPN.

Two molecular subtypes of ependymomas that have been shown to have poor prognosis are PF-EPN-A ependymomas and ependymomas with fusions involving ZFTA/ RELA.<sup>1, 15</sup> The PF-EPN-A subtype mostly occurs in the cerebellum of young children, and although it does not exhibit recurrent genomic alterations, it is readily identified by a characteristic hypermethylation signature and/or an absence of H3K27me3 immunostaining in tumour cell nuclei.<sup>16</sup> Chromosome 1q gain has been associated with worse prognosis in PFA EPN. ZFTA fusion positive EPN are characterised by the presence of gene fusions involving the ZFTA gene (formerly known as C11orf95) causing increased NF-κB signalling. The most common fusion partner of ZFTA is RELA gene, hence this tumour was formerly called RELA fusion positive EPN. ZFTA EPN can be identified by the presence of positive staining for L1CAM. PF-EPN-B, ST-EPN-YAP1, molecular SE (PF-SE/ST-SE/SP-SE), and spinal molecular groups (SP-MPE, SP-EPN) are mainly associated with favourable prognosis.<sup>5, 6, 11, 15, 17, 18</sup>

Over 75% of ependymomas was reported to demonstrate ErbB 2 (Her2) and ErbB 4 co-expression; in addition, ligand-dependent activation of the ErbB receptor was found to trigger cellular proliferation in cultured ependymoma cells; therefore, the ErbB protein family would also be investigated as a therapeutic target in intramedullary ependymoma.<sup>19</sup>

DNA methylation profiling has emerged as a robust source for the reliable distinction of different brain tumour entities or the identification of clinically relevant subgroups within a specific tumour entity.<sup>20, 21</sup>

## Radiotherapy

Surgery with maximum safe resection remains the mainstay of curative treatment for all children with Ependymoma. As a standard of care, postoperative radiotherapy is the standard of care in patients with high-

grade ependymomas, patients who are unable to tolerate gross total resection, after incomplete resection and recurrence of tumour. Radiotherapy should follow surgical removal in patients with intracranial ependymoma WHO grades 2 or 3, regardless of the fact whether gross total resection is done or not.<sup>1, 9, 15, 22, 23</sup> This has been shown to locally control the tumour as well as increase the overall survival. The irradiation field depends upon neuroaxis findings, if CSF or MRI shows neural axis dissemination of disease then craniospinal irradiation is recommended otherwise localised radiation to operative /disease site is indicated.<sup>7</sup>

The timing, dose and volume of radiotherapy may affect overall survival, as well.<sup>24</sup> Current studies have suggested radiotherapy doses of 54-59.4 Gy in 30-33 fractions @ 1.8Gy/fraction, five days a week in 6-6.5 weeks period as per risk of local tumour recurrence. Radiotherapy can be given to patients starting from 1 year of age. Patient who requires craniospinal irradiation usually receive radiation dose of 36 Gy /20 fractions @ 1.8 Gy/fraction followed by focal boost to postoperative bed/residual/gross disease up to 59.4Gy.<sup>2, 7, 9, 14, 22</sup> Recommended units of post operative radiotherapy with respect to age are shown below Shown in Table 1

RT is given to children with grade 2 in anaplastic spinal ependymomas, even if gross total resection has been achieved. 5 Adjuvant RT is also administered in myxopapillary ependymomas, without which the rate of recurrence has been shown to be high.

Role of radiosurgery is evolving and can provide benefit in term of local control in highly selected patients, however, it is not recommended as upfront treatment after surgery.<sup>5, 17</sup> Similarly, proton therapy is also emerging as new radiation treatment modality because of its reduced toxicity outcome due to its characteristic beam profile.<sup>25, 26</sup> All efforts should be made to deliver a useful dose to the target area and spare the normal CNS structures of these children. Peer review of radiation treatment planning and delivery remains crucial for maintaining quality of treatment.<sup>27</sup>

It is appropriate to conclude that Multidisciplinary approach involving all stakeholders including paediatric neurosurgeon, medical and radiation oncologist is essential component of comprehensive cancer care and peer review is crucial step in this critical process hence translating into maximum clinical benefit with minimal toxicity.<sup>28</sup>

## Chemotherapy

Surgery and radiotherapy (RT) are the current therapeutic

**Table-1:** Units of post operative radiotherapy.

Age	Dose of Radiotherapy administered
12-18 months	54 Gy (1.8 Gy/fraction)
18 months or altered neurological status	54 Gy (1.8 Gy/fraction)
> 18 months	59.4Gy (1.8 Gy/fraction)

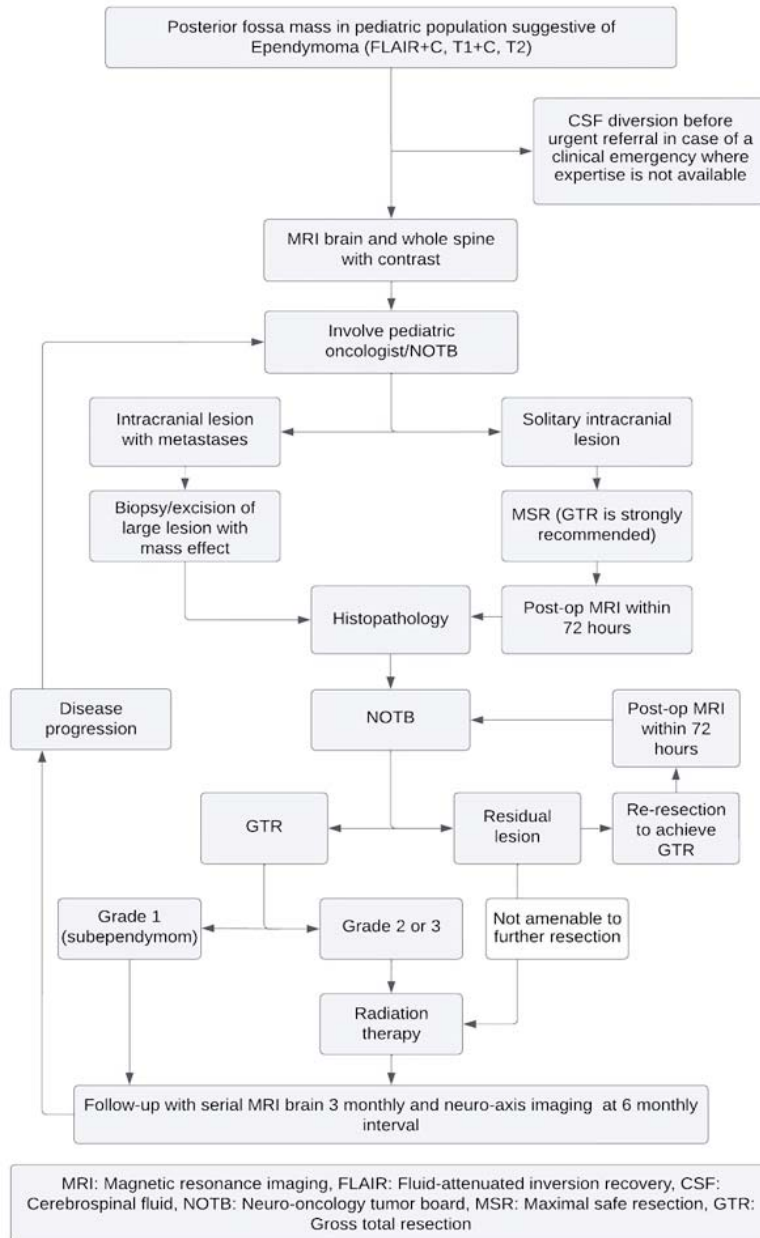
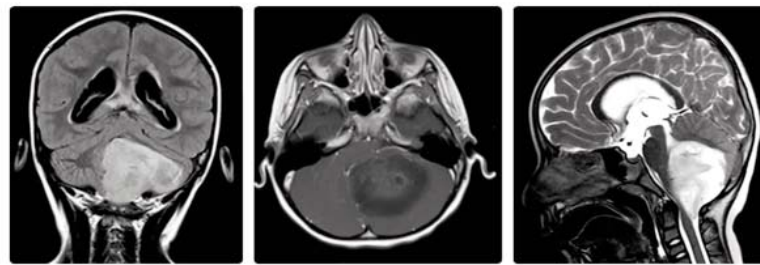


Figure-1: Management of intracranial ependymoma algorithm

mainstays for ependymomas, and the role of chemotherapy alone is not proven.<sup>5</sup> The role of chemotherapy in the management of ependymomas in young population is being investigated whereas its efficacy in adults is minimal. In paediatric population, preoperative chemotherapy can sometimes be administered in adjunct to reduce the volume and vascularity of tumour.<sup>8</sup> Chemotherapy when used, is in patients with subtotally removed tumours, in already irradiated patients with inoperable recurrences and in children <12 months with ependymomas, due to the possible side effects of the chemotherapy due to the immature brain which can result in neurocognitive deficits over time.<sup>1, 2</sup> Different regimens of chemotherapy include vincristine, cyclophosphamide, etoposide, platinum derivatives and methotrexate, but none of these have showed outcomes better than adjuvant radiotherapy.<sup>7, 9, 24, 29</sup>

**Post-operative management and follow-up**

Main therapeutic treatments are surgery and RT. Frequent neuroimaging along with clinical assessments is recommended.<sup>5</sup> For the first two years after treatment, MRI should be repeated after 3 months and from third to sixth year, it should be repeated every 6 months to monitor the progress and recurrence of tumour. This is also summarized in Table 2.

**Table-2:** Post-operative management and follow-up.

Year of tumour resection	Imaging (MRI)
First 2 years	Every 3 months
3rd-6th years	Every 6 months

Before resorting to radiotherapy, early second-look surgery can be proposed to achieve total removal in selected cases where an accessible tumour remnant is disclosed on postoperative MRI. A repeat MRI may be appropriate to confirm the diagnosis of tumour remnant before proposing second-look surgery.

The regular assessment of neurocognitive function, as well as monitoring quality of life, is also deemed necessary as part of the protocol. In cases where there is tumour recurrence after irradiation, histomolecular reassessment can be performed in order to rule out the formation of novel tumours, e.g., glioblastoma.<sup>5</sup> Recurrent STE is an indication of choice for reoperation.<sup>8</sup> Even when treated with additional radiation therapy, patients with subtotal resection remain at higher risk for disease progression.<sup>7, 8</sup> For spinal ependymomas, there can be tumour recurrence even after a decade, thus follow up

**Table-3:** Summary of Recommendations for Ependymoma.

<b>Radiology</b>	<ul style="list-style-type: none"> <li>• Complete MRI brain and spine study is needed.</li> <li>• ‘Minimum required’ MRI brain protocol:                             <ul style="list-style-type: none"> <li>o Imaging on at least 0.5T.</li> <li>o Sequences: Axial T2 and coronal or axial FLAIR sequence; pre-contrast T1 and contrast enhanced T1.</li> </ul> </li> <li>• Tumour location, tumour margins, enhancement pattern, tumour size, involvement of brainstem, and presence of hemorrhage/mineralisation.</li> <li>• Postoperative MRI is recommended in the first 48 hours after surgery. If delayed by 72 hours, then MRI should be delayed by 3 weeks but not more than 4 weeks.                             <ul style="list-style-type: none"> <li>o To identify the extent of resection.</li> <li>o To have a baseline to compare successive imaging.</li> <li>o Not required after biopsy.</li> </ul> </li> </ul>
<b>Neurosurgery</b>	<ul style="list-style-type: none"> <li>• Surgical goals: Resection of tumour and opening of the CSF pathway.</li> <li>• Gross total resection should be attempted where possible. However, in case of tumour adherence to the surrounding critical structures i.e. obex or floor of the fourth ventricle, maximum safe resection should be performed.</li> <li>• Abstain from VP shunt as a temporising procedure unless there is a significant risk of deterioration due to hydrocephalus. Consider referring the patient to a facility where surgical resection can be done along with CSF diversion if needed.</li> <li>• In case of delay in surgical intervention, CSF drainage (VPS or ETV) is recommended.</li> <li>• Redo surgery can be considered in case of recurrence/disease progression after risk stratification in NOTB.</li> </ul>
<b>Neuropathology</b>	<ul style="list-style-type: none"> <li>• Haematoxylin and Eosin (H&amp;E) for histological typing.</li> <li>• The role of histologic grading is limited in EPN but should be rendered according to the degree of cellularity, proliferative activity (mitoses and Ki-67/ MIB1 rate), the presence or absence of necrosis, and microvascular proliferation.</li> <li>• Immunostain L-1CAM to identify ZFTA fusion-positive supratentorial EPN and H3K27me to differentiate Posterior fossa A and B subtypes. Both stains are to be used as surrogates for molecular studies.</li> </ul>
<b>Medical Oncology</b>	<ul style="list-style-type: none"> <li>• Chemotherapy is not a mainstay of therapy and is not currently recommended.</li> </ul>

Continued on next page...

Continued from previous page...

**Radiation oncology** • Radiotherapy is recommended after STR, and in grade 2/3 tumours irrespective of extent of resection and after recurrence.

- Recommended dose is 59.4 Gy @ 1.8 Gy/ fraction per day five days a week over 6.5 weeks. For children <18 months, the total dose will be restricted to 54 Gy.

**Follow-up**

- First follow-up at post-op day 10 for wound assessment, stitch removal, discussion related to histopathology, and NOTB recommendations.
- Serial MRI brain at 3 months, and Neuro-axis MRI at 6 months for two years then every 6 months for 3 years.

MRI: Magnetic resonance imaging, FLAIR: Fluid-attenuated inversion recovery, CSF: Cerebrospinal fluid, VPS: Ventriculoperitoneal shunt, ETV: endoscopic third ventriculostomy, NOTB: Neuro-oncology tumour board, EPN: Ependymoma, MIB1: Mindbomb Homolog-1, ZFTA: Zinc Finger Translocation Associated, STR: Subtotal resection, Gy: Gray.

can be done life-long.<sup>4</sup> Multi-disciplinary tumour board discussion are vital in decision making.

### Miscellaneous/prognosis/quality of life

Overall, ependymomas have a generally decent outcome if resected completely 67 to 85% five-year survival rate versus the one with incomplete resection 30 to 50%. Progression free survival for five years is 43 to 64% and 24 to 53% for ten years.<sup>1</sup> With improvements in management of ependymomas, the survival rates have been increasing in the last decade.<sup>24</sup> Prognosis depends on multiple factors such as age, resection of tumour, and molecular subgrouping. Infants usually have a worse prognosis for ependymomas.<sup>2</sup> Extent of surgical resection is still the best predictor of prognosis with significantly better survival rate in gross total resection as compared to subtotal resection.<sup>17</sup>

### Gaps in knowledge

There is still a need for standardisation of ependymoma management along with the utility of new and emerging techniques in molecular genetics. New research involving genetic testing and prognosis of ependymoma treatment is vitally important in assessing new treatment modalities in the future. Less invasive and procedures requiring less radiation especially in the children population is of immense importance to improve quality of life in patients with ependymomas.

### Conclusion

Developed to support healthcare professionals working in resource-constrained settings, these recommendations provide a practical framework based on valuable

expertise (see Table 3 and Figure 1). Implementing these guidelines has the potential to significantly improve specific outcomes and promote increased emphasis on teamwork in healthcare within low- and middle-income countries (LMICs) such as Pakistan.

**Disclaimer:** None.

**Conflict of Interest:** None.

**Funding Disclosure:** None.

### References

1. Wu J, Armstrong TS, Gilbert MR. Biology and management of ependymomas. *Neuro Oncol* 2016;18:902-13. doi: 10.1093/neuonc/now016.
2. Rudà R, Reifenberger G, Frappaz D, Pfister SM, Laprie A, Santarius T, et al. EANO guidelines for the diagnosis and treatment of ependymal tumors. *Neuro Oncol* 2018;20:445-56. doi: 10.1093/neuonc/nox166.
3. Gerstner ER, Pajtler KW. Ependymoma. *Semin Neurol* 2018;38:104-11. doi: 10.1055/s-0038-1636503.
4. Bajwa MH, Shah MM, Mustansir F, Gauhar F, Baig E, Zafar SN, et al. A Guideline On Guidelines – Neuro-Oncology Guideline Standards For Low And Middle-Income Countries. *J Pak Med Assoc* 2024;74(Suppl 3):s87-92. Doi: 10.47391/JPMA.S3.GNO-10.
5. Leeper H, Felicella MM, Walbert T. Recent Advances in the Classification and Treatment of Ependymomas. *Curr Treat Options Oncol* 2017;18:55. doi: 10.1007/s11864-017-0496-7.
6. Hübner JM, Kool M, Pfister SM, Pajtler KW. Epidemiology, molecular classification and WHO grading of ependymoma. *J Neurosurg Sci* 2018;62:46-50. doi: 10.23736/S0390-5616.17.04152-2.
7. Merchant TE, Boop FA, Kun LE, Sanford RA. A retrospective study of surgery and reirradiation for recurrent ependymoma. *Int J Radiat Oncol Biol Phys* 2008;71:87-97. doi: 10.1016/j.ijrobp.2007.09.037.
8. Vinchon M, Soto-Ares G, Riffaud L, Ruchoux MM, Dhellemmes P. Supratentorial ependymoma in children. *Pediatr Neurosurg* 2001;34:77-8. doi: 10.1159/000055999.
9. Oh MC, Ivan ME, Sun MZ, Kaur G, Safaee M, Kim JM, et al. Adjuvant radiotherapy delays recurrence following subtotal resection of spinal cord ependymomas. *Neuro Oncol* 2013;15:208-15. doi: 10.1093/neuonc/nos286.
10. Bale TA, Rosenblum MK. The 2021 WHO Classification of Tumors of the Central Nervous System: An update on pediatric low-grade gliomas and glioneuronal tumors. *Brain Pathol* 2022;32:e13060. doi: 10.1111/bpa.13060.
11. Kresbach C, Neyazi S, Schüller U. Updates in the classification of ependymal neoplasms: The 2021 WHO Classification and beyond. *Brain Pathol* 2022;32:e13068. doi: 10.1111/bpa.13068.
12. Louis DN, Perry A, Wesseling P, Brat DJ, Cree IA, Figarella-Branger D, et al. The 2021 WHO Classification of Tumors of the Central Nervous System: a summary. *Neuro Oncol* 2021;23:1231-5. doi: 10.1093/neuonc/naob106.
13. Sonneland PR, Scheithauer BW, Onofrio BM. Myxopapillary ependymoma. A clinicopathologic and immunocytochemical study of 77 cases. *Cancer* 1985;56:883-93. doi: 10.1002/1097-0142(19850815)56:4<883::aid-cnrcr2820560431>3.0.co;2-6.
14. Feldman WB, Clark AJ, Safaee M, Ames CP, Parsa AT. Tumour control after surgery for spinal myxopapillary ependymomas: distinct outcomes in adults versus children: a systematic review. *J Neurosurg Spine* 2013;19:471-6. doi: 10.3171/2013.6.SPINE12927.
15. Kishwar Jafri SK, Bakhshi SK, Shamim MS. Management of paediatric intracranial ependymoma. *J Pak Med Assoc*

- 2021;71:1288-9.
16. Mu W, Dahmouh H. Classification and neuroimaging of ependymal tumors. *Front Pediatr* 2023;11:1181211. doi: 10.3389/fped.2023.1181211.
  17. Horbinski C, Ligon KL, Brastianos P, Huse JT, Venere M, Chang S, et al. The medical necessity of advanced molecular testing in the diagnosis and treatment of brain tumor patients. *Neuro Oncol* 2019;21:1498-50. doi: 10.1093/neuonc/noz119.
  18. Louis DN, Aldape K, Brat DJ, Capper D, Ellison DW, Hawkins C, et al. cIMPACT-NOW (the consortium to inform molecular and practical approaches to CNS tumor taxonomy): a new initiative in advancing nervous system tumor classification. *Brain Pathol* 2017;27:851-2. doi: 10.1111/bpa.12457.
  19. Varlet P, Bouffet E, Casanova M, Giangaspero F, Antonelli M, Hargrave D, et al. Comprehensive analysis of the ErbB receptor family in pediatric nervous system tumors and rhabdomyosarcoma. *Pediatr Blood Cancer* 2022;69:e29316. doi: 10.1002/pbc.29316.
  20. Witt H, Gramatzki D, Hentschel B, Pajtler KW, Felsberg J, Schackert G, et al. DNA methylation-based classification of ependymomas in adulthood: implications for diagnosis and treatment. *Neuro Oncol* 2018;20:1616-24. doi: 10.1093/neuonc/noy118.
  21. Cho HJ, Park HY, Kim K, Chae H, Paek SH, Kim SK, et al. Methylation and molecular profiles of ependymoma: Influence of patient age and tumor anatomic location. *Mol Clin Oncol* 2021;14:88. doi: 10.3892/mco.2021.2250.
  22. Murphy ES, Chao ST, Angelov L, Vogelbaum MA, Barnett G, Jung E, et al. Radiosurgery for Pediatric Brain Tumors. *Pediatr Blood Cancer* 2016;63:398-405. doi: 10.1002/pbc.25831.
  23. Qureshi BM, Mansha MA, Karim MU, Hafiz A, Ali N, Mirkhan B, et al. Impact of Peer Review in the Radiation Treatment Planning Process: Experience of a Tertiary Care University Hospital in Pakistan. *J Glob Oncol* 2019;5:1-7. doi: 10.1200/JGO.19.00039.
  24. Tashvighi M, Mehrvar A, Hedayati Asl AA, Mehrvar N, Ghorbani R, Naderi A, et al. Treatment challenges and outcomes for pediatric intracranial ependymoma at a single institution in Iran. *Pediatr Hematol Oncol* 2018;35:60-75. doi: 10.1080/08880018.2018.1435758.
  25. Indelicato DJ, Ioakeim-Ioannidou M, Bradley JA, Mailhot-Vega RB, Morris CG, Tarbell NJ, et al. Proton Therapy for Pediatric Ependymoma: Mature Results From a Bicentric Study. *Int J Radiat Oncol Biol Phys* 2021;110:815-20. doi: 10.1016/j.ijrobp.2021.01.027.
  26. MacDonald SM, Safai S, Trofimov A, Wolfgang J, Fullerton B, Yeap BY, et al. Proton radiotherapy for childhood ependymoma: initial clinical outcomes and dose comparisons. *Int J Radiat Oncol Biol Phys* 2008;71:979-86. doi: 10.1016/j.ijrobp.2007.11.065.
  27. Qureshi BM, Mansha MA, Karim MU, Hafiz A, Ali N, Mirkhan B, et al. Impact of Peer Review in the Radiation Treatment Planning Process: Experience of a Tertiary Care University Hospital in Pakistan. *J Glob Oncol* 2019;5:1-7. doi: 10.1200/JGO.19.00039.
  28. Waqas M, Abbasi AN. Establishment of site specific multi-disciplinary tumour boards in Pakistan: Sharing experience of neuro oncology team based at a tertiary care university hospital. *J Pak Med Assoc* 2017;67:486.
  29. Sun XY, Kong C, Lu SB, Sun SY, Guo MC, Ding JZ. Survival outcomes and prognostic factors of patients with intramedullary Grade II ependymomas after surgical treatments. *J Clin Neurosci* 2018;57:136-42. doi: 10.1016/j.jocn.2018.08.001.

---

#### DISCLAIMER

Articles published in JPMA and Supplements of JPMA do not represent the views of the editor or editorial Board. Authors are solely responsible for the opinions expressed and the accuracy of the data.

The contribution of each author towards the published research included in this supplement is the responsibility of the authors and their institutions. It is expected to be in accordance and compliance with the ICMJE Guidelines.

Any questions/queries raised by readers should be directed to the corresponding author.

## NARRATIVE REVIEW

## Consensus guidelines for the management of intracranial meningioma for low- and middle-income countries

Syed Ather Enam<sup>1</sup>, Mehar Masroor<sup>2</sup>, Saqib Kamran Bakhshi<sup>3</sup>, Fatima Shaukat<sup>4</sup>, Hafiza Fatima Aziz<sup>5</sup>, Kaynat Siddiqui<sup>6</sup>, Mohammad Hamza Bajwa<sup>7</sup>, Muhammad Shakir<sup>8</sup>, Rabeet Tariq<sup>9</sup>, Altaf Ali Laghari<sup>10</sup>

**Pakistan Brain Tumour Consortium:** Authors list at the end of the supplement.

### Abstract

Intra-cranial meningiomas represent the most common type of extra-axial brain tumour in adults. Characteristically slow-growing and often asymptomatic, these tumours may only require observation in some cases. However, lesions that cause a significant mass effect necessitate intervention, primarily through surgical means. Additionally, in cases of significant unresectable low-grade residual meningioma or high-grade tumours, radiation therapy becomes essential. Notably, current management guidelines predominantly reflect data derived from high-income countries, failing to address constraints prevalent in the developing world, such as limited financial resources and restricted access to advanced surgical facilities. This manuscript introduces guidelines specifically tailored for the management of meningioma in patients from low- and middle-income countries, considering their unique healthcare challenges and resources.

**Keywords:** Meningioma, brain neoplasms, health care, neurooncology.

**DOI:** <https://doi.org/10.47391/JPMA.S3.GNO-18>

### Introduction

Meningiomas, arise from meningeal cells of the central nervous system, and are the most frequent extra-axial primary brain tumour in adults. Age-related increase in meningioma incidence has been found and overall accounts for 37.6% of all primary brain tumours. Of these, 54.3% are reported as benign.<sup>1</sup> They are uncommon in children and are frequently found in women between 40 and 60 years of life. Most of them occur spontaneously, but some are familial (found in relation to neurofibromatosis, von Hippel-Lindau syndrome and some other syndromes) or occur after radiotherapy.

.....  
<sup>1-3,5-8,10</sup>Department of Neurosurgery, The Aga Khan University, Karachi, Pakistan. <sup>4</sup>CyberKnife and Tomotherapy Centre, Jinnah Post Graduate Medical Centre, Karachi, Pakistan. <sup>9</sup>Jumma Research Laboratories, The Aga Khan University, Karachi, Pakistan

**Correspondence:** Syed Ather Enam **Email:** [ather.enam@aku.edu](mailto:ather.enam@aku.edu)

Meningiomas are most commonly found on the surface of the brain such as cerebral convexity and parasagittal regions, followed by the medial and lateral base of the skull regions. Compared to medial skull base meningioma, non-skull base and lateral skull base meningioma have a higher frequency of atypia and malignancy, as well as higher recurrence rate.<sup>2</sup> The World Health Organization (WHO) categorizes meningioma in 3 histologic grading: Grade 1 is the most common and has a benign course, while Grades 2 and 3 are not very common but have more aggressive course and higher recurrence rate.<sup>3</sup> The 5-year survival rate for non-malignant meningioma is approximately 88% which reduces to 66.5% in cases of malignant meningioma.<sup>4</sup>

Due to resource constraints in low- and middle-income countries (LMIC), many patients with meningioma do not seek timely treatment. Current guidelines on meningioma management are based on data from developed countries, and do not take into account the limitations of LMICs. These guidelines provide comprehensive framework for effective management of patients diagnosed with meningioma in resource limited settings.

### Methodology

A systematic database search was done in July 2023 to identify gaps in the diagnosis and management of intracranial meningioma in the low- and middle income countries. The literature search of the high-quality data on meningiomas was done on different databases including PubMed, Google Scholar, Scopus, and Embase. The most relevant and high-quality studies were analysed to develop the evidence-based recommendations. A panel of experts comprising neurosurgeons, oncologists, neuro-radiologists, radiation oncologists and neuropathologists collected and analysed published evidence within their respective fields regarding the diagnosis and management of intracranial meningioma. These evidences were collected to identify the best-practice recommendations for the management of intracranial meningioma in LMIC settings. After extracting the data of local and regional published articles, the data was reviewed and discussed with senior faculty of each

working group. Expert opinions were used to decide the quality of evidence. Recommendations were made for the practical application of best-practice guidelines to LMIC settings, such as in Pakistan.

## Initial evaluation (Screening and diagnosis)

### Clinical presentation and evaluation

As with other intracranial tumours, the clinical presentation of intracranial meningioma varies based on its location and size. However, the majority of these meningiomas are asymptomatic and often diagnosed incidentally. They can be seen originating from any dural surface and if symptomatic, the clinical presentation results from the mass effect produced by compression of surrounding brain parenchyma or vascular structures and includes localised neurological impairments, seizures (generalized or focal), and signs and symptoms of elevated intracranial pressure such as headache and vomiting. Meningiomas typically have slow growth with a low incidence of metastasis and the common sites for meningioma metastasis include the lung, liver and bone. The 5-year survival rate of patients with meningioma also reduces with metastasis.<sup>5</sup>

### Diagnostic workup

MRI with contrast is the preferred diagnostic modality when there is clinical suspicion of a brain tumour. They typically appear as solitary round dural based tumours with homogenous and prominent contrast enhancement and adjacent dural enhancement (dural-tail sign). They are iso-intense with brain parenchyma on T1-weighted imaging and iso-intense or hyper-intense on FLAIR imaging. However, approximately 10-15% of meningiomas resemble metastases or malignant glioma on MRI with atypical features.<sup>6</sup>

However, when MRI is contraindicated (e.g. if the patient has a pacemaker) then CT scan with contrast can be used instead. On CT scan, meningioma usually appears iso-dense with brain parenchyma. Also, CT scan is more sensitive in defining bone remodelling features such as hyperostosis of skull as a result of slow growing meningioma, intraosseous tumour growth or in detection of psammomatous calcifications within meningioma which is seen in approximately 25% of cases. The neuroimaging features such as the presence of a dural-tail sign, calcification, uniform enhancement, and regular border suggest the presence of a more benign meningioma while the presence of peritumoural oedema, intratumoural necrosis, intratumoural cystic change, cortex invasion, bone destruction, and hyperostosis of the adjacent skull suggests the presence of a high grade meningioma.

As meningiomas are highly vascular tumours, cerebral angiography can also be performed in selected cases which can be followed by preoperative embolisation. During angiography, meningioma is found to have a dual arterial supply with pial arteries supplying the tumour's outermost area and dural arteries supplying the tumour's inner core. MR spectroscopy can also be used to differentiate between meningioma and other intracranial neoplasms particularly in patients who are unable to undergo surgery and observation is being considered.

### Management of meningioma

For asymptomatic, non-growing, incidentally diagnosed meningioma, only active monitoring can be done using annual clinical assessment and repeat imaging at regular intervals. However, the definitive diagnosis of a growing or symptomatic meningioma requires a surgical procedure to obtain tumour tissue for histological classification, grading and molecular genetics as this will guide all subsequent decision-making. Generally, the standard recommended treatment for growing or symptomatic meningioma is gross complete (total) resection including the removal of any involved dura. However, different radiation strategies are frequently used when surgical resection alone appears to be insufficient.

### Observation

Incidentally diagnosed meningioma that are asymptomatic and small ( $\leq 3$  cm in diameter) can be observed. These tumours can remain undiagnosed because of their slow growth and once diagnosed, close active monitoring with clinical and neuroimaging follow ups can be sufficient. This will avoid post-surgical complication risks associated with the surgical approach. However, before opting for observation in such cases, a careful evaluation of factors that can predict these tumours' growth is required. The two most significant radiographic findings are the presence of tumour calcification and the T2-weighted MRI signal intensity. Studies have shown gradual growth in tumours with calcification and hypointense signals on T2 weighted MRI, while there is rapid growth in tumours with hyperintense signals on T2 weighted MRI.<sup>7</sup> Therefore, a follow-up observation strategy can be explored in patients with radiological signs of slow-growing, asymptomatic meningioma. This strategy involves repeating imaging three or six months after diagnosis, then every year for five years, followed by once every two years.<sup>8</sup> This follow up strategy is complied until the tumour becomes symptomatic or large enough to consider surgical intervention. However, in elderly patients with shorter life expectancy and having benign radiological features there

is no need for follow up imaging.

### **Surgical technique**

The approach needed to resect intra-cranial meningioma or any other intra-cranial tumour depends on its size, location, proximity to intra-cranial neurovascular networks and the degree of dural attachment. The goal of resection is gross-complete removal of the tumour, which also includes removal of any associated dura. The extent of resection can be determined by the surgeon's own judgement and by a postoperative MRI that can be performed within 48 hours after surgery or can be delayed until three months postoperatively. The degree of surgical resection is also one of the most significant predictors for recurrence, as with sub-total resection, the likelihood of disease recurrence/ progression is high. Generally, subtotal resection is considered for tumours with difficult localization, such as skull base meningioma, even in cases of benign histologic grading of tumours with healthy brain invasion.

### **Pathologic assessment**

#### **Histopathology**

The classification used by the World Health Organization (WHO) for meningiomas is based on the histological features. Under the WHO 2021 classification method, meningiomas are classified as a single tumour type with 15 sub-categories. Grades range between WHO grade 1 (meningothelial, fibrous, transitional, psammomatous, angiomatous, microcystic, secretory and lymphoplasmacytic-rich meningioma), WHO grade 2 (atypical meningioma including brain infiltrative meningioma, choroid and clear cell meningioma), and WHO grade 3 (anaplastic/malignant meningioma).<sup>9</sup>

Grade 1 accounts for more than 80% of meningioma cases. Histologically, these tumours have benign features lacking anaplastic features found in the other two grades. The characteristics 'psammoma bodies' which are the result of calcification of meningeal cells can be seen in histopathology.

Grade 2 accounts for approximately 17% of meningiomas. The presence of necrosis, conspicuous nuclei, hyper cellularity, high nuclear-cytoplasmic ratio, or raised mitotic figures are some of the atypical characteristics seen in grade 2 meningioma. Furthermore, the likelihood of recurrence is higher with atypical meningiomas compared to benign meningioma.

Approximately 3% of meningiomas are WHO grade 3 and are known as anaplastic or malignant meningiomas. They have a high level of mitotic figures (at-least 20 mitoses per 10 high-power fields) and are associated with higher risk

for distant metastasis.

### **Adjuvant treatment Radiotherapy**

Meningioma outcomes and management strategies are mostly determined by the degree of surgical excision and the WHO histopathologic classification. Postoperative radiation therapy is recommended for WHO grade 3 meningioma, WHO grade 2 meningioma after sub-total excision or in some patients after gross complete resection because patients are frequently lost to follow-up, and WHO grade 1 meningioma with growing-residual tumour. However, radiation therapy is considered the preferred first line treatment in patients with inoperable meningioma such as those encasing neurovascular structures. Approximately 30-35% reduction in size of meningioma following radiation therapy have been observed in multiple studies with most occurring in the first 3 years after radiation.<sup>10</sup>

Dowook Kim et al. in their study, on patients treated with adjuvant radiotherapy for atypical meningioma, found that greater tumour size, higher mitotic figures and brain invasion affect the treatment outcomes while the degree of surgical excision was not found to affect the outcome after radiation therapy. Additionally, they also found a dose-response relationship between radiation exposure and the effectiveness of the treatment, with greater doses producing better survival results.<sup>11</sup>

The dose and volume of radiotherapy, therefore, may affect overall survival. According to recent studies, depending on the tumour's extent, stereotactic and fractionated radiotherapy can be used in patients with WHO grade 1 meningioma after sub-total resection. Stereotactic radiation (12–16 Gy in a single dose) is preferred over fractionated radiotherapy (54 Gy administered at 1.8 Gy per fraction) for small tumours. For WHO grade 2, the role of adjuvant radiotherapy after gross total resection is unclear, however, after subtotal resection adjuvant fractionated radiation (54-60 Gy administered at 1.8-2.0 Gy per fraction) is advised.<sup>12</sup> Regardless of the degree of surgical resection, all patients with WHO grade 3 meningioma, including those who have a TERT promoter mutation and/or CDKN2A/B deletion, need postoperative radiation therapy. Due to the aggressive clinical history of these meningiomas, recent studies have recommended radiation dosages of 60 Gy administered at 2.0 Gy per fractions. NRG-Oncology Radiation Therapy Oncology Group (RTOG) conducted a Phase II clinical trial in which meningioma patients were categorized in three prognostic groups based on the WHO grade of tumour, presence of recurrence and the



**Table-1:** Summary of Radiation Therapy recommendation based on prognostic group.

RISK GROUP	DESCRIPTION	RADIATION DOSE	VOLUME
LOW RISK	WHO grade 1 meningioma s/p GTR or STR	Observation	-----
INTERMEDIATE RISK	WHO grade 2 meningioma S/P GTR Recurrent WHO grade I meningioma	54 Gy/30 fractions	Margin of 1cm
HIGH RISK	WHO grade 3 meningioma (any resection) WHO grade 2 meningioma S/P STR Recurrent WHO grade 2 meningioma	60 Gy/30 fractions	Margin of 2 cm

S/P: surgical procedure, GTR: Gross total resection, STR: Subtotal resection, Gy: Gray.

degree of tumour resection.<sup>13</sup> Table-1 summarizes the recommendation for radiation therapy according to prognostic group of patients as per this trial. RTOG trial also shows improved outcomes with Intensity Modulated Radiation Therapy (IMRT) for high grade meningioma.

### Chemotherapy

There is currently insufficient data to determine the significance of chemotherapy in the management of meningioma. For patients with recurrent meningioma, surgically not accessible and not responding to radiotherapy, National Comprehensive Cancer Network (NCCN) guidelines recommend alpha-interferon analogue, somatostatin (growth hormone-inhibiting hormone) receptor agonist and vascular endothelial growth factor (VEGF); however, there are no conclusive studies determining the efficacy levels of these medications.<sup>14</sup> Palbociclib, a CDK4/6 inhibitor, was found to enhance radiation activity against meningioma especially when meningioma cells were p-16 deficient and Rb intact, diminishing cell growth in vivo using mouse models with aggressive meningioma.<sup>15</sup> A phase II clinical trial was conducted using Nivolumab, a programmed cell death protein 1 blocker, in patients with recurrent/ anaplastic meningioma and results showed no significant side effects with this drug; however, there was also no significant improvement in progression-free survival.<sup>16</sup> More research and clinical studies are needed to transform the effectiveness of chemotherapy in the treatment of meningioma.

### Management/ follow-up after surgery

The standard recommended treatment options are surgery and radiation therapy. Postoperatively, frequent neuroimaging at regular intervals along with clinical assessment is recommended according to WHO grade of tumours. For any grade, the first follow up should be after 3 months and thereafter, it depends on the WHO grade of tumour. For WHO grade 1 patients, follow-up is

recommended every year for the first five years, then every two years. For WHO grade 2 patients, every six months for the first five years, then yearly. For WHO grade 3 patients, further follow ups should be every 3-6 months.<sup>8</sup> For any grade, if 5-year scans do not show any increase in size of residual disease or any recurrence then follow-up can be discontinued; but if there is recurrence/ increase in size of residual disease then continue follow-up as recommended.

### Miscellaneous/ prognosis/ outcomes/ quality of life

The prognosis for meningioma is generally favorable. Patients with WHO grade 1 tumour often have a five-year progression-free survival rate of about 90%, WHO grade 2 patients typically have a five-year progression-free survival rate of 60-90% and WHO grade 3 patients have a rate of 28% after gross complete resection. However, for a 10-year overall survival rate, this decreases to 53% for patients with grade 2 and 0% for patients with grade 3 even after receiving the best possible treatment.<sup>17</sup> Prognosis depends on factors such as age, symptoms burden, histological tumour grade and extent of resection. Meningioma grade is also correlated with the degree of prognosis with grade 3 having higher risk of recurrence and worse prognosis. The health related quality of life is also affected and the known risk factors for worse quality of life includes tumour size, location, histological grade, seizure burden and recurrent tumour. Identifying at-risk patients, such as those with high grade meningioma, frontal or skull base location or larger size tumours, can help in counselling the patients regarding their expected quality of life.

### Gaps in knowledge

There is still a need for further research in meningioma with the recent emerging large scale molecular studies, in particular genomic and epigenomic, to improve current management strategies for patients in LMIC. New

**Table-2:** Summary of Recommendations for Meningioma.

<b>Radiology</b>	<ul style="list-style-type: none"> <li>• MRI brain with and without contrast.</li> <li>• 'Minimum required' MRI protocol:               <ul style="list-style-type: none"> <li>o Imaging on at least 0.5T.</li> <li>o Sequences: Axial T2 and coronal or axial FLAIR sequence; pre-contrast T1 and contrast enhanced T1.</li> </ul> </li> <li>• Tumour location, tumour margins, enhancement pattern, size, vascular supply, venous sinus and bone involvement, and presence of haemorrhage/mineralization.</li> <li>• CTA can aid surgical planning in selected cases.</li> <li>• First postoperative MRI is recommended after 6 months for grade 1 and 3 months for grade 2/3.               <ul style="list-style-type: none"> <li>o To identify the extent of resection.</li> <li>o To have a baseline to compare successive imaging.</li> </ul> </li> </ul>
<b>Neurosurgery</b>	<p><b>Surveillance</b></p> <ul style="list-style-type: none"> <li>• Asymptomatic, small, non-growing, incidentally diagnosed meningioma, only active monitoring is recommended.</li> <li>• Repeat clinical evaluation and MRI after 3 months then 6 months then annually for 5 years, followed by every 2 years until the tumour becomes symptomatic or large enough to consider surgical intervention.</li> </ul> <p><b>Surgery</b></p> <ul style="list-style-type: none"> <li>• Extent of resection depends on tumour size, location, proximity to neurovascular structures and the extent of dural involvement.</li> <li>• GTR including the resection of involved dura and overlying bone is recommended.</li> <li>• STR can be considered for tumours located near critical neurovascular structures.</li> </ul>
<b>Neuropathology</b>	<ul style="list-style-type: none"> <li>• Haematoxylin and eosin (H&amp;E) preparation for histological typing.</li> <li>• Histopathological assessment should assess mitotic activity, atypical/ anaplastic features like necrosis, cellularity, and glial invasion to classify according to the WHO classification system.</li> <li>• Immunohistochemical stains EMA, S-100, CD34, STAT-6 and GFAP to differentiate from non-meningeal tumours.</li> </ul>
<b>Medical &amp; Radiation Oncology</b>	<ul style="list-style-type: none"> <li>• Radiation therapy can be considered as the first line in patients with unresectable meningioma.</li> <li>• Postoperative radiation is advised in WHO grade 3 (regardless of EOR), WHO grade 2 after STR, and in cases of recurrence irrespective of the grade.</li> <li>• Radiation can be considered in patients with LMIC limitations in WHO grade 2 with GTR and grade 1 with STR.</li> </ul>

Continued on next column...

Continued on next column...

<b>Follow-up</b>	<ul style="list-style-type: none"> <li>• Conformal radiation with advanced techniques such as 3DCRT/IMRT/VMAT with a conventional fractionation schedule is recommended. However, for grade 1 meningioma stereotactic radiation can be considered in selected patients.</li> <li>• The common radiation dose for grade 1 is 54 Gy given at 1.8 Gy per fraction, for grade 2 is 54–60 Gy given at 1.8–2.0 Gy per fraction, and for grade 3 is 60 Gy given at 2.0 Gy per fraction for five days a week for 6–7 weeks.</li> <li>• Stereotactic radiation treatment can be considered as the preferred radiation approach in re-irradiation settings in centres having site-specific expertise and practice after discussion in radiation oncology peer review meetings.</li> <li>• Chemotherapy has not yet proven to be effective in the treatment of meningioma.</li> </ul>
<b>Follow-up</b>	<ul style="list-style-type: none"> <li>• First follow-up at post-op day 10 for wound assessment, stitch removal, discussion related to histopathology and NOTB recommendations.</li> <li>• For WHO grade 1, annually for five years and then every two years.</li> <li>• For WHO grade 2, every 6 months for five years and then annually.</li> <li>• For WHO grade 3, further follow-ups should be every 3–6 months.</li> <li>• For all grades, if the 10-year scan is satisfactory, follow-up can be discontinued but if recurrence is detected, then an annual scan is recommended.</li> </ul>

MRI: Magnetic resonance imaging, FLAIR: Fluid-attenuated inversion recovery, CSF: Cerebrospinal fluid, VPS: Ventriculoperitoneal shunt, ETV: endoscopic third ventriculostomy, NOTB: Neuro-oncology tumour board, EPN: Ependymoma, MIB1: Mindbomb Homolog-1, ZFTA: Zinc Finger Translocation Associated, STR: Subtotal resection, Gy: Gray.

research including molecular studies can aid in the investigation of molecular pathology diagnostics, predictive algorithms and treatment modalities for meningioma.

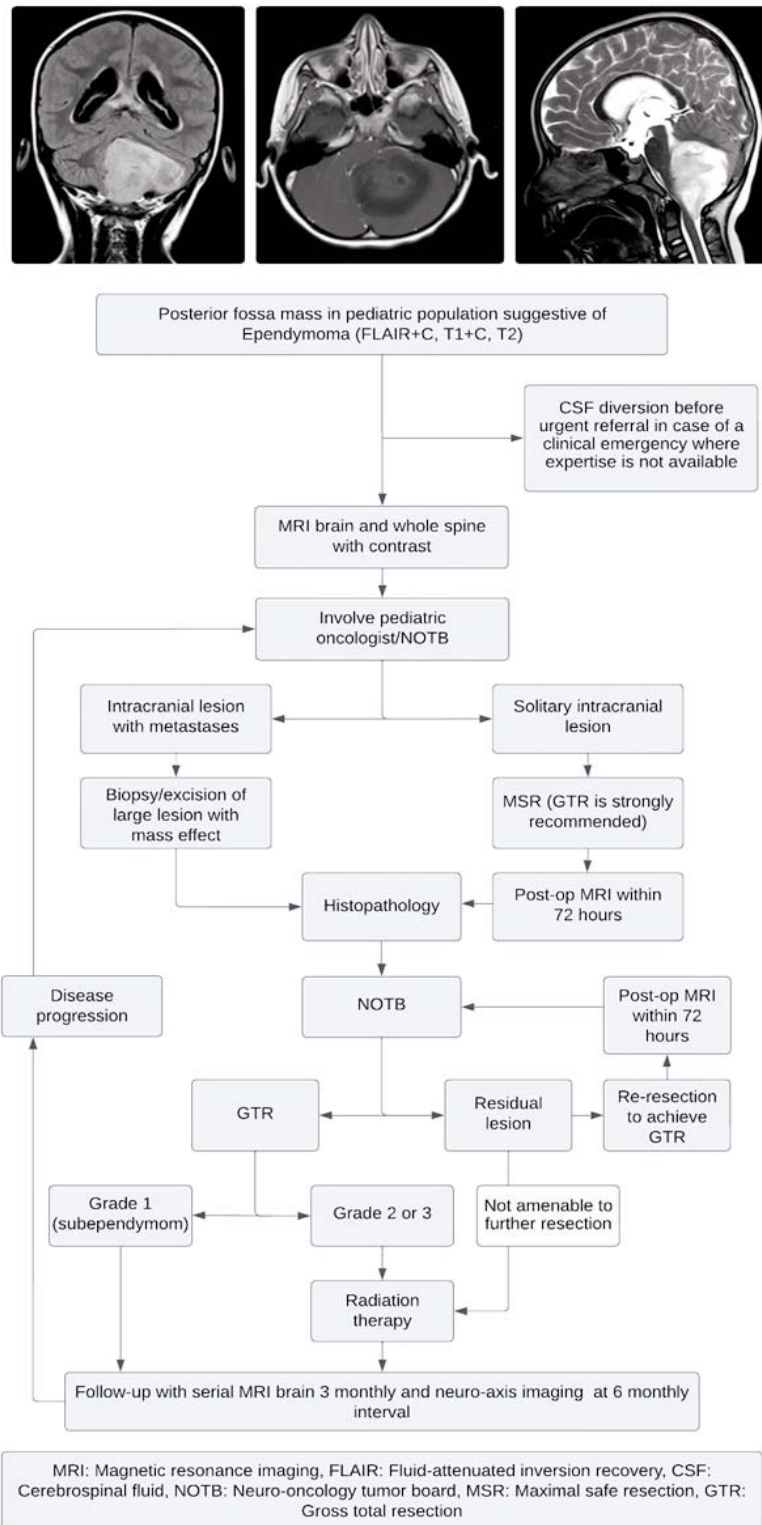
### Conclusion

These guidelines are formulated based on valuable experience (refer to Table 2 and Figure 1) and are designed for physicians working in low-resource setups. Their application has significant potential to improve outcomes and aims for a strong emphasis on multidisciplinary care within LMICs, such as Pakistan.

**Disclaimer:** None.

**Conflict of Interest:** None.

**Funding Disclosure:** None.



**Figure-1:** Management of intracranial meningioma algorithm.

## References

- Ogasawara C, Philbrick BD, Adamson DC. Meningioma: A Review of Epidemiology, Pathology, Diagnosis, Treatment, and Future Directions. *Biomedicines* 2021;9:319. doi: 10.3390/biomedicines9030319.
- Maiuri F, Mariniello G, Guadagno E, Barbato M, Corvino S, Del Basso De Caro M. WHO grade, proliferation index, and progesterone receptor expression are different according to the location of meningioma. *Acta Neurochir (Wien)* 2019;161:2553-61. doi: 10.1007/s00701-019-04084-z.
- Louis DN, Perry A, Wesseling P, Brat DJ, Cree IA, Figarella-Branger D, et al. The 2021 WHO Classification of Tumors of the Central Nervous System: a summary. *Neuro Oncol* 2021;23:1231-5. doi: 10.1093/neuonc/noab106.
- Ostrom QT, Truitt G, Gittleman H, Brat DJ, Kruchko C, Wilson R, et al. Relative survival after diagnosis with a primary brain or other central nervous system tumor in the National Program of Cancer Registries, 2004 to 2014. *Neurooncol Pract* 2020;7:306-12. doi: 10.1093/nop/npz059.
- Montgomery EY, Sundararajan C, Pernik MN, Caruso JP, Garzon-Muvdi T. Metastatic meningioma: A systematic review of incidence and risk factors. *Interdisciplinary Neurosurgery* 2023;32:101720. Doi: 10.1016/j.inat.2023.101720.
- Buetow MP, Buetow PC, Smirniotopoulos JG. Typical, atypical, and misleading features in meningioma. *Radiographics* 1991;11:1087-106. doi: 10.1148/radiographics.11.6.1749851.
- Lee EJ, Kim JH, Park ES, Kim YH, Lee JK, Hong SH, et al. A novel weighted scoring system for estimating the risk of rapid growth in untreated intracranial meningiomas. *J Neurosurg* 2017;127:971-80. doi: 10.3171/2016.9.JNS161669.
- Goldbrunner R, Minniti G, Preusser M, Jenkinson MD, Sallabanda K, Houdart E. et al. EANO guidelines for the diagnosis and treatment of meningiomas. *Lancet Oncol* 2016;17:e383-91. doi: 10.1016/S1470-2045(16)30321-7.
- Torp SH, Solheim O, Skjulsvik AJ. The WHO 2021 Classification of Central Nervous System tumours: a practical update on what neurosurgeons need to know-a minireview. *Acta Neurochir (Wien)* 2022;164:2453-64. doi: 10.1007/s00701-022-05301-y.
- Fega KR, Fletcher GP, Waddle MR, Peterson JL, Ashman JB, Barrs DM, et al. Analysis of MRI Volumetric Changes After Hypofractionated Stereotactic Radiation Therapy for Benign Intracranial Neoplasms. *Adv Radiat Oncol* 2018;4:43-9. doi: 10.1016/j.adro.2018.08.013.
- Kim D, Chang WI, Byun HK, Kim IA, Cho J, Lee JH, et al. Dose-response relationship in patients with newly diagnosed atypical meningioma treated with adjuvant radiotherapy. *J Neurooncol* 2023;161:329-37. doi: 10.1007/s11060-022-04206-1.
- Abd El-Bary TH, Samir MA, Elgaddar AAI, El-Shiekh MMO. Brief Insight About Management Of Meningioma. *J Pharm Negat Results* 2023;14:610-8. DOI: 10.47750/pnr.2023.14.S02.74.
- Rogers L, Zhang P, Vogelbaum MA, Perry A, Ashby LS, Modi JM, et al. Intermediate-risk meningioma: initial outcomes from NRG Oncology RTOG 0539. *J Neurosurg* 2018;129:35-47. doi: 10.3171/2016.11.JNS161170.
- Karsy M, Guan J, Cohen A, Colman H, Jensen RL. Medical Management of Meningiomas: Current Status, Failed Treatments, and Promising Horizons. *Neurosurg Clin N Am* 2016;27:249-60. doi: 10.1016/j.nec.2015.11.002.
- Horbinski C, Xi G, Wang Y, Hashizume R, Gopalakrishnan M, Phillips JJ, et al. The effects of palbociclib in combination with radiation in preclinical models of aggressive meningioma. *Neurooncol Adv* 2021;3:vdab085. doi: 10.1093/nojnl/vdab085.
- Bi WL, Nayak L, Meredith DM, Driver J, Du Z, Hoffman S, et al. Activity of PD-1 blockade with nivolumab among patients with recurrent atypical/anaplastic meningioma: phase II trial results. *Neuro Oncol* 2022;24:101-13. doi: 10.1093/neuonc/noab118.
- Buerki RA, Horbinski CM, Kruser T, Horowitz PM, James CD, Lukas RV. An overview of meningiomas. *Future Oncol* 2018;14:2161-77. doi: 10.2217/fo-2018-0006.

### DISCLAIMER

Articles published in JPMA and Supplements of JPMA do not represent the views of the editor or editorial Board. Authors are solely responsible for the opinions expressed and the accuracy of the data.

The contribution of each author towards the published research included in this supplement is the responsibility of the authors and their institutions. It is expected to be in accordance and compliance with the ICMJE Guidelines.

Any questions/queries raised by readers should be directed to the corresponding author.

## Consensus guidelines for the management of brain stem and diffuse midline glioma for low and middle-income countries

Hafiza Fatima Aziz<sup>1</sup>, Naureen Mushtaq<sup>2</sup>, Fatima Suleman<sup>3</sup>, Asim Hafiz<sup>4</sup>, Mohammad Hamza Bajwa<sup>5</sup>, Ahmed Gilani<sup>6</sup>, Kaynat Siddiqui<sup>7</sup>, Altaf Ali Laghari<sup>8</sup>, Muhammad Usman Khalid<sup>9</sup>, Saqib Kamran Bakhshi<sup>10</sup>

**Pakistan Brain Tumour Consortium:** (Authors list at the end of the supplement), Syed Ather Enam<sup>11</sup>.

### Abstract

The understanding of brainstem gliomas and diffuse midline gliomas has significantly increased in the last decade. However, the management paradigm remains a dilemma. The critical location is the foremost factor dictating the outcome. Recent advancements in the field of neuro-oncology are pushing the boundaries of optimal care in the developed world nevertheless, the strategies in low- and middle-income countries (LMICs) need to be tailored according to the resources to improve outcome. The objective of these guidelines is to provide an algorithm-based management plan to cater challenges for healthcare providers in LMICs.

**Keywords:** Algorithms, brain stem, glioma.

**DOI:** <https://doi.org/10.47391/JPMA.S3.GNO-19>

### Introduction

Brainstem gliomas are glial tumours, divided anatomically and clinically into diffuse intrinsic pontine (DIPG), exophytic medullary, tectal, cervicomedullary, and focal gliomas. Genomic studies show that these tumours can broadly be divided into 3 molecular groups, namely: 1) histone mutant tumours with H3K27M mutation, 2) IDH mutant tumours, and 3) H3 wild-type and IDH wild-type tumours. Up to 2/3rd of all DIPG and non-pontine diffuse midline gliomas (DMGs) harbour a mutation in histone H3 genes wherein lysine 27 is substituted with methionine (H3K27M). Their aggressive behaviour, poorer prognosis, and a common mutation was the justified reason for grouping them as a separate entity.<sup>1,2</sup> Infratentorial/brainstem IDH mutant gliomas are less common but likely under-reported due to the difficulty in diagnosis as most have non-canonical IDH mutations (which are not

identified by IDH immunostain).

Brainstem gliomas make up only about 1-2% of adult malignant CNS neoplasms, however, they are more frequent in children.<sup>3</sup> DMGs are mainly found in pons, however, they can occur among any of the midline structures, including the brainstem, spinal cord, cerebellum, and thalamus.

Histologically, brainstem gliomas can be categorized into grades 1-4, however recent studies show that molecular group (H3K27M, IDH mutant or H3-wildtype/ IDH-wild type) is a stronger predictor of clinical behaviour. Grade 1 is restricted to localized tumours without histologic or radiologic evidence of invasion into the surrounding brain. The signs and symptoms might range from cranial nerve impairments to long tract signs, as well as limb and trunk ataxia, depending on the location and degree of spread.<sup>1,4</sup> DMGs are classified as WHO Grade 4 with even less than a year's survival.<sup>1</sup>

Factors predicting prognosis comprise poorly differentiated architecture, large size, tumour duration of more than 3 months, age 40 years or more, and low Karnofsky Performance Scale ( $KPS \leq 70$ ) are associated with a poorer prognosis.<sup>4</sup> Treatment options mainly include maximal safe resection, chemotherapy, and/or radiotherapy<sup>4, 5</sup>; however, we still find room in the literature for discussions on the best ways to treat these tumours, particularly in adults. Most of the literature on brainstem lesions comes from high-income countries and hence the treatment paradigm, cannot be applied to low-income countries (LMICs), where limited resources need to be aligned with the outcome. Here we formulated guidelines for brainstem and diffuse midline gliomas, supported by the evidence and working dynamics in LMICs

### Methodology

The literature search of the high-quality data on brain stem and midline gliomas was done in March 2023 on different databases including PubMed, Google Scholar, Scopus, and Embase. The most relevant and high-quality

<sup>1,3,5,7,8,10,11</sup>Department of Neurosurgery, The Aga Khan University,

<sup>2</sup>Department of Paediatric Oncology, The Aga Khan University, <sup>4</sup>Department of Radiation Oncology, The Aga Khan University, Karachi, Pakistan,

<sup>6</sup>Department of Pathology, University of Colorado, Children's Hospital Colorado, USA, <sup>9</sup>Department of Neurosurgery, University of Kentucky, Lexington, USA.

**Correspondence:** Syed Ather Enam Email: [ather.enam@aku.edu](mailto:ather.enam@aku.edu)

studies were analyzed to develop the evidence-based recommendations. An expert panel was convened consisting of specialists and leading experts within the field of neuro-oncology to identify the gaps in diagnosis and management of brain stem and midline gliomas within Pakistan. This group was tasked with identifying best-practice recommendations and their application within the context of Pakistan as an LMIC. Recommendations were collated, reviewed and debated regarding utility and evidence-based practices, in a process that has been previously detailed.<sup>6</sup>

## Epidemiology

The majority of cancer registries focus on histopathology, and the true incidence is unknown as biopsy is not usually recommended for the diagnosis of these tumours.<sup>7</sup> Even when recommended (to distinguish DMGs from DIPGs), it is rarely performed due to the critical location.<sup>1</sup>

Most LMICs lack well-established brain tumour registries. According to the most recent Central Brain Tumour Registry of the United States (CBTRUS) data from 2019, 4.4% of all gliomas are found in the brainstem.<sup>8</sup> The majority of paediatric brain tumour deaths are caused by diffuse pontine gliomas.<sup>7</sup>

## Classification

Brainstem gliomas are classified into pontine, medullary, and midbrain gliomas based on the anatomical location, based on imaging features into diffuse and focal (less than 2cm, with no edema) tumours. The direction and size of the tumour, magnitude of brainstem involvement, growth pattern (intrinsic or exophytic), and presence of haemorrhage, necrosis, or hydrocephalus can be used to further categorise these tumours.<sup>8</sup>

Choux et al classified them as (1) diffuse intrinsic or exophytic; (2) focal intrinsic or exophytic, (cystic or solid); (3) dorsal or lateral exophytic, arising in the subependymal zone and growing into the fourth ventricle; and (4) cervicomedullary, excluding cervical cord tumours that respect the border of the medulla.<sup>9</sup>

In 2021, the DMG classification was further updated from 'DMG, H3K27M-mutant' to 'DMG, H3K27M-altered' to ensure that other alterations such as EZHIP protein overexpression are included as well which can better explain this entity, in addition to the previously recognized H3K27 mutations.<sup>10</sup>

## Initial evaluation

### Screening and prevention

Although gliomas are typically sporadic, they can be linked to a few familial diseases, including Turcot, Li-

Fraumeni, Lynch syndromes, and neurofibromatosis type I. Neuroimaging is only performed during the early diagnostic work-up for screening. Unless new symptoms favouring an intracranial pathology emerge, repeat imaging is not advised. When counselling and testing unaffected relatives of glioma patients who are found to be carriers of germline mutations linked to gliomagenesis, clinical geneticists should be consulted. However, glioma growth cannot be halted in any known way.<sup>11</sup> It is important to use caution when having costly screening imaging for gliomas in LMICs.

## Clinical presentation

A history and examination of patients help establish localizing signs and symptoms along with recognition of warning signs of neurological deterioration. In general, the progression of neurological signs and symptoms serves as an estimate of glioma growth, with fast-growing tumours causing symptoms merely weeks before detection and slow-growing tumours requiring years before diagnosis.<sup>11</sup> Duration of symptoms is more determinant of prognosis than symptoms themselves.<sup>12,13</sup>

The symptomatology depends on the location and extent of the tumour. Non-specific manifestations include fatigue and headache.<sup>11</sup> Diffuse gliomas, commonly called Diffuse Intrinsic Pontine Gliomas (DIPG) are aggressive tumours that produce widespread brainstem oedema. They frequently appear with brainstem syndromes that include cranial nerve deficits, ataxia, and long tract signs, isolated or combined.<sup>12</sup> Hydrocephalus and intra-tumoural bleeding have also been seen at presentation in some patients.<sup>14</sup> Diffuse midline gliomas H3K27M mutant is the most aggressive subtype. Symptoms correlate with compression of adjacent structures i.e. midbrain, pons, or thalamus.<sup>1,15</sup>

Focal tumours are typically low-grade, and have a protracted course before diagnosis. Oculomotor dysfunction or cerebellar signs are mainly seen with upper brainstem tumours, while the lower ones mainly present with lower cranial nerve deficits and long tract findings. Tectal tumours can expand and compress the aqueduct of Sylvius, which is when they produce neurological symptoms secondary to obstructive hydrocephalus. Tegmental ones can present with hydrocephalus and oculomotor paresis with or without associated long tract findings. In cases of medullary involvement, the patient may present with lower cranial nerve dysfunction (hoarseness of voice, dysphagia, or recurrent chest infections due to micro-aspirations and ataxia).

Cervicomedullary brainstem gliomas progress slowly. Two main syndromes, a medullary and a cervical cord syndrome, have been described. Medullary dysfunction may manifest as failure to thrive due to nausea, vomiting, or dysphagia, upper respiratory tract infection, dysarthria, and sleep apnoea. Chronic neck pain, cervical myelopathy with weakness and spasticity are the symptoms of cervical cord dysfunction.<sup>16</sup>

The Neurological Assessment in Neuro-Oncology (NANO) Scale can be used to document the neurological examination and Mini-Mental State Examination (MMSE) can be used to document the neurocognitive status of adult patients.<sup>11</sup>

Delayed diagnosis has been shown to drastically impact outcomes.<sup>17</sup> Limited access to healthcare, delayed referral to imaging, higher costs, and far-off hospitals all contribute to delay in diagnosis, however, the most important variable delaying diagnosis is delayed parental and physician recognition of symptoms. Another important delay occurs in the correct and early referral of patients to neurological specialists. Tumour characteristics and symptoms, like behavioural changes which are not very commonly found, are often overlooked. Low-grade tumours with subtle signs are frequently disregarded and not investigated. Therefore, it's crucial to raise awareness among patients, parents as well as physicians regarding the symptomatology and the necessity to investigate accordingly.<sup>18</sup>

Confounding pathologies within the brainstem regions can be mistaken for brainstem glioma – adult patients with unclear radiological characteristics may benefit from

further workup. CSF analysis and systemic imaging may be useful in ruling out metastasis to the CNS or demyelinating pathology. Global neuro-oncology collaborations can help low-volume centers in pre-operatively discussing cases with a neuroradiologist or experts with experience in CNS imaging for optimizing the clinical approach.

### Diagnostic workup

The preferred diagnostic method is magnetic resonance imaging (MRI) both with and without contrast. An infiltrative T2/fluid-attenuated inversion recovery (FLAIR) high-signal lesion that occupies at least two thirds of the pons and frequently extends laterally into the cerebellum as well as vertically into the midbrain and medulla is the classic MRI picture. Contrast enhancement typically only accounts for 0–25 % of the tumour volume on average. Cysts are uncommon, however, necrosis can be present.<sup>19</sup>

Based on the MRI and location of the tumour, Choux et al classified brainstem gliomas into four main categories, and Yin L. et al further modified it as shown in Table.1<sup>9, 16</sup>

CT is more frequently employed in developing nations because of its greater accessibility and lower costs; however, tissue differentiation and delineating tumour involvement require MR imaging. Diffuse brainstem gliomas are often seen as diffuse enlargements iso-dense to the brain parenchyma or have a lower density and may exhibit partial enhancement. Focal gliomas may present as an exophytic or expansile lesion with heterogeneous density and prominent enhancement. Early diagnosis can be done if displacement of the fourth ventricle and compression of the cisterns is appreciated.<sup>20</sup> Compared

**Table-1:** Classification of brainstem gliomas.

Diffuse	Intrinsic	Enhancing (T1- Hypointense, contrast-enhancing, T2- hyperintense)
		Non-enhancing(T1- Hypointense, non- contrast enhancing, T2- hyperintense)
	Exophytic	Enhancing (T1- Hypointense invading surrounding structures, contrast-enhancing, T2- hyperintense)
		Non-enhancing T1- Hypointense not invading surrounding structures, contrast-enhancing, T2- hyperintense)
Focal (Midbrain, Pons, or Medulla Oblongata (solid or cystic)	Intrinsic	Enhancing (T1- Focal hypointense, contrast enhancing, T2- Focal hyperintense)
		Non-enhancing (T1- Focal Hypointense, non- contrast enhancing, T2- Focal hyperintense)
	Exophytic	Enhancing (T1- Focal hypointense not confined to the brainstem, contrast-enhancing, T2- Focal hyperintense)
		Non-enhancing (T1- Focal hypointense not totally confined to brainstem, non- contrast enhancing, T2- Focal hyperintense)

Dorsal or lateral exophytic, Cervicomedullary.

to MRI, CT has a substantially poor sensitivity for detecting and planning surgical intervention. As repeat MRIs significantly increase costs, patients frequently do not get them done at regular intervals, which might result in missed diagnoses or missed relapses after intervention.<sup>17</sup> CT scans are not indicated for follow-up as it has poor sensitivity and can miss small recurrence.

### Management of brainstem gliomas

Management of brainstem glioma requires a multidisciplinary approach that involves expertise from neurosurgery, medical oncology, radiation oncology, neuroradiology, and neuropathology, along with nursing and supportive care services to exchange ideas and define an optimal treatment plan. Studies have shown that it improves clinical outcomes and patient satisfaction hence it is highly recommended to discuss each case in a multidisciplinary neuro-oncology tumour board meeting before embarking on any treatment plan.

### Surgical management of brainstem gliomas

Careful patient selection is key to the successful management of brainstem gliomas. The main aims of surgery are: controlling raised intracranial pressure, providing tissue for histopathology, and decreasing the maximum possible tumour burden to improve neurological outcomes.<sup>21</sup> For diffuse brainstem gliomas, surgical intervention is not recommended. Tumours arising in the ventral midline pons are a common hallmark of diffuse, inoperable brainstem gliomas. T1-T2 inequality (T1 abnormality is volumetrically inequivalent/differing from the T2 signal), visibility of crossing pontine fibers, and symmetric encasement of the basilar artery are distinguishing radiological findings.<sup>5</sup>

For other brainstem gliomas like focal brainstem gliomas, the role of surgery and the surgical entrance point remains controversial. Usually, early surgery before the development of neurological complications, with maximal safe resection using intra-operative neuromonitoring is indicated. Tumours are most commonly approached via the posterior fossa in the prone position.<sup>16</sup> Since focal midbrain tumours are often indolent, they are typically treated conservatively; in the event of hydrocephalus, an endoscopic third ventriculostomy (ETV) should be performed. In LMICs, where access to specialized centres for multidisciplinary team and surgical expertise to perform specialized procedures like ETV are limited, CSF diversion such as ventriculoperitoneal (VP) shunt and then urgent referral should be considered. Implementing a one-on-one approach between referring and referred physicians significantly minimizes the risk of delayed care. Personal

and individualized strategy is also appropriate to link specialised physicians for a multidisciplinary team, especially in LMICs where a structured team approach is lacking.

Resection is necessary if the tumour increases in size, or if it occupies a significant portion of the midbrain and pineal region. A biopsy is advised at the point of tumour progression to best determine treatment for tumour recurrence. Serum concentrations of  $\alpha$  fetoprotein,  $\beta$  human chorionic gonadotrophin, and placental alkaline phosphatase can be used to identify the few non-germinomatous germ cell tumours. Biopsy may also be done in such cases while doing ETV. Focal tumours of the tegmentum also may be amenable to resection.<sup>16, 21</sup> Maximum safe resection of focal or exophytic pontine, medullary, and upper cervical spine tumours can be considered for symptomatic, extra-axial components. Intrinsic brainstem lesions are generally non-operable and considered the significant postoperative morbidity, except focal, benign gliomas where surgical intervention needs careful consideration.<sup>16</sup>

### Surgical management of diffuse midline gliomas

The brainstem, thalamus, and spinal cord are crucial structures and surgical resection here can lead to neurological problems that may be irreversible. Resection is not a viable option, with biopsy only considered in cases where the radiological diagnosis is unclear.<sup>1</sup>

For pontine and extrapontine DMGs, different recommendations and patient counselling may apply. Thalamic tumours have been shown to have improved survival outcomes following maximum safe resection when treated with superior facilities like MRI, neuronavigation, and/ or intra-operative neuromonitoring.<sup>22</sup> For spinal cord DMGs, the aim should be to achieve maximal safe resection. Thalamic and spinal cord DMGs have better prognoses than pontine DMGs, thus MSR is recommended.<sup>23</sup> Surgery is contraindicated for diffuse midline pontine gliomas.<sup>5</sup>

### Second surgery

Second surgery can be offered if there is delayed, recurrent growth of the tumour with new neurological symptoms, or if the resection had to be stopped prematurely on the initial attempt because of the transient intra-operative deficit.<sup>16</sup> These should be discussed in a multi-disciplinary tumour board weighing pre-operative functional status and goals of care for the patient.



## Pathologic assessment

DMG can be broadly classified into H3K27 altered, IDH mutant, and histone-wt, IDH-wt astrocytomas. DMG is usually reserved for astrocytic tumours with diffuse histology and should be distinguished from circumscribed gliomas such as pilocytic astrocytoma, and glioneuronal tumours such as gangliogliomas amongst other tumours. Histologically these tumours can be graded from 1-4 with grade 1 reserved for circumscribed/non-diffuse tumours. The role of histologic grading remains controversial as molecular features such as the presence of histone mutations often trump histologic grading.<sup>9</sup>

Grade 1 lesions (such as pilocytic astrocytoma and ganglioglioma) are uncommon, are histone and IDH wildtype and show better outcomes than diffuse tumours with these alterations. These tumours can be seen to occur throughout the brainstem, including the tectum of the midbrain, focally within the pons, or at the cervicomedullary junction where they are frequently exophytic. Diffuse tumours can be graded grade 2-4 depending upon the presence of proliferative index, i.e. mitoses and Ki67/ MIB1 count (grade 2 vs. 3), necrosis, and microvascular proliferation (grade 3 vs. 4)<sup>24, 25</sup>

Surrogate immunohistochemical markers can be used to identify H3K27M, BRAF V600E, and IDH1 R132H mutations. Tumours without these alterations require more molecular testing<sup>26</sup>, which remains expensive and difficult to perform and therefore largely out of reach of LMICs. Depending upon clinical need, selected cases may be sent to HIC centers with molecular analysis capacity.

## Radiotherapy

The aims of radiation therapy (RT) range from the relief of neurological symptoms in diffuse intrinsic gliomas to the complete removal of any remaining tumour after subtotal resection of focal tumours. Since surgery cannot be done for diffuse intrinsic pontine gliomas, radiotherapy is the mainstay of treatment, as chemotherapy has not yet demonstrated a substantial benefit. Although there may be some neurological improvement, there hasn't been any discernible difference in the patient's prognosis and survival.<sup>7</sup> The conventional median dose of radiotherapy is 50–55 Gy, using fractions of 1.8–2 Gy continuously for five days a week.<sup>27</sup> Ideally, the RT should begin within 1 week of diagnosis, and steroids may be used to manage life-threatening symptoms while waiting for RT to begin especially in LMICs where it might take longer. As a general rule, the treatment volume of the radiation field should enclose all the disease sites, called gross total volume (GTV) plus a margin of 1-2 cm (1 cm for low-grade

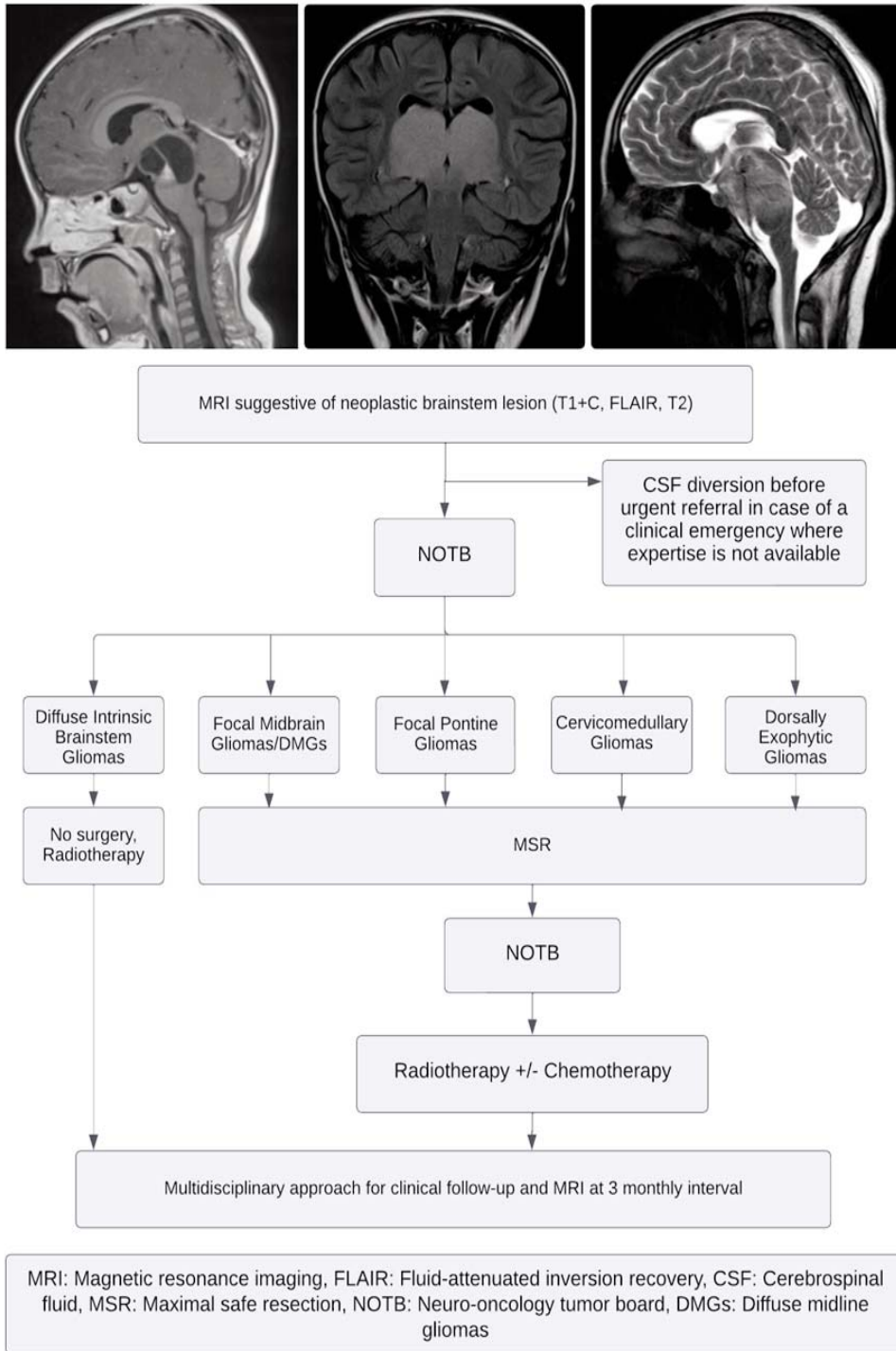
and 2cm for high-grade tumours) to incorporate microscopic disease.<sup>21</sup> For high-grade gliomas, GTV typically includes contrast-enhancing areas visible on the T1 contrast sequence of MRI and for low-grade gliomas, GTV is represented by hyperintense signal areas lesions seen on T2-weighted, FLAIR sequence of MRI.<sup>1</sup> It is important to remember that the majority of the time both patterns have been found on MRI due to heterogeneity of tumour population, hence, a careful review by a neuro-radiologist is crucial to delineate target volume adequately. In addition, a margin of 3-5mm is needed to incorporate daily setup variation according to individual institute data. Conventionally, fractionated RT is typically administered over 6 weeks with a total dose of 54-60 Gy at 1.8 – 2 Gy fraction with 3D conformal or IMRT/ VMAT techniques. In addition, peer review of radiation treatment plans at every level is an integral and essential tool of quality assurance programs and literature has shown its direct impact on clinical outcomes and patient care therefore it is highly recommended to be a part of every radiation therapy service.<sup>28</sup> Numerous clinical trials have compared conventional radiotherapy to altered fractionation schedules such as hyper- and hypofractionated radiation therapy however they failed to show any advantage as compared to the conventional radiation treatment. However, in a patient with poor performance status, a hypofractionated schedule emerges as an alternative approach with comparable clinical outcomes without significant toxicity.<sup>29</sup> The guidelines of RT are the same for diffuse midline gliomas as for diffuse brainstem gliomas. Re-irradiation in the case of tumour recurrence or progression is a highly challenging situation that requires careful patient selection and rigorous peer review of radiation treatment planning and should be considered in a center having expertise and supportive care services available. The role of stereotactic radiosurgery in the management of brainstem gliomas is evolving and should be only considered in the context of clinical trials as we do not have a good amount of literature on the side effects of RT.<sup>30</sup>

## Chemotherapy

As per most of the studies, chemotherapy hasn't been proven to be very effective in brainstem gliomas. Most of these tumours do not contain MGMT promoter methylation, making temozolomide and other chemotherapeutic agents ineffective.<sup>26, 27</sup>

## Post-operative management

Based on the tumour location, the degree of the resection, and the surgical technique, post-operative neurological impairments (temporary or irreparable) may



**Figure-1:** Management of Brain stem and diffuse midline glioma algorithm.

**Table-2:** Summary of Recommendations for Brainstem and Diffuse Midline Glioma.

<b>Radiology</b>	<ul style="list-style-type: none"> <li>• MRI brain with and without contrast.</li> <li>• 'Minimum required' MRI protocol:</li> <li>• Imaging on at least 0.5T.</li> <li>• Sequences: Axial T2 and coronal or axial FLAIR sequence; pre-contrast T1 and contrast enhanced T1.</li> <li>• Tumour location, tumour margins, enhancement pattern, tumour size, relation with critical neurovascular structure, and presence of haemorrhage/mineralization must be included.</li> <li>• Postoperative MRI is recommended within 72 hours of surgery. If delayed, then MRI should be performed after 6 weeks.               <ul style="list-style-type: none"> <li>o To identify the extent of resection.</li> <li>o To have a baseline to compare successive imaging.                   <ul style="list-style-type: none"> <li>o Not required after biopsy.</li> </ul> </li> </ul> </li> </ul>
<b>Neurosurgery</b>	<ul style="list-style-type: none"> <li>• The main aims of surgery are: controlling raised intracranial pressure, providing tissue for histopathology, and decreasing the maximum possible tumour burden to improve neurological outcomes.</li> <li>• The extent of resection depends on the tumour location and cranial nerve involvement within the brainstem.</li> <li>• Surgery is contraindicated in diffuse intrinsic brainstem gliomas.</li> <li>• Maximum safe resection with intra-operative neuromonitoring should be achieved wherever possible.</li> <li>• Maximum Safe Resection is preferred for DMGs, or at least biopsy is preferred where surgical resection is not possible.</li> </ul>
<b>Neuropathology</b>	<ul style="list-style-type: none"> <li>• Haematoxylin and Eosin (H&amp;E) slides for histological typing.</li> <li>• Immunohistochemical stains GFAP, Olig-2, p-53, IDH1 R132H, Ki-67 (proliferative marker), H3K27M to possible definite characterization.</li> </ul>
<b>Medical &amp; Radiation Oncology</b>	<ul style="list-style-type: none"> <li>• Radiation is the therapy of choice in diffuse intrinsic brainstem gliomas and diffuse midline gliomas.</li> <li>• Dose: 54 Gy in 30 fractions at 1.8 Gy per fraction or 39 Gy in 13 fractions at 3 Gy per fraction depending upon the availability of radiation service and the patient's performance status.</li> <li>• Radiation treatment shall be started urgently after a decision for radiation therapy has been taken in the neuro-oncology tumour board.</li> <li>• Chemotherapy can be considered after discussing in NOTB.</li> </ul>

Continued on next column...

Continued from previous column...

<b>Follow-up</b>	<ul style="list-style-type: none"> <li>• First follow-up at post-op day 10 for wound assessment, stitch removal, discussion related to histopathology, and NOTB recommendations.</li> <li>• Clinical follow-up with MRI every 3 months.</li> </ul>
------------------	--

MRI: Magnetic resonance imaging, FLAIR: Fluid-attenuated inversion recovery, DMGs: Diffuse midline gliomas, GFAP: Glial fibrillary acidic protein, TP53: Tumour protein 53, IDH: Isocitrate dehydrogenase, Gy: Gray, NOTB: Neuro-oncology tumour board.

manifest. Cranial nerve deficits vary with the tumour location. Transient diplopia due to internuclear ophthalmoplegia can occur if surgery is done within the pons. Ophthalmologic therapy with specialized eyeglass prisms may be required for persistent diplopia. Facial nerve injury can cause facial palsy and corneal abrasions due to problems with eye closure. Lower cranial nerve damage can lead to severe dysphagia, vocal cord paralysis, and loss of gag and cough reflexes. Aspiration and recurrent pneumonia can occur because of this. Thus, proper post-op swallowing evaluation is mandatory. In case of medullary involvement of the tumour, the patient is left intubated for at least 48-72 hours and is only weaned off after 24 hours of stable respiratory drive. Due to these reasons, tracheostomy and feeding tube placements are often planned in these patients.<sup>16</sup> Limited access to resources like speech therapist, occupational therapist, nursing care, and rehabilitation care in low- and middle-income countries can significantly hinder post-op patient care. Therefore, Emphasizing the significance of safe surgery and preservation of neurological functions cannot be overstated in resource-limited settings for better quality of life.

The cornerstone of the management of brainstem and diffuse midline gliomas is a multidisciplinary approach, as it is with all brain tumours. To correctly diagnose and effectively manage these illnesses neurosurgeons, medical and radiation oncologists, paediatric oncologists, histopathologists, and radiologists collaborate on tumour boards.<sup>17</sup> Virtual tumour board meetings have been adopted at a few centres and can help manage complex interdisciplinary cases in centers with lower volume or limited resources. This might help to significantly decrease mismanagement and treatment delays. In LMICs, virtual tumour boards can potentially revolutionise the management paradigm for these complex cases without adding a significant financial burden.

### Prognosis and follow-up

The prognosis is poorer in children than in adults. Children mostly have high-grade gliomas while adults have low-grade disease. The mean survival of diffuse

intrinsic low-grade gliomas ranges between 4.9 to 7.3 years, and they are slow and progressive. High-grade gliomas, especially the diffuse intrinsic forms, have an extremely dismal prognosis and have an average lifespan of under 2 years. Following ventriculoperitoneal shunting and, in some cases, focussed radiation, focal tectal gliomas have been linked to extended overall life (over 10 years). Other brainstem gliomas also have good outcomes. DMGs of the thalamus and spine have a much better prognosis with longer survival than pontine gliomas.<sup>23</sup>

In addition to the tumour's prognosis, the lack of a clear treatment protocol, limited funding, delayed referrals, financial constraints, and poor accessibility to healthcare in low- and middle-income countries further contribute to overall worse outcomes than in developed nations.<sup>31</sup> Unfortunately, these delayed diagnoses and referrals have a major negative impact on immediate post-operative outcomes. Progress has been made to reduce surgical morbidity with neuro-navigation and stereotactic biopsy techniques. An appraisal of local and patient-specific financial constraints is needed before recommending treatment protocols, considering the need for further follow-ups, investigations, and supportive care.<sup>32</sup>

Regular follow-ups in 3-6 months shall be done for observation, and to look for the development of any post-op neurological deficits. Follow-up with a repeat MRI brain with contrast must be done in case of the development of new neurological symptoms.<sup>16, 27</sup>

Patients with neurological morbidity significantly benefit from rehabilitation care which is significantly lacking in many LMICs. Postoperative cranial nerve dysfunction, ataxia, incoordination, and other neurological deficits limit patients' functionality. For these patients, motor learning through repetitive practice of focussed tasks is a beneficial strategy for promoting plasticity and obtaining optimal performance.<sup>33</sup>

### Gaps in knowledge

Surgical management has significantly improved with stereotactic access to the midbrain for decreased morbidity for biopsy. The utility of diffusion tensor imaging (DTI) for white matter tracts is still debatable within the midbrain and requires greater analysis of complex connections within the region.<sup>34</sup> Mutational analysis of the H3 histone gene provides greater insight into biological and morphological differentiation of paediatric brainstem gliomas from classical adult glioma. Global hypomethylation of H3K27 is posited to be a significant epigenetic driver for DIPG gliomagenesis. H3.3

and H3.1 variants of this gene may be oncogenic drivers for brainstem gliomas, however, the origins are still unknown. Other somatic mutations such as ACVR1, PDGFRA, ATRX, and TP53 are being studied to look for any role in their development and proliferation.<sup>35</sup> Potential therapies to restore baseline levels of methylation of H3K27 may be a solution; the demethylase inhibitor GSKJ1 has been shown to increase cancer cell apoptosis in pre-clinical models. Similarly, immune checkpoint inhibition is being investigated as a solution. Anti-PD1 drugs have yet to show a significant benefit in retrospective analysis with ongoing clinical trials for anti-PD1 monoclonal antibodies.<sup>36</sup> Pre-clinical and efficacy trials are also looking into CAR-T cell therapy for brainstem gliomas.<sup>37</sup>

Despite significant strides in treatment opportunities for brainstem gliomas in high-income countries (HICs), these benefits will not easily translate to countries with limited resources for neuro-oncology services. Greater uptake of newer therapies may lead to price reduction and cost-effective solutions, however, it is difficult to ascertain future impact at this time.

### Conclusion

These guidelines serve as a practical roadmap based on valuable experience (Table 2 and Figure 1) and are designed for physicians working in resource-limited settings. Their implementation has significant potential to improve focused outcomes and aims to nurture a stronger emphasis on multidisciplinary care within LMICs, such as Pakistan.

**Disclaimer:** None.

**Conflict of Interest:** None.

**Funding Disclosure:** None.

### References

1. Yoon HI, Wee CW, Kim YZ, Seo Y, Im JH, Dho YS, et al. The Korean Society for Neuro-Oncology (KSNO) Guideline for Adult Diffuse Midline Glioma: Version 2021.1. *Brain Tumor Res Treat* 2021;9:1-8. doi: 10.14791/btrt.2021.9.e8.
2. Cooney TM, Lubanszky E, Prasad R, Hawkins C, Mueller S. Diffuse midline glioma: review of epigenetics. *J Neurooncol* 2020;150:27-34. doi: 10.1007/s11060-020-03553-1.
3. Leibetseder A, Leitner J, Mair MJ, Meckel S, Hainfellner JA, Aichholzer M, et al. Prognostic factors in adult brainstem glioma: a tertiary care center analysis and review of the literature. *J Neurol* 2022;269:1574-90. doi: 10.1007/s00415-021-10725-0.
4. Khalid SI, Kelly R, Adogwa O, Carlton A, Tam E, Naqvi S, et al. Pediatric Brainstem Gliomas: A Retrospective Study of 180 Patients from the SEER Database. *Pediatr Neurosurg* 2019;54:151-64. doi: 10.1159/000497440.
5. Faulkner H, Arnaout O, Hoshide R, Young IM, Yeung JT, Sughrue ME, et al. The Surgical Resection of Brainstem Glioma: Outcomes and Prognostic Factors. *World Neurosurg* 2021;146:e639-50. doi: 10.1016/j.wneu.2020.10.147.

6. Bajwa MH, Shah MM, Mustansir F, Gauhar F, Baig E, Zafar SN, et al. A Guideline On Guidelines – Neuro-Oncology Guideline Standards For Low And Middle-Income Countries. *J Pak Med Assoc* 2024;74(Suppl 3):s87-92. Doi: 10.47391/JPMA.S3.GNO-10.
7. Hargrave D, Bartels U, Bouffet E. Diffuse brainstem glioma in children: critical review of clinical trials. *Lancet Oncol* 2006;7:241-8. doi: 10.1016/S1470-2045(06)70615-5.
8. Ostrom QT, Cioffi G, Gittleman H, Patil N, Waite K, Kruchko C, et al. CBTRUS Statistical Report: Primary Brain and Other Central Nervous System Tumors Diagnosed in the United States in 2012-2016. *Neuro Oncol* 2019;21:v1-100. doi: 10.1093/neuonc/noz150.
9. Yin L, Zhang L. Correlation between MRI findings and histological diagnosis of brainstem glioma. *Can J Neurol Sci* 2013;40:348-54. doi: 10.1017/s0317167100014293.
10. Bin-Alamer O, Jimenez AE, Azad TD, Bettogowda C, Mukherjee D. H3K27M-Altered Diffuse Midline Gliomas Among Adult Patients: A Systematic Review of Clinical Features and Survival Analysis. *World Neurosurg* 2022;165:e251-64. doi: 10.1016/j.wneu.2022.06.020.
11. Weller M, van den Bent M, Preusser M, Le Rhun E, Tonn JC, Minniti G, et al. EANO guidelines on the diagnosis and treatment of diffuse gliomas of adulthood. *Nat Rev Clin Oncol* 2021;18:170-86. doi: 10.1038/s41571-020-00447-z.
12. Ramos A, Hilario A, Lagares A, Salvador E, Perez-Nuñez A, Sepulveda J. Brainstem gliomas. *Semin Ultrasound CT MR* 2013;34:104-12. doi: 10.1053/j.sult.2013.01.001.
13. Mauffrey C. Paediatric brainstem gliomas: prognostic factors and management. *J Clin Neurosci* 2006;13:431-7. doi: 10.1016/j.jocn.2005.05.015.
14. Broniszer A, Laningham FH, Kocak M, Krasin MJ, Fouladi M, Merchant TE, et al. Intratumoral hemorrhage among children with newly diagnosed, diffuse brainstem glioma. *Cancer* 2006;106:1364-71. doi: 10.1002/cncr.21749.
15. Wang Y, Feng LL, Ji PG, Liu JH, Guo SC, Zhai YL, et al. Clinical Features and Molecular Markers on Diffuse Midline Gliomas With H3K27M Mutations: A 43 Cases Retrospective Cohort Study. *Front Oncol* 2021;10:602553. doi: 10.3389/fonc.2020.602553.
16. Jallo GI, Biser-Rohrbaugh A, Freed D. Brainstem gliomas. *Childs Nerv Syst* 2004;20:143-5. doi: 10.1007/s00381-003-0870-6.
17. Abdullah UE, Laghari AA, Khalid MU, Rashid HB, Jabbar AA, Mubarak F, et al. Current management of glioma in Pakistan. *Glioma* 2019;2:139-44. DOI: 10.4103/glioma.glioma\_15\_19.
18. Orduña PC, P Lubaton-Sacro CA. Factors associated with delayed diagnosis among Filipino pediatric brain tumor patients: a retrospective review. *CNS Oncol* 2022;11:CNS89. doi: 10.2217/cns-2022-0009.
19. Grimm SA, Chamberlain MC. Brainstem glioma: a review. *Curr Neurol Neurosci Rep* 2013;13:346. doi: 10.1007/s11910-013-0346-3.
20. Bilaniuk LT, Zimmerman RA, Littman P, Gallo E, Rorke LB, Bruce DA, et al. Computed tomography of brain stem gliomas in children. *Radiology* 1980;134:89-95. doi: 10.1148/radiology.134.1.7350640.
21. Walker DA, Punt JA, Sokal M. Clinical management of brain stem glioma. *Arch Dis Child* 1999;80:558-64. doi: 10.1136/adc.80.6.558.
22. Dorfer C, Czech T, Gojo J, Hosmann A, Peyrl A, Azizi AA, et al. Infiltrative gliomas of the thalamus in children: the role of surgery in the era of H3 K27M mutant midline gliomas. *Acta Neurochir (Wien)* 2021;163:2025-3. doi: 10.1007/s00701-020-04589-y.
23. Yi S, Choi S, Shin DA, Kim DS, Choi J, Ha Y, et al. Impact of H3.3 K27M Mutation on Prognosis and Survival of Grade IV Spinal Cord Glioma on the Basis of New 2016 World Health Organization Classification of the Central Nervous System. *Neurosurgery* 2019;84:1072-81. doi: 10.1093/neuros/nyy150.
24. Bankole NDA, Dokponou YCH, Sayore MC, Boutarbouch M, Rifi L, El Ouahabi A. Childhood brainstem gliomas: A non-aggressive management. *Interdiscip Neurosurg* 2022;28:e 101488.
25. Guillamo JS, Doz F, Delattre JY. Brain stem gliomas. *Curr Opin Neurol* 2001;14:711-5. doi: 10.1097/00019052-200112000-00006.
26. Zhang L, Pan CC, Li D. The historical change of brainstem glioma diagnosis and treatment: from imaging to molecular pathology and then molecular imaging. *Chin Neurosurg J* 2015;1:e3.
27. Reyes-Botero G, Mokhtari K, Martin-Duverneuil N, Delattre JY, Laigle-Donadey F. Adult brainstem gliomas. *Oncologist* 2012;17:388-97. doi: 10.1634/theoncologist.2011-0335.
28. Qureshi BM, Mansha MA, Karim MU, Hafiz A, Ali N, Mirkhan B, et al. Impact of Peer Review in the Radiation Treatment Planning Process: Experience of a Tertiary Care University Hospital in Pakistan. *J Glob Oncol* 2019;5:1-7. doi: 10.1200/JGO.19.00039.
29. Gallitto M, Lazarev S, Wasserman I, Stafford JM, Wolden SL, Terezakis SA, et al. Role of Radiation Therapy in the Management of Diffuse Intrinsic Pontine Glioma: A Systematic Review. *Adv Radiat Oncol* 2019;4:520-31. doi: 10.1016/j.adro.2019.03.009.
30. Gagliardi F, De Domenico P, Snider S, Pompeo E, Roncelli F, Barzaghi LR, et al. Gamma Knife radiosurgery as primary treatment of low-grade brainstem gliomas: A systematic review and meta-analysis of current evidence and predictive factors. *Crit Rev Oncol Hematol* 2021;168:103508.
31. Seah T, Zhang C, Halbert J, Prabha S, Gupta S. The magnitude and predictors of therapy abandonment in pediatric central nervous system tumors in low- and middle-income countries: Systematic review and meta-analysis. *Pediatr Blood Cancer* 2019;66:e27692. doi: 10.1002/pbc.27692.
32. Baquero-Herrera PE, Ardila-Martínez MA, Abdalá-Vargas NJ, Racedo J, Ordóñez-Rubiano EG. Treatment Limitations for Pediatric Diffuse Intrinsic Pontine Gliomas in a Middle-Income Country. *J Neurosci Rural Pract* 2022;13:515-20. doi: 10.1055/s-0042-1745714.
33. Lee YS, Oh DW. One-year follow-up of problem-based task training for a child presenting cerebellar ataxia after brainstem glioma surgery: A single-subject experimental study. *Physiother Res Int* 2021;26:e1908. doi: 10.1002/pri.1908.
34. Low SYY, Soh SY, Chen MW, Ng LP, Low DCY, Seow WT. DTI fusion with conventional MR imaging in intra-operative MRI suite for paediatric brainstem glioma biopsy. *Childs Nerv Syst* 2018;34:19-21. doi: 10.1007/s00381-017-3627-3.
35. Wummer B, Woodworth D, Flores C. Brain stem gliomas and current landscape. *J Neurooncol* 2021;151:21-8. doi: 10.1007/s11060-020-03655-w.
36. Kline C, Liu SJ, Duriseti S, Banerjee A, Nicolaidis T, Raber S, et al. Reirradiation and PD-1 inhibition with nivolumab for the treatment of recurrent diffuse intrinsic pontine glioma: a single-institution experience. *J Neurooncol* 2018;140:629-38. doi: 10.1007/s11060-018-2991-5.
37. Mount CW, Majzner RG, Sundaresh S, Arnold EP, Kadapakkam M, Haile S, et al. Potent antitumor efficacy of anti-GD2 CAR T cells in H3-K27M+ diffuse midline gliomas. *Nat Med* 2018;24:572-9. doi: 10.1038/s41591-018-0006-x.

---

#### DISCLAIMER

Articles published in JPMA and Supplements of JPMA do not represent the views of the editor or editorial Board. Authors are solely responsible for the opinions expressed and the accuracy of the data.

The contribution of each author towards the published research included in this supplement is the responsibility of the authors and their institutions. It is expected to be in accordance and compliance with the ICMJE Guidelines.

Any questions/queries raised by readers should be directed to the corresponding author.

## NARRATIVE REVIEW

## Consensus guidelines for the management of primary central nervous system lymphoma for low and middle-income countries

Hafiza Fatima Aziz<sup>1</sup>, Saqib Kamran Bakhshi<sup>2</sup>, Noman Ahmed<sup>3</sup>, Mohammad Hamza Bajwa<sup>4</sup>, Adnan Abdul Jabbar<sup>5</sup>, Asim Hafiz<sup>6</sup>, Ahmed Gilani<sup>7</sup>, Muhammad Usman Khalid<sup>8</sup>

**Pakistan Brain Tumour Consortium:** (Authors list at the end of the supplement), Syed Ather Enam.

### Abstract

Primary lymphoma of the central nervous system (PCNSL) is a rare and aggressive form of extranodal non-Hodgkin lymphoma primarily involving the brain, spinal cord, cerebrospinal fluid, and eyes. The role of surgical intervention in PCNSL is currently limited to biopsy and decompression of critical structures if needed – extended resection is debated. Chemotherapy is the mainstay of treatment. In lower and middle-income countries (LMICs), issues like delayed diagnosis and resource constraints are widespread. These guidelines provide a framework for addressing PCNSL in LMICs, emphasizing the importance of early diagnosis, tailored treatment approaches, and ongoing patient monitoring to improve outcomes for this rare and aggressive disease.

**Keywords:** Lymphoma, non-Hodgkin, biopsy, nervous system, physiologic decompression, spinal cord, brain tumours

**DOI:** <https://doi.org/10.47391/JPMA.S3.GNO-20>

### Introduction

Primary lymphoma of the central nervous system (PCNSL) is an aggressive form of extranodal non-Hodgkin lymphoma (NHL) that is primarily limited to the involvement of brain parenchyma, spinal cord, cerebrospinal fluid (CSF), and the eyes. The disease is more commonly seen in individuals who are immunocompromised in comparison to immunocompetent individuals. This is particularly true for individuals with solid organ transplantation and those affected with the Human immunodeficiency virus.

Primary CNS lymphoma is a rare disease with an incidence of 0.4 to 0.5 per 100,000 persons per year, accounting for

.....  
<sup>1-4,8,10</sup>Department of Neurosurgery, The Aga Khan University, Karachi, Pakistan. <sup>5</sup>Department of Oncology, Ziauddin University Hospital, Karachi, Pakistan. <sup>6</sup>Department of Radiation Oncology, The Aga Khan University, Karachi, Pakistan. <sup>7</sup>Department of Pathology, University of Colorado, Children's Hospital Colorado, USA.

**Correspondence:** Syed Ather Enam **Email:** [ather.enam@aku.edu](mailto:ather.enam@aku.edu)

approximately 4 to 5 percent of all primary brain tumors.<sup>1,2</sup> It has a higher incidence in males, with a mean age at diagnosis of 65 years.<sup>3</sup> Rarely individuals with primary CNS involvement can have a systemic relapse that carries a poor prognosis.

Secondary CNS lymphoma is a part of systemic disease, which is more common in relapse cases. The median time from systemic diagnosis to CNS disease is one year, but it can also present within six months.<sup>4</sup> The factors associated with increased risk of CNS involvement include aggressive subtypes of NHL, older age at diagnosis, advanced stage, and involvement of testis, orbit, and paranasal sinuses.<sup>5,6</sup>

### Methodology

The literature search of the high-quality data on lymphomas was done in June 2022 on different databases including PubMed, Google Scholar, Scopus, and Embase. The most relevant and high-quality studies were analyzed to develop the evidence-based recommendations. An expert panel was convened consisting of specialists and leading experts within the field of neuro-oncology to identify the gaps in diagnosis and management of primary CNS lymphoma within Pakistan. Experts from neurosurgery, oncology, neuro-radiology, radiation oncology, and neuro-pathology were tasked with identifying best-practice recommendations and their application within the context of Pakistan as an LMIC. Members of the panel collected and analysed published evidence within their specialties for the management of CNS lymphoma. Often there was consideration given to the availability of infrastructure and resources within the region.

These recommendations were thus collated and discussed among senior members of the panel. They were reviewed and debated regarding utility and evidence-based practices. Recommendations once drafted were once again reviewed by the experts for any disagreements or further required points. Based on this second review process as well as insight from senior panel members, a finalized set of recommendations culminated

in a consensus draft that was then agreed upon by the panel at large. This draft paper was edited for clarity and brevity, for the purposes of dissemination and publication.<sup>7</sup>

## Initial evaluation

### Clinical presentation and evaluation

The clinical presentation of CNS lymphomas is highly variable depending upon the anatomical location of the lesion. The signs and symptoms range from focal neurological deficits (50-70%), altered mentation, behavioural changes (32-43%), and manifestations related to raised intracranial pressure (headache, nausea, vomiting, and papilloedema; 32-33%) and seizures (11-14%).<sup>8</sup> Rare symptomatology includes isolated visual symptoms (4%) ranging from pain, redness, blurry vision, decreased visual acuity, and visual floaters.<sup>9</sup>

Neurolymphomatosis may be seen as the only clinical presentation of lymphoma resulting from infiltration of the peripheral nervous system that manifests differently. This can include plexopathy, mononeuritis multiplex, foot drop, radiculopathy, and cranial nerve palsies. Symptoms of nerve involvement can result in extreme pain not amenable to neuropathic pain medications.<sup>10</sup>

The diagnosis of CNS lymphoma can be delayed in low- and middle-income countries (LMICs) because of delayed health-seeking behaviour combined with a high misdiagnosis rate. This can result in a high disease burden at presentation. According to one study, the median time from the onset of symptoms to diagnosis is reported to be around 3.5 – 5 months in the Indian subcontinent compared to the Western population, which is about 2.5 – 3 months.<sup>11, 12</sup> Individuals in LMIC commonly present with headaches due to raised intracranial pressure as the index presentation compared to focal neurological deficits in the Western population.<sup>13, 14</sup> The Eastern Cooperative Oncology group (ECOG) performance status is  $\geq 3$  in individuals residing in LMIC in comparison to higher-income countries.<sup>15, 16</sup>

### Diagnostic workup

Lymphoma is fundamentally a multisystem disease. A systemic approach is needed to investigate the patient considering a wide array of differentials. Primary CNS lymphoma typically appears as a solitary (60%) parenchymal mass involving the supratentorial compartment with a greater predilection for the periventricular region.<sup>17</sup> It can be multifocal in 20-40 % of cases with up to 8 lesions.<sup>18, 19</sup> Frontal and parietal lobes are involved more commonly in the supratentorial compartment. Lymphomatous lesions involve deep

periventricular structures in the brain, including the corpus callosum and basal ganglia.<sup>20</sup>

MRI with and without contrast is the modality of choice. The lesion appears hypo to isointense on the T1 weighted image while hypointense on T2 and FLAIR sequences. Lymphomas show diffusion restriction owing to high cellular content, appearing hyperintense on diffusion-weighted imaging (DWI) with corresponding low ADC (apparent diffusion coefficient) values. MR spectroscopy shows an elevated choline peak with reduced N-acetyl aspartate (NAA) and Cr levels. Leptomeningeal enhancement can also be present in some cases. There is mild peritumoral oedema compared to gliomas and metastasis.<sup>20</sup> The low cost and wide availability of CT scan make it a valuable alternative to MRI in resource-limited settings in LMICs. On CT, lymphoma characteristically appears hyperdense with homogeneously contrast enhancement.<sup>21</sup>

It's essential to differentiate CNS lymphoma from other pathologies that closely mimic on MRI. Glioblastoma is one of the closest differentials of lymphoma on imaging. High-grade gliomas usually elicit heterogeneous contrast enhancement with central necrosis compared to more homogeneously enhancing lymphomas. Unlike glioblastomas, lymphomas manifest restricted diffusion. Metastasis is also a common differential to lymphoma, usually showing central necrosis, peripheral enhancement, and extensive peritumoral oedema. Other differentials may include tumefactive demyelination and infectious etiologies such as an abscess.<sup>21</sup>

A complete staging workup is required once the diagnosis is confirmed. This includes MRI whole spine with and without contrast, lumbar puncture, systemic imaging with and without bone marrow biopsy, and ophthalmology evaluation. In addition, baseline blood workup should include complete blood count, liver and kidney function tests, serum lactate dehydrogenase (LDH), and HIV and Hepatitis serology.

Lumbar puncture if safe, should be performed for all patients with suspected or confirmed PCNS lymphoma. It is indicated in cases where biopsy isn't available and/or to rule out leptomeningeal involvement.<sup>22</sup> CSF (3-10 ml) should be sent for detailed report (DR) and cytology. Immunohistochemistry analysis of sample tissue is often sufficient and practical for most resource-limited settings, however, if facilities are available beta-2 microglobulin levels, IgH gene rearrangement, and flow cytometry may be considered for CSF analysis. A detailed report reveals elevated white cell count and protein. Glucose is usually

normal.

18 Fluorodeoxyglucose PET scan is recommended to rule out systemic disease; if not available, it can be replaced with CT scan of the neck, chest, abdomen, and pelvis with and without contrast. It is particularly useful in patients with renal dysfunction or contrast allergies. In addition, PET has high sensitivity in detecting systemic lymphoma compared to CT scans.<sup>23</sup> It is also superior to MRI in determining the therapeutic response to chemotherapy. However, its cost and availability limit practicality in LMICs.

For individuals aged over 60 with CNS lymphoma, it is essential to undergo an evaluation to exclude the possibility of a primary testicular neoplasm, which accounts for 15% of cases.<sup>24</sup> A thorough testicular examination, complemented by ultrasound, offers substantial diagnostic advantages, especially since PET scans and CT scans have limited efficacy in detecting testicular diseases.

Ophthalmology evaluation is mandated in all patients suspected of CNS lymphoma, as 5-20 % of these tumours present with intraocular involvement only. Most patients present with floaters and blurry vision with intact visual acuity, unless direct central macular involvement. Approximately 50% of patients are asymptomatic at presentation, underlying the need for examination. A slit lamp examination should be done, followed by fluorescein angiography and colour photography if an abnormality is detected. Confirmatory tests may include flow cytometry of vitreous fluid and tissue biopsy from the vitreous, retina, and choroid tissue. Primary vitreoretinal lymphoma (PVRL) is a subset where lymphoma arises in the eyes first without brain involvement. Though this is initially a limited disease, 60-90% of patients develop CNS relapse.

### **Surgical management**

The role of surgery for Primary CNS lymphoma (PCNSL) is focussed on tissue biopsy for histopathological confirmation before starting chemotherapy. Solitary lesions can be elected for either standard biopsy or stereotactic sampling if such capabilities are available, resulting in lower surgical morbidity and hospital stay. The tissue sample can be obtained via stereotactic biopsy with a greater than 80% diagnostic yield.<sup>25</sup> Surgical biopsy is not indicated when the tumour is located deep within the brain parenchyma or multifocal, as it may increase the morbidity of patients. For multicentric lesions, the most accessible and safest lesion is biopsied, ensuring the adequacy of samples obtained. The intraoperative frozen section may help confirm the preliminary diagnosis; if the

lesion is shown to be glial or metastatic neoplasm, then the procedure may need to be converted to maximum safe resection.

Debulking of the lesion is usually not recommended, due to the disease's excellent response to chemotherapy obviating any need for debulking. However, large lesions compressive adjacent critical structures or resulting in obstructive hydrocephalus would benefit from maximum safe resection. The objective is then to improve the patient's functional status and allow early initiation of chemotherapy. Recent evidence from meta-analysis suggests that overall survival and progression free survival are higher in PCNSL patients who undergo resection compared to biopsy only.<sup>26</sup> However, this remains to be further validated in other trials.

The use of corticosteroids before biopsy should be avoided as it leads to lysis of tumour cells, decreasing the diagnostic yield of biopsy. Non-diagnostic rates range from 37% after a short period of steroid use (less than one week) to 57 % after a long course of steroid (greater than one week). Therefore, steroid use should be discontinued before biopsy in patients with suspected lymphoma.<sup>27, 28</sup> Re-imaging is advised after 2-4 weeks in cases of suspected CNS lymphoma that usually disappears after steroid use.

The rates of complications associated with surgical resection and biopsy are similar. These complications encompass the risks of surgical site infection, bleeding, meningitis, cerebrospinal fluid leakage, intracranial haemorrhage, seizures, focal deficits, brain infarction, as well as systemic complications.<sup>29, 30</sup>

### **Pathological assessment histopathology**

The characteristic histology is a diffuse large B cell lymphoma (DLBCL), which belongs to the family of non-Hodgkin B cell lymphoma, in more than 90 percent of the cases. Uncommon causes include Burkitt lymphoma and low-grade B-cell lymphomas including MALT lymphoma and T-cell lymphoma.<sup>31</sup> Immunodeficiency-associated CNS lymphoma and intravascular large B cell lymphoma are now considered unique types, of CNS lymphoma distinct from primary diffuse, large B, cell lymphoma of the CNS.

Characteristic histological features of primary CNS lymphoma include malignant cells with minimal cytoplasm, angiocentric growth pattern, and frequent mitotic activity. A background of reactive inflammatory cells may also accompany these features. Haematolymphoid nature should be confirmed by



immunohistochemical staining.

The malignant tumour cells show a mature, late germinal-center exit B cells phenotype. The tumour expresses mature B-cell markers including PAX5, CD20, CD19, and CD79a. Immunohistochemical stains such as CD10, Bcl6, and MUM1 are frequently used to sub-classify the tumour into germinal center type and non-germinal center type tumours. CD10 expression is less common (less than 10% of all CNS B cell lymphoma) and should prompt a search for an extracranial source of lymphoma. In cases where diagnostic tumour cells are not seen, the pathologist should elicit the history of steroid use which leads to apoptosis of tumour cells.

### Molecular pathology

Three distinct molecular subgroups of primary CNS lymphoma have been categorised according to gene expression. These different subgroups include germinal center B-cell like, activated B-cell like/non germinal centers, and type 3 subgroups. Most of these tumours have overlapping features of germinal center and activated B cell differentiation subtypes as immunohistochemical analysis has revealed expression of the MUM-1 gene (activated B cell marker) and BCL-6 (a marker of germinal center). The BCR signalling pathway may be affected by recurrent mutations, especially MYD88 and CD79B, that activate nuclear factor  $\kappa$ B (NF- $\kappa$ B). Other alterations may also be seen, including gain at chromosome 9p24.1, which suggests that evasion of immune responses and modulation of pathways contribute to the pathogenesis of CNS lymphomas.<sup>32</sup>

### Chemotherapy

The first-line lymphoma treatment, both primary CNS and systemic, is chemotherapy. However, the chemotherapy regimens for systemic lymphoma differ from primary CNS lymphoma as many of these therapeutic agents do not cross the blood-brain barrier.

A modern treatment approach to primary CNS lymphoma includes two phases: induction and consolidation phase.

### Induction phase

Combination chemotherapy regimens are used during the induction phase. The treatment protocol incorporates high-dose Methotrexate (MTX), which has high initial response rates in combination with other agents.

According to several studies, the dose of MTX employed is between 3 and 8 g/m<sup>2</sup>, although the optimal dose has yet to be established. It's essential to administer MTX as a rapid infusion over 2- hours at a dose of at least 3 g/m<sup>2</sup> to achieve maximum therapeutic concentration in CNS at

intervals of 10-21 days.<sup>33</sup>

The International Extranodal Lymphoma Study Group (IELSG) study has demonstrated the value of combining HD-MTX with other cytotoxic agents. Adding cytarabine in combination with HD-MTX improves complete response rate and progression free survival compared to methotrexate alone. Adding Rituximab to a combination of MTX/cytarabine further improves the response rate.

Within resource-limited centers, the modified DeAngelis Protocol is a viable option, consisting of five to seven cycles of MVP (Methotrexate, Vincristine, and Procarbazine) followed by radiation and consolidation with two cycles of high-dose Cytarabine considering the challenges faced by the high cost of drugs such as rituximab which doesn't impact overall outcome.<sup>34</sup> Repeat hospital admissions for infusions and toxicity management underlie the need for practicable application of such protocols. Specific methotrexate serum levels may not be available in many centres; our institutional experience has been to universally admit patients to the hospital for HD-MTX to maintain adequate hydration and urine alkalinization for timely methotrexate clearance, with renal function monitoring. With timely intervention, HD-MTX can be delivered effectively.<sup>35</sup> Due to the toxicity of HD-MTX, only centres with the capability for monitoring, typically tertiary care centres, should manage these patients.

The poor CNS penetration indicates the use of high-dose MTX in addition to R-CHOP regimen (Rituximab, Cyclophosphamide, Doxorubicin, Vincristine, and Prednisolone) in individuals with secondary CNS involvement.<sup>36</sup>

Elderly and frail patients are less tolerant of the adverse effects of intensive induction chemotherapy regimens. In these individuals, less intensive treatment options can be considered. According to the PRIMAIN protocol for elderly patients, a combination of Methotrexate with Rituximab and Procarbazine can be used for six cycles every 28 days, followed by a maintenance dose of Procarbazine for another six cycles.<sup>37</sup>

Palliative treatment can be considered in patients deemed unfit for methotrexate-based chemotherapy. This includes whole brain radiotherapy and oral chemotherapeutic agents like Temozolomide or corticosteroids. A small retrospective study of single agent temozolomide in elderly patients with comorbidities showed a prolonged response (>12 months), progression free survival of 5 months, and overall survival of 21 months.<sup>38</sup>

Frequently observed adverse effects of Methotrexate-based chemotherapy encompass renal failure, atypical blood cell counts, disruptions in liver function, pneumonitis, mucositis, and leukoencephalopathy. Other serious effects may include the reactivation of latent viruses, particularly hepatitis, and the activation of latent tuberculosis.

### Consolidation phase

Patients responding to initial induction and with non-progressive disease should be considered for consolidation therapy to improve overall outcomes. According to the recommendations, this phase of treatment should be commenced within 6-8 weeks of the first day of the final induction chemotherapy cycle.<sup>39</sup>

High-dose Thiotepa (HDT) based chemotherapy with Autologous Stem Cell Transplantation (ASCT) is considered first-line consolidation therapy. Based on the findings from the International Extra-nodal Lymphoma Study Group 32 (IELSG32), 24 out of 28 patients who initially had a partial response following induction therapy were able to attain a complete response after undergoing HDT-ASCT.<sup>40</sup>

Patients, not eligible for HDT-ASCT and those with residual disease following induction chemotherapy should receive whole brain radiotherapy (WBRT) as part of consolidation treatment.<sup>41</sup> The cost and availability of Thiotepa are concerning in LMICs. As per NCCN guidelines, alternative options may include a high-dose Cytarabine with or without Etoposide or continuing high dose Methotrexate/Rituximab-based regimen for 1 year.

### Radiotherapy

Radiotherapy had previously been the mainstay in treating PCNSL. It is currently used in the consolidative phase of management in combination with the chemotherapeutic agent to maintain remission. Isolated whole brain radiotherapy can achieve rapid remission; however, recurrences are particularly common. The median survival is 12-18 months with radiation alone, but when combined with chemotherapy, the median survival can be increased to 31-90 months.<sup>42,43</sup>

Isolated whole brain radiation therapy can be used in individuals unfit for methotrexate-based regimens, particularly elderly individuals with comorbidities. It is indicated for induction of remission and in the consolidation phase to maintain remission.<sup>44</sup>

Neurotoxicity is a major complication associated with whole brain radiotherapy. Patients may show marked leukoencephalopathy, which leads to cortical and

subcortical atrophy resulting in gait abnormalities, incontinence, and cognitive deficits.<sup>45</sup>

### Disease relapse

Managing patients who experience disease relapse is a daunting task, characterized by a grim prognosis and a median overall survival ranging from 3 to 5 months.<sup>46</sup> It's recommended that all relapses should be discussed in multidisciplinary meetings involving neurosurgeons, neuro-oncologists, and radiation oncologists. Individualised salvage treatment should be considered in cases of relapse and recurrence.

All patients with relapses occurring more than two years after initial diagnosis should undergo repeat biopsy and re-staging to plan further treatment. Intensive treatment options may include high-dose methotrexate when the first remission to HD-MTX is over two years. Other options include Ifosfamide-based immunochemotherapy if there's an early relapse with MTX-based treatment.<sup>47</sup>

Patients ineligible for intensive treatment should be considered for whole brain radiotherapy, corticosteroids, or oral Temozolomide.

A recent systematic review highlighted promising evidence for the use of the irreversible Bruton tyrosine kinase inhibitor, ibrutinib, for the treatment of recurrent/relapsing PCNSL, especially in combination therapy.<sup>48</sup> However further trials are needed to establish its efficacy.

### Follow up

All patients diagnosed with lymphoma of CNS should remain under continuous follow-up as there's a high risk of recurrence. It's observed that recurrences may be seen more than ten years after treatment, and about 6-25 percent of recurrences are asymptomatic.<sup>49</sup> The requirement of complete remission includes the disappearance of contrast-enhancing lesions, the absence of malignant cells in CSF, and the complete disappearance of previous ocular involvement.

All patients should undergo routine clinical examination and imaging at follow-up. The guidelines from the National Comprehensive Cancer Network (NCCN) suggest undergoing brain imaging every three months during the initial two years, followed by imaging every six months for the subsequent three years, and then yearly for the subsequent five years.<sup>50</sup>

Routine evaluation of CSF and spine imaging is not indicated unless an abnormality is suspected. Similarly, patients with intraocular involvement previously should undergo ophthalmologic examination routinely.

**Table-1:** Summary of Recommendations for Primary CNS Lymphoma.

<b>Radiology</b>	<ul style="list-style-type: none"> <li>• MRI brain with and without contrast.</li> <li>• 'Minimum required' MRI protocol:               <ul style="list-style-type: none"> <li>o Imaging on at least 0.5T.</li> <li>o Sequences: Axial T2 and coronal or axial FLAIR sequence; pre-contrast T1 and contrast-enhanced T1.</li> </ul> </li> <li>• Tumour location, tumour margins, enhancement pattern, tumour size and presence of haemorrhage/mineralisation must be included.</li> <li>• Systemic imaging (CT chest, abdomen, and pelvis with contrast) and blood workup to differentiate between primary and secondary disease lymphoma and ophthalmological assessment.</li> </ul>
<b>Neurosurgery</b>	<ul style="list-style-type: none"> <li>• Surgery is usually indicated to obtain tissue for histopathology.</li> </ul>
<b>Neuropathology</b>	<ul style="list-style-type: none"> <li>• Haematoxylin and eosin (H&amp;E) preparation for histological typing.</li> <li>• Intraoperative consultation to rule out gliomas and metastatic tumours is crucial.</li> <li>• Immunohistochemical stain panel including CD20, CD3, CD30, Ki-67 etc, for definite characterisation.</li> </ul>
<b>Medical and Radiation Oncology</b>	<ul style="list-style-type: none"> <li>• Mainstay in the treatment of both primary and secondary CNS lymphoma.</li> <li>• Multiple chemotherapeutic regimens are available depending on patient factors – we recommend a modified DeAngelis protocol with active renal and systemic toxicity monitoring.</li> <li>• Radiotherapy is a part of PCNSL management as an adjunct to chemotherapy according to the modified DeAngelis protocol.</li> <li>• Patients who are not a candidate for chemotherapy radiation therapy can be considered alone.</li> <li>• WBRT with advanced techniques such as 3DCRT/IMRT/VMAT with a conventional fractionation schedule is recommended.</li> <li>• For patients with complete response after chemotherapy WBRT dose should be limited to 23.4 Gy in 13 fractions at 1.8 Gy fraction.</li> <li>• For patients with partial response to chemotherapy or who are not candidates for chemotherapy WBRT dose is 36 Gy in 1.8-2 fraction followed by a boost to gross disease for a total dose of 45 Gy.</li> </ul>
<b>Follow-up</b>	<ul style="list-style-type: none"> <li>• First follow-up at post-op day 10 for wound assessment, stitch removal, discussion related to histopathology and NOTB recommendations.</li> <li>• Serial follow-up with an MRI brain is recommended every three months for the first two years, six monthly imaging for the next three years, and then annually</li> </ul>

Continued on next column...

Continued from previous column...

for five years.

MRI: Magnetic resonance imaging, FLAIR: Fluid-attenuated inversion recovery, CT: Computed tomography, CNS: Central nervous system, PCNSL: Primary central nervous system lymphoma, WBRT: Whole brain radiotherapy, 3DCRT: Three-dimensional conformal radiotherapy, IMRT: Intensity-modulated radiation therapy, VMAT: Volumetric modulated arc therapy, Gy: Gray, NOTB: Neuro-Oncology tumour board.

### Steroids and decision-making

If workup shows a lesion with homogeneous contrast-enhancement, CNS lymphoma should be suspected. Steroids therapy should be deferred initially for surgical biopsy as soon as possible for the patient. After an adequate sample, confirmed on frozen section if available, has been obtained, clinicians can empirically initiate steroids treatment. In some circumstances, patients present to clinics having already started steroids to treat mass-effect symptoms. In such a case, a new MRI scan should be obtained where possible – if involution of the lesion is seen, steroids should be withheld and repeat MRI done after 2-3 weeks, or if symptoms recur.

### Miscellaneous/Prognosis/Quality of life

The overall outcome and prognosis of a patient with CNS lymphoma are highly variable. Age is an independent factor of the prognosis, with the elderly population having poor outcomes, a high risk of early death, and being frequently disabled. In contrast, younger individuals have higher long-term survival and cure rates.<sup>51</sup>

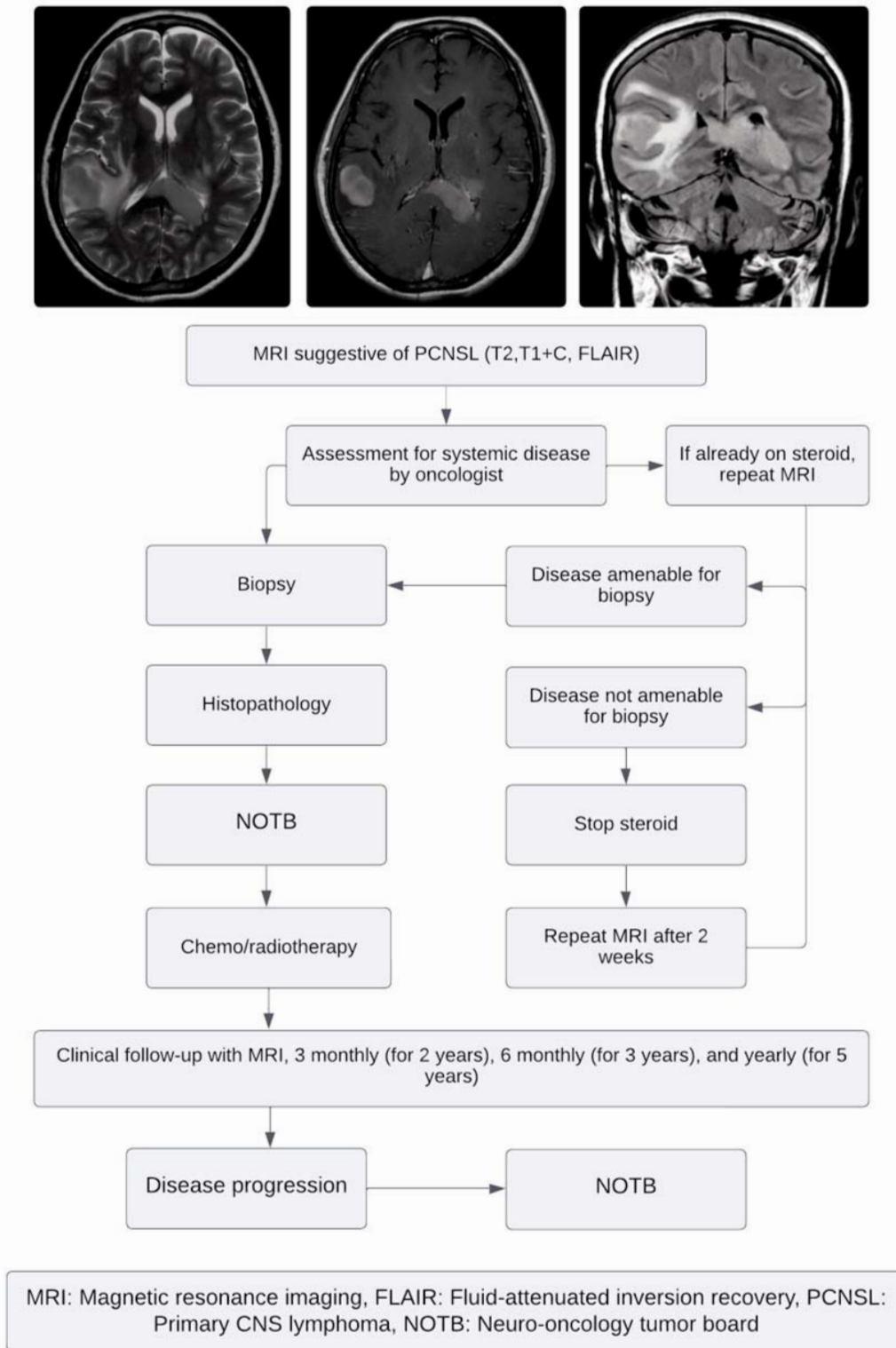
Functional performance status is one of the strongest predictors of survival in PCNSL – Karnofsky Performance Status is a useful determinant of pre-treatment function and survival likelihood.<sup>52</sup>

According to a study, the quality of life was good in about 72% of the patients.<sup>53</sup> However, in some patients, the quality of life had declined, mainly due to loss of social functioning. Most patients suffer from cognitive impairment at presentation. Individuals who experience subnormal performance at long-term follow-up primarily affect attention and executive functions.

Younger patients treated with MTX based systemic polychemotherapy have an acceptable quality of life without significantly deteriorating cognitive deficits.

### Conclusion

These guidelines set a practical framework to support healthcare professionals working in limited resource settings, (see Table 1 and Figure 1). By implementing these guidelines, we can significantly improve outcomes



**Figure-1:** Management of PCNSL algorithm.

while effectively providing multi-disciplinary neuro-oncology care in resource-constrained countries, like Pakistan.

**Disclaimer:** None.

**Conflict of Interest:** None.

**Funding Disclosure:** None.

## References

- Villano JL, Koshy M, Shaikh H, Dolecek TA, McCarthy BJ. Age, gender, and racial differences in incidence and survival in primary CNS lymphoma. *Br J Cancer* 2011;105:1414-8. doi: 10.1038/bjc.2011.357.
- Mendez JS, Ostrom QT, Gittleman H, Kruchko C, DeAngelis LM, Barnholtz-Sloan JS, et al. The elderly left behind-changes in survival trends of primary central nervous system lymphoma over the past 4 decades. *Neuro Oncol* 2018;20:687-94. doi: 10.1093/neuonc/nox187.
- O'Neill BP, Decker PA, Tieu C, Cerhan JR. The changing incidence of primary central nervous system lymphoma is driven primarily by the changing incidence in young and middle-aged men and differs from time trends in systemic diffuse large B-cell non-Hodgkin's lymphoma. *Am J Hematol* 2013;88:997-100. doi: 10.1002/ajh.23551.
- Bernstein SH, Unger JM, Leblanc M, Friedberg J, Miller TP, Fisher RI. Natural history of CNS relapse in patients with aggressive non-Hodgkin's lymphoma: a 20-year follow-up analysis of SWOG 8516 -- the Southwest Oncology Group. *J Clin Oncol* 2009;27:114-9. doi: 10.1200/JCO.2008.16.8021.
- Hollender A, Kvaloy S, Nome O, Skovlund E, Lote K, Holte H. Central nervous system involvement following diagnosis of non-Hodgkin's lymphoma: a risk model. *Ann Oncol* 2002;13:1099-107. doi: 10.1093/annonc/mdf175.
- van Besien K, Ha CS, Murphy S, McLaughlin P, Rodriguez A, Amin K, et al. Risk factors, treatment, and outcome of central nervous system recurrence in adults with intermediate-grade and immunoblastic lymphoma. *Blood* 1998;91:1178-84.
- Bajwa MH, Shah MM, Mustansir F, Gauhar F, Baig E, Zafar SN, et al. A Guideline On Guidelines – Neuro-Oncology Guideline Standards For Low And Middle-Income Countries. *J Pak Med Assoc* 2024;74(Suppl 3):s87-92. Doi: 10.47391/JPMA.S3.GNO-10.
- Bataille B, Delwail V, Menet E, Vandermarcq P, Ingrand P, Wager M, et al. Primary intracerebral malignant lymphoma: report of 248 cases. *J Neurosurg* 2000;92:261-6. doi: 10.3171/jns.2000.92.2.0261.
- Hong JT, Chae JB, Lee JY, Kim JG, Yoon YH. Ocular involvement in patients with primary CNS lymphoma. *J Neurooncol* 2011;102:139-45. doi: 10.1007/s11060-010-0303-9.
- Grisariu S, Avni B, Batchelor TT, van den Bent MJ, Bokstein F, Schiff D, et al. Neurolymphomatosis: an International Primary CNS Lymphoma Collaborative Group report. *Blood* 2010;115:5005-11. doi: 10.1182/blood-2009-12-258210.
- van der Meulen M, Dirven L, Habets EJJ, van den Bent MJ, Taphoorn MJB, Bromberg JEC. Cognitive functioning and health-related quality of life in patients with newly diagnosed primary CNS lymphoma: a systematic review. *Lancet Oncol* 2018;19:e407-18. doi: 10.1016/S1470-2045(18)30356-5.
- Haldorsen IS, Espeland A, Larsen JL, Mella O. Diagnostic delay in primary central nervous system lymphoma. *Acta Oncol* 2005;44:728-34. doi: 10.1080/02841860500256272.
- Patekar M, Adhikari N, Biswas A, Raina V, Kumar L, Mohanti BK, et al. Primary CNS Lymphoma in India: A 17-Year Experience From the All India Institute of Medical Sciences. *J Glob Oncol* 2019;5:1-9. doi: 10.1200/JGO.18.00124.
- Tun HW, Personett D, Baskerville KA, Menke DM, Jaeckle KA, Kreinest P, et al. Pathway analysis of primary central nervous system lymphoma. *Blood* 2008;111:3200-1. doi: 10.1182/blood-2007-10-119099.
- Bataille B, Delwail V, Menet E, Vandermarcq P, Ingrand P, Wager M, et al. Primary intracerebral malignant lymphoma: report of 248 cases. *J Neurosurg* 2000;92:261-6. doi: 10.3171/jns.2000.92.2.0261.
- Mahadevan A, Rao CR, Shanmugham M, Shankar SK. Primary central nervous system diffuse large B-cell lymphoma in the immunocompetent: Immunophenotypic subtypes and Epstein-Barr virus association. *J Neurosci Rural Pract* 2015;6:8-1. doi: 10.4103/0976-3147.143171.
- Zucca E, Conconi A, Mughal TI, Sarris AH, Seymour JF, Vitolo U, et al. Patterns of outcome and prognostic factors in primary large-cell lymphoma of the testis in a survey by the International Extranodal Lymphoma Study Group. *J Clin Oncol* 2003;21:20-7. doi: 10.1200/JCO.2003.11.141.
- Mohile NA, Abrey LE. Primary central nervous system lymphoma. *Neurol Clin* 2007;25:1193-207. doi: 10.1016/j.ncl.2007.07.001.
- Coulon A, Lafitte F, Hoang-Xuan K, Martin-Duverneuil N, Mokhtari K, Blustajn J, et al. Radiographic findings in 37 cases of primary CNS lymphoma in immunocompetent patients. *Eur Radiol* 2002;12:329-40. doi: 10.1007/s003300101037.
- Mansour A, Qandeel M, Abdel-Razeq H, Abu Ali HA. MR imaging features of intracranial primary CNS lymphoma in immune competent patients. *Cancer Imaging* 2014;14:22. doi: 10.1186/1470-7330-14-22.
- Joshi A, Deshpande S, Bayaskar M. Primary CNS lymphoma in Immunocompetent patients: Appearances on Conventional and Advanced Imaging with Review of literature. *J Radiol Case Rep* 2022;16:1-17. doi: 10.3941/jrcr.v16i7.4562.
- Schroers R, Baraniskin A, Heute C, Vorgerd M, Brunn A, Kuhnhen J, et al. Diagnosis of leptomeningeal disease in diffuse large B-cell lymphomas of the central nervous system by flow cytometry and cytopathology. *Eur J Haematol* 2010;85:520-8. doi: 10.1111/j.1600-0609.2010.01516.x.
- Fox CP, Phillips EH, Smith J, Linton K, Gallop-Evans E, Hemmaway C, et al. Guidelines for the diagnosis and management of primary central nervous system diffuse large B-cell lymphoma. *Br J Haematol* 2019;184:348-63. doi: 10.1111/bjh.15661.
- Zucca E, Conconi A, Mughal TI, Sarris AH, Seymour JF, Vitolo U, et al. Patterns of outcome and prognostic factors in primary large-cell lymphoma of the testis in a survey by the International Extranodal Lymphoma Study Group. *J Clin Oncol* 2003;21:20-7. doi: 10.1200/JCO.2003.11.141.
- von Baumgarten L, Illerhaus G, Korfel A, Schlegel U, Deckert M, Dreyling M. The Diagnosis and Treatment of Primary CNS Lymphoma. *Dtsch Arztebl Int* 2018;115:419-26. doi: 10.3238/arztebl.2018.0419.
- Chojak R, Koźba-Gosztyła M, Polańska K, Rojek M, Chojko A, Bogacz R, et al. Surgical resection versus biopsy in the treatment of primary central nervous system lymphoma: a systematic review and meta-analysis. *J Neurooncol* 2022;160:753-61. doi: 10.1007/s11060-022-04200-7.
- Gametchu B. Glucocorticoid receptor-like antigen in lymphoma cell membranes: correlation to cell lysis. *Science* 1987;236:456-61. doi: 10.1126/science.3563523.
- Weller M. Glucocorticoid treatment of primary CNS lymphoma. *J Neurooncol* 1999;43:237-9. doi: 10.1023/a:1006254518848.
- Schellekes N, Barbotti A, Abramov Y, Sitt R, Di Meo F, Ram Z, et al. Resection of primary central nervous system lymphoma: impact of patient selection on overall survival. *J Neurosurg* 2021;135:1016-25. doi: 10.3171/2020.9.JNS201980.

30. Wu S, Wang J, Liu W, Hu F, Zhao K, Jiang W, et al. The role of surgical resection in primary central nervous system lymphoma: a single-center retrospective analysis of 70 patients. *BMC Neurol* 2021;21:190. doi: 10.1186/s12883-021-02227-3.
31. Camilleri-Broët S, Martin A, Moreau A, Angonin R, Hénin D, Gontier MF, et al. Primary central nervous system lymphomas in 72 immunocompetent patients: pathologic findings and clinical correlations. *Groupe Ouest Est d'étude des Leucémies et Autres Maladies du Sang (GOELAMS)*. *Am J Clin Pathol* 1998;110:607-12. doi: 10.1093/ajcp/110.5.607.
32. Chapuy B, Roemer MG, Stewart C, Tan Y, Abo RP, Zhang L, et al. Targetable genetic features of primary testicular and primary central nervous system lymphomas. *Blood* 2016;127:869-81. doi: 10.1182/blood-2015-10-673236.
33. Fox CP, Phillips EH, Smith J, Linton K, Gallop-Evans E, Hemmaway C, et al. Guidelines for the diagnosis and management of primary central nervous system diffuse large B-cell lymphoma. *Br J Haematol* 2019;184:348-63. doi: 10.1111/bjh.15661.
34. Houillier C, Soussain C, Ghesquières H, Soubeyran P, Chinot O, Taillandier L, et al. Management and outcome of primary CNS lymphoma in the modern era: An LOC network study. *Neurology* 2020;94:e1027-39. doi: 10.1212/WNL.0000000000008900.
35. Shahzadi M, Ahmed D, Sawani S, Moosajee M. Outcome of Primary CNS Lymphoma; A Retrospective Analysis. *Asian Pac J Cancer Care* 2022;7:41-6. DOI 10.31557/apjcc.2022.7.1.41-46.
36. Kim SJ, Oh SY, Kim JS, Kim H, Lee GW, Won JH, et al. Secondary central nervous system (CNS) involvement in patients with diffuse large B-cell lymphoma: a therapeutic dilemma. *Ann Hematol* 2011;90:539-46. doi: 10.1007/s00277-010-1104-0.
37. Fritsch K, Kasenda B, Schorb E, Hau P, Bloehdorn J, Möhle R, et al. High-dose methotrexate-based immuno-chemotherapy for elderly primary CNS lymphoma patients (PRIMAIN study). *Leukemia* 2017;31:846-52. doi: 10.1038/leu.2016.334.
38. Kurzweily D, Glas M, Roth P, Weimann E, Lohner H, Waha A, et al. Primary CNS lymphoma in the elderly: temozolomide therapy and MGMT status. *J Neurooncol* 2010;97:389-92. doi: 10.1007/s11060-009-0032-0.
39. Ferreri AJM, Cwynarski K, Pulczynski E, Fox CP, Schorb E, La Rosée P, et al. Whole-brain radiotherapy or autologous stem-cell transplantation as consolidation strategies after high-dose methotrexate-based chemoimmunotherapy in patients with primary CNS lymphoma: results of the second randomisation of the International Extranodal Lymphoma Study Group-32 phase 2 trial. *Lancet Haematol* 2017;4:e510-23. doi: 10.1016/S2352-3026(17)30174-6.
40. Nelson DF. Radiotherapy in the treatment of primary central nervous system lymphoma (PCNSL). *J Neurooncol* 1999;43:241-7. doi: 10.1023/a:1006206602918.
41. Morris PG, Correa DD, Yahalom J, Raizer JJ, Schiff D, Grant B, et al. Rituximab, methotrexate, procarbazine, and vincristine followed by consolidation reduced-dose whole-brain radiotherapy and cytarabine in newly diagnosed primary CNS lymphoma: final results and long-term outcome. *J Clin Oncol* 2013;31:3971-9. doi: 10.1200/JCO.2013.50.4910.
42. Abrey LE, Ben-Porat L, Panageas KS, Yahalom J, Berkey B, Curran W, et al. Primary central nervous system lymphoma: the Memorial Sloan-Kettering Cancer Center prognostic model. *J Clin Oncol* 2006;24:5711-5. doi: 10.1200/JCO.2006.08.2941.
43. Bellinzona M, Roser F, Ostertag H, Gaab RM, Saini M. Surgical removal of primary central nervous system lymphomas (PCNSL) presenting as space occupying lesions: a series of 33 cases. *Eur J Surg Oncol* 2005;31:100-5. doi: 10.1016/j.ejso.2004.10.002.
44. Langner-Lemercier S, Houillier C, Soussain C, Ghesquières H, Chinot O, Taillandier L, et al. Primary CNS lymphoma at first relapse/progression: characteristics, management, and outcome of 256 patients from the French LOC network. *Neuro Oncol* 2016;18:1297-303. doi: 10.1093/neuonc/nov033.
45. Nepal G, Khurana M, Bucheli DH, Bhandari S, Joshi U, Bhagat R, et al. Ibrutinib in Refractory or Relapsing Primary Central Nervous System Lymphoma: A Systematic Review. *Neurol Int* 2022;14:99-10. doi: 10.3390/neurolint14010009.
46. Hoang-Xuan K, Bessell E, Bromberg J, Hottinger AF, Preusser M, Rudà R, et al. Diagnosis and treatment of primary CNS lymphoma in immunocompetent patients: guidelines from the European Association for Neuro-Oncology. *Lancet Oncol* 2015;16:e322-3. doi: 10.1016/S1470-2045(15)00076-5.
47. van der Meulen M, Dirven L, Habets EJJ, van den Bent MJ, Taphoorn MJB, Bromberg JEC. Cognitive functioning and health-related quality of life in patients with newly diagnosed primary CNS lymphoma: a systematic review. *Lancet Oncol* 2018;19:e407-18. doi: 10.1016/S1470-2045(18)30356-5.

#### DISCLAIMER

Articles published in JPMA and Supplements of JPMA do not represent the views of the editor or editorial Board. Authors are solely responsible for the opinions expressed and the accuracy of the data.

The contribution of each author towards the published research included in this supplement is the responsibility of the authors and their institutions.

It is expected to be in accordance and compliance with the ICMJE Guidelines.

Any questions/queries raised by readers should be directed to the corresponding author.

## Consensus guidelines for the management of intracranial metastases for low- and middle-income countries

Hafiza Fatima Aziz<sup>1</sup>, Saqib Kamran Bakhshi<sup>2</sup>, Zaniab Javed<sup>3</sup>, Asim Hafiz<sup>4</sup>, Adeeba Zaki<sup>5</sup>, Kaynat Siddiqui<sup>6</sup>, Ahsan Ali Khan<sup>7</sup>, Mohammad Hamza Bajwa<sup>8</sup>,

**Pakistan Brain Tumour Consortium:** (Authors list at the end of the supplement), Syed Ather Enam.

### Abstract

Metastatic tumours are among the most common types of brain tumours. However, in low- and middle-income countries (LMICs), the numbers are considerably lower. This does not necessarily indicate a decreased incidence but rather points to decreased survival rates or limited access to healthcare. The challenge of achieving better outcomes, along with associated costs and resource constraints, often hinders the effective management of brain metastasis. Even in cases where localised disease can potentially be managed to improve survival, these challenges persist. The purpose of these guidelines is to address these challenges and outline a management strategy within the context of LMICs.

**Keywords:** Incidence, survival rate, health care, brain neoplasms, metastases, tumours

**DOI:** <https://doi.org/10.47391/JPMA.S3.GNO-21>

### Introduction

Brain metastases (BM), are the most frequent type of brain tumours, that are found in 10–40% of individuals diagnosed with cancer. Several factors contribute to the increasing incidence, which include the aging population, improved facilities of neuro-imaging, and improved systemic treatment for the underlying disease. BM cause significant morbidity and mortality consequently.<sup>1</sup> Synchronous (diagnosed within 2 months of the primary tumour) or precocious (diagnosed before the primary tumour), brain metastasis constitutes up to 20% of the instances; the rest of the 80% of the cases present with an already known primary tumour.<sup>1</sup> According to data collected from neurosurgeons and published under the the Pakistan Brain Tumour Epidemiology study (PBTES),

.....  
<sup>1-3,6-7,9-10</sup>Department of Neurosurgery, The Aga Khan University, Karachi, Pakistan. <sup>4</sup>Department of Radiation Oncology, The Aga Khan University, Karachi, Pakistan. <sup>5</sup>Department of Oncology, Ziauddin University Hospital, Karachi, Pakistan. <sup>8</sup>The Aga Khan Medical College and University, Karachi, Pakistan

**Correspondence:** Syed Ather Enam **Email:** [ather.enam@aku.edu](mailto:ather.enam@aku.edu)

the incidence of brain metastasis was 3% This incidence is significantly less than rates reported from high-income countries, possibly due to limitations in collecting and reporting epidemiological data by the author. Another probable reason could be that more patients with metastasis are sent for palliative treatment in LMIC due to the high costs of surgical care.<sup>2</sup>

Brain metastasis is typically found at the interface of gray and white matter and the boundaries connecting the major territories of arterial vasculature. Around 80% of BM arise within the hemispheres of the cerebrum, 15% originate within the cerebellum, and 3% are found within the basal ganglia. Some cancers such as uterine cancers, prostate cancers, and primary gastrointestinal tumours may metastasise to the posterior fossa preferentially. Occasionally, these tumours may spread to the pituitary gland, leptomeninges, or choroid plexus. Infrequently, a few malignancies, such as lymphoma, may extend within or along the cerebral vessels.<sup>3</sup>

The majority of BM are solitary lesions (50%), two in 20%, and three in 30% of the cases. Some tumours, such as those of breast, colon, renal cell tumours, and thyroid tumours are typically solitary, whereas tumours like melanomas and lung cancers are usually multiple. Metastases from cancers like renal cell carcinoma, choriocarcinoma, melanoma, lungs, and thyroid classically cause haemorrhage.

### Methodology

The literature search of the high-quality data on brain metastases was done on different databases including PubMed, Google Scholar, Scopus, and Embase in February, 2023. The most relevant and high-quality studies were analyzed to develop the evidence-based recommendations. An expert panel was convened consisting of specialists and leading experts within the field of neuro-oncology to identify the gaps in diagnosis and management of brain metastases within Pakistan. This group was tasked with identifying best-practice recommendations and their application within the context of Pakistan as an LMIC. Recommendations were

collated, reviewed and debated regarding utility and evidence-based practices, in a process that has been previously detailed.<sup>4</sup>

### Initial evaluation

BM are asymptomatic up to 60-75% of the time. Symptoms may include seizure, headache loss of consciousness, papilloedema, or focal neurological deficit; which warrants further evaluation.<sup>5</sup> Screening is not routinely implemented. Patients suffering from advanced melanoma, small-cell lung carcinoma, and NSCLC, are currently recommended for screening brain MRI at diagnosis.<sup>6</sup>

The main factor in assessing the suitability of the treatment and prognosis is the performance status. Karnofsky performance status (KPS) is a part of the recursive partitioning analysis (RPA) classification system refer to table 1 and 2, together with age, status of primary tumour, and extent of disease outside the cranium. Graded prognostic assessment (GPA), a new prognostic index has been reported recently, which gives a score to each patient from 0 to 4 according to the number of metastases. More recently, for an accurate estimate of prognosis, Disease-specific graded prognostic assessment (DS-GPA) may be used.<sup>1</sup> Molecular profiles and tumour biology have also been integrated into the latest versions of the prognostic scoring systems. Changes in Anaplastic Lymphoma Kinase (ALK) and Epidermal growth factor receptor (EGFR) in non-small-cell lung cancer (NSCLC) (Lung-molGPA); estrogen/progesterone and human epidermal growth factor receptor 2 (HER2) status for breast cancer (Breast-GPA); and BRAF status in melanoma (Melanoma-molGPA), have been used more accurately to estimate the outcome of modern BM patient.<sup>7</sup>

### Imaging

Nonenhanced CT (NECT) due to its easy availability, low cost, and well tolerability is the best initial imaging technique for individuals with recent onset neurological impairments since it can diagnose life-threatening emergencies rapidly like significant mass effect, haemorrhage, or hydrocephalus. BM present as single or multiple lesions, with a variable density compared to the brain parenchyma and extensive surrounding vasogenic oedema. Acutely haemorrhagic metastases and melanoma appear hyperdense to brain parenchyma on CT. Iodinated contrast enhancement is needed for identifying metastases on CT. They may exhibit nodular, solid, or ring-like enhancement. If MRI is unavailable or contraindicated, Contrast-enhanced CT (CECT) can be used as a screening tool for metastases. In LMICs where

accessibility and availability are the major limiting factors, CECT is a valuable diagnostic, screening, and surveillance tool.

On MRI images, metastases show isointense- or hypointense signals on T1-weighted images, and hyperintense signals on T2-weighted images, and display intense enhancement. Few metastases, like melanomas, show hyperintense signals on T1 due to melanin that has paramagnetic effects. Haemorrhagic metastases may also show hyperintensity on T1, varying based on the duration of haemorrhage. Usually, Diffusion Weighted Images demonstrate facilitated diffusion (i.e., bright on apparent diffusion coefficient (ADC) map), rather than diffusion restriction. Substantial vasogenic oedema is noted and is not associated with lesion size. Contrast enhancement with gadolinium is needed to identify compact metastases. Unlike cerebral abscesses, BM demonstrates elevated rather than reduced relative cerebral blood volume (rCBV). Furthermore, perfusion MRI helps differentiate lymphomas of CNS from high-grade glioma and metastasis; because compared to these two entities lymphoma demonstrates lower rCBV. One group suggested a minimum ADC threshold of non-enhancing T2-hyperintense lesion of  $1.3 \times 10^{-3} \text{ mm}^2/\text{s}$  to differentiate metastasis from high-grade glioma: Values below this indicate high-grade glioma not metastasis, with a specificity of 79% and a sensitivity of 83%. Although FDG-PET is crucial in staging metastasis in other parts of the body, it is seen to be less sensitive than MRI in the assessment of brain metastases.

Some cancers are associated with the metastases of the dura, including lung, breast, lymphoma, and prostate cancers. Differentiating a meningioma from a metastasis originating from the dura is challenging. Both may appear as hyperdense lesions on non-contrast CT and may show avid enhancement. Any prior history of malignant tumour, the existence of both parenchymal lesions and dural-based lesions, and the emergence of a recent lesion of dura compared to previous imaging can provide useful indications to favour dural metastasis over meningioma.<sup>4</sup>

### Surgical management

Surgery plays an important role in the multidisciplinary management of BM. Surgical resection reduces the need for corticosteroids, and helps in symptomatic improvement and local control of disease, particularly in patients having stable systemic disease. It helps establish a histopathological diagnosis and provides specimens for more extensive molecular and histological characterisation. Even in patients with known metastatic malignancy, an intra-axial mass can be a primary brain



tumour in 11% of cases.<sup>3</sup> Surgical resection is also needed to differentiate true progression from radionecrosis.<sup>8</sup>

Surgery together with radiotherapy is advised as the initial management strategy in patients with single brain metastasis with limited extracranial disease and favourable performance status. It enhances local control and improves survival. Compared to piecemeal resection, gross total tumour removal is recommended to reduce the risk of leptomeningeal disease postoperatively following resection of single brain metastasis. Complete tumour resection or gross total resection (GTR) is preferred over subtotal resection (STR) in recursive partitioning analysis Class I patients to prolong the time to recurrence and improve overall survival.<sup>9</sup> GTR with WBRT compared to STR with WBRT in 157 patients with BM found no statistically significant difference between the local recurrence rates, but overall survival was significantly increased in the GTR group (20.4 months versus 15.1 months). Even though it has less number of patients, this study suggests that total excision of the tumour showing contrast enhancement can prove to be beneficial, regardless of the subsequent adjuvant therapy.<sup>10</sup>

“Microscopic total resection”, excision of the tumour and the infiltration of microscopic tumour cells within a seemingly normal-looking brain parenchyma within a 5 mm area using an ultrasonic aspirator, was evaluated and compared to radiological GTRs. The local control of tumour was better in the microscopic total resection group than the GTR group (The 1- and 2-year respective local recurrence rates were 29.1 & 29.1% in the microscopic total resection group and 58.6 & 63.2% in the gross total resection group).<sup>11</sup> Another step towards improving the degree of resection is by using fluorescent dye 5-aminolevulinic acid (5-ALA).<sup>10</sup>

In the context of multidisciplinary management of brain metastases, palliative surgical interventions can also provide benefits in select cases. Ommaya reservoir insertion and intrathecal/intraventricular delivery of the drug may be beneficial in patients suffering from leptomeningeal metastases or those diagnosed with large cystic growths in the eloquent region of the brain with impaired performance. Other surgical interventions with palliative intent are for patients experiencing acute hydrocephalus due to metastatic spread to the cerebral aqueduct, cerebellum, or brainstem and for those individuals diagnosed with carcinomatous meningitis causing obstruction to CSF absorption. These palliative interventions may improve the consciousness level and neurological condition of patients.<sup>11</sup>

## Pathologic assessment

Histopathological analysis of the tumour is crucial in formulating a treatment plan for patients with BM as different histopathological tumour types offer different chemotherapeutic and radiation-based treatment options. The main etiology of BM is lung cancer (50–60%) in adults, which is followed by breast cancer (15–20%) and melanoma (5–10%) respectively, and rarely gastric and prostate cancer.<sup>11</sup>

## Adjuvant therapy WBRT

In the past, Whole Brain Radiation Therapy (WBRT) was the mainstay for individuals suffering from BM due to its cost-effectiveness, speed, simplicity, and ability to maximise the control of total intracranial disease.<sup>8</sup> However due to recent deep insight into tumour molecular biology resulting in improved survival, the role of WBRT has significantly reduced because of its associated side effects like fatigue, headache, nausea, anorexia, alopecia, xerostomia, and particularly neurocognitive dysfunction. Currently, its role in clinical practice has been limited to patients with numerous brain metastases (> 4 lesions) those with leptomeningeal disease those having large-sized tumours or pathology with diffuse micrometastatic lesions such as small cell lung carcinoma or lymphoma, or those with the site of metastases not treatable with surgical resection or radiosurgery.

There isn't enough evidence to justify any specific dose or fractionation regimen for a patient with brain metastasis. A common dose/fractionation of the WBRT schedule is 30 Gy in 10 fractions however in patients having poor performance status short fractionation e.g., 20 Gy in 5 fractions can be considered without any significant differences in local control or median survival.

To reduce the neurocognitive decline in the patient getting WBRT different strategies have been proposed such as hippocampal sparing WBRT (HA-WBRT) and, the use of memantine alone or in combination with each other to potentially prevent, lessen, or delay the related neurocognitive toxicity.<sup>12</sup>

## Stereotactic radiosurgery

Stereotactic radiosurgery (SRS), pioneered by Lars Leksell in the 1950s,<sup>13</sup> involves the delivery of several radiations directed on a specific target lesion within a stereotactic setting providing treatment accuracy to submillimeters.<sup>3</sup> SRS is given either as one fraction of extremely precise, high-dose treatment (18–24 Gy generally) or as moderate-dose fractions termed as fractionated SRS (FSRS) given in 3 fractions ranging from 24 to 27 Gy, or 30

Gy in 5 fractions.<sup>7</sup> There is no randomised controlled trial that compares clinical outcomes concerning different SRS fractionation regimens. The Radiation Therapy Oncology Group (RTOG-90-05) a dose escalation phase 1 study according to tumour size has set the standard for single-fraction SRS for intact brain lesions.<sup>14</sup>

Stereotactic radiosurgery can be considered as an initial treatment because of its non-invasive nature, reduced out-patient visits, low morbidity, and provision of a high local control rate. SRS can be used alone in individuals with a known history of cancer and presented with a solitary or limited number of brain lesions without WBRT due to its protecting neurocognitive function ability or it can be utilized in adjunct to surgery for better local control particularly when surgery is indicated for tissue diagnosis or relieving mass effect or hydrocephalus.<sup>6</sup>

Large growths (usually those >3 cm in diameter) are usually not suitable for single fraction radiosurgery and should require a short fractionation approach because it increases the peritumoral oedema and risk of Radiation necrosis (RN) that may occur in a minimum of 10% of patients post-treatment who receive SRS, typically between 6 and 18 months. Based on conventional MRI it is often difficult to differentiate recurrent/progressive BM from radiation necrosis because of the resembling appearance of both oedema and contrast enhancement. The standard treatment is surgical resection for the diagnosis of the lesion which is not always desirable or feasible and may show a mixture of tumour and radiation necrosis. A lot of recent studies have explored the potential of different noninvasive neuroimaging techniques to help differentiate between tumour recurrence from radiation necrosis. These noninvasive neuroimaging modalities include dual-phase PET and MR perfusion. While adjunctive information can be provided by these two tests, no modality has shown adequate specificity and sensitivity to effectively distinguish between these 2 phenomena noninvasively, as recognized in the recently published Response Assessment in Neuro-Oncology–Brain Metastases (RANO-BM) guidelines.<sup>6</sup>

### Chemotherapy/ immunotherapy

Systemic treatment of brain metastasis depends upon primary malignancy. Previously, conventional platinum-based chemotherapy regimens had a role in brain metastases from NSCLC, in the upfront setting particularly. Cisplatin alone has a positive response of 30%, with response rates ranging from 28% to 45% when combined with 1st, 2nd, and 3rd generation EGFR TKI seto-positve, teniposide, fotemustine, paclitaxel, and

vinorelbine/gemcitabine (carboplatin instead of cisplatin). With the advancement in treatment, various targetted therapies enter brain tumours and can target specific genetic alterations in cancer that reach the brain metastatic disease that began elsewhere.

- For metastatic non-small cell lung cancer (NSCLC) with a genetic change in the EGFR gene, osimertinib can be used.
- Alectinib, brigatinib, or ceritinib for metastatic NSCLC that has a genetic change on the ALK gene
- For HER2-positive metastatic breast cancer, tucatinib, trastuzumab, and capecitabine can be used
- For metastatic melanoma, dabrafenib with trametinib can be used.

### Immunotherapy

Certain immunotherapy types have shown promising results in managing BM from melanoma and lung cancer which include ipilimumab (Yervoy), pembrolizumab (Keytruda), and nivolumab (Opdivo).

In a heavily pretreated setting, temozolomide has shown modest activity. Bevacizumab (vascular endothelial growth factor inhibitor) has proved to be safe and has some role in treating non-haemorrhagic brain metastases from NSCLC.<sup>8</sup> Pembrolizumab and nivolumab (Anti-PD1 agents) especially in PD-L1 positive individuals or those who have other immunogenicity biomarkers, or anti-folate chemotherapeutic agent, pemetrexed in individuals suffering from adenocarcinomas may help in managing intracranial disease in certain patients, although outcomes may be limited.<sup>7</sup>

For breast cancer, cytotoxic regimens have a role. Rosner et al in their study reported a 52% response rate in individuals managed with prednisone (P), cyclophosphamide (C), and fluorouracil (F) and a 54% of response rate in those treated with CFP-methotrexate.<sup>14</sup> Similarly, another study reported the efficacy of high-dose metho-trexate in parenchymal or leptomeningeal metastases, which should be investigated further.<sup>14</sup> Bevacizumab's role is currently under investigation. In a case series involving 4 patients suffering from CNS metastases from breast cancer, all patients responded to bevacizumab and paclitaxel. Many reports describe the response to Intrathecal trastuzumab, which is a humanized monoclonal antibody against HER2, in LM from HER2-positive "breast cancer."<sup>17</sup>

In Melanoma BM, the response has been seen with BRAF inhibitor dabrafenib, vemurafenib, and Ipilimumab, an

**Table 1 – Components of recursive partitioning analysis (RPA) classification use to determine prognosis in cerebral metastasis<sup>16</sup>.**

Class	Clinical parameters	Median overall survival (OS) (months)
I	<65 years; Karnofsky performance status (KPS) $\geq$ 70; controlled primary; no extracranial spread	7.1
II	$\geq$ 65 years; KPS $\geq$ 70; uncontrolled primary; extracranial spread	4.2
III	KPS < 70	2.3

**Table-2:** Eastern Cooperative Oncology Group Score.**ECOG/WHO score**

- 0 Fully active, able to carry on all predisease performance without restriction
- 1 Restricted in physically strenuous activity, but ambulatory and able to carry out work of a light and sedentary nature (e.g. light house work, office work)
- 2 Ambulatory and capable of all self-care but unable to carry out any work activities. Up and about more than 50% of waking hours.
- 3 Capable of only limited self-care, confined to bed or chair more than 50% of waking hours
- 4 Completely disabled. Cannot carry on any self-care. Totally confined to bed or chair.
- 5 Dead

anti-CTLA4 monoclonal antibody.<sup>8</sup>

Routine use of chemotherapy alone or after WBRT or SRS for brain metastases is not advised.<sup>18</sup>

**Single brain metastasis**

In individuals with solitary BM with favourable performance status and controlled extracranial disease, WBRT after surgery is advised as the first-line treatment option to extend the overall survival and local control based on randomised trials.<sup>9</sup> Patchell et al. carried out a randomised controlled trial under which 48 patients diagnosed with a solitary BM were randomised to undergo WBRT with or without an initial attempt at complete tumour resection. The addition of surgical removal showed benefits in the duration of functional independence (median duration, 38 vs. 8 weeks;  $P < .005$ ) and overall median survival (mean duration, 40 vs. 15 weeks;  $P < .01$ ).<sup>19</sup>

Recently studies have shown similar clinical outcomes with stereotactic radiation therapy alone for small brain lesions without mass effect or even the preferred

approach for deep-seated lesions. In the case of surgical excision of solitary brain lesion, post-operative radiation to the operative bed by stereotactic radiation is the common clinical practice instead of WBRT because of largely spares the grossly uninvolved brain tissue thus improving or preserving neuro-cognitive function. However, it requires close surveillance with an MRI brain every 2-3 months due to the frequent risk of distant brain failure.<sup>9</sup>

The National Comprehensive Cancer Network Clinical Practice Guidelines in Oncology and the American Society for Radiation Oncology, both published their consensus statements supporting the use of SRS alone or after surgical removal of a solitary metastasis, instead of using WBRT, in individuals with a solitary lesion and good control of systemic disease.<sup>20</sup>

**Multiple (2-4) brain metastases**

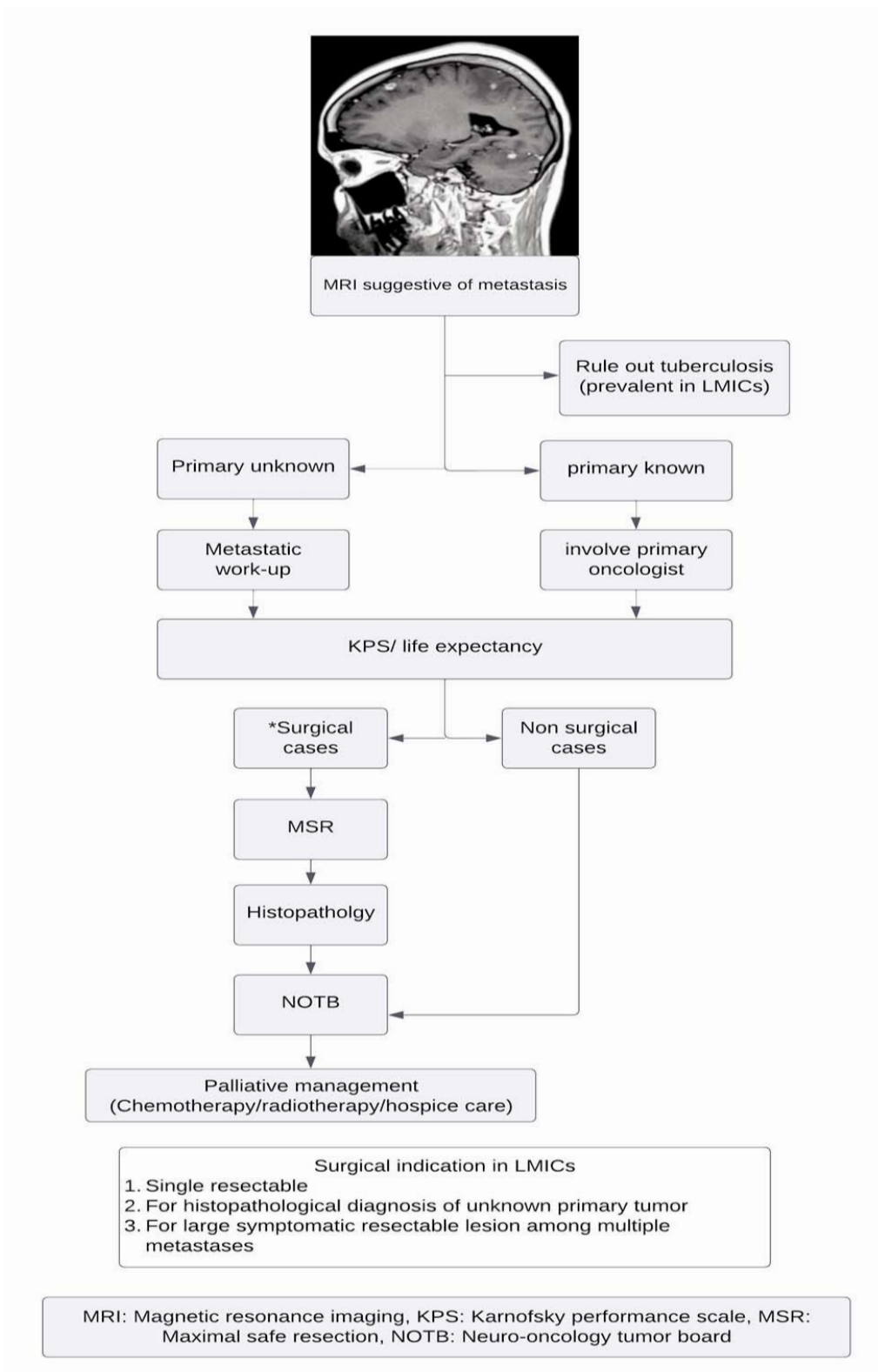
Stereotactic radiation treatment whether single or fractionated is preferred to manage tumours locally, rather than whole brain radiation therapy, when there is a limited number of brain metastasis (<4) with cumulative tumour volume not exceeding 10 CC. However, patients with significant mass effect or hydrocephalus and < 4 lesions brain lesions require surgical excision before proceeding with stereotactic radiation treatment.<sup>20</sup> Collectively, trials demonstrate high rates of local disease control with better preservation of neuro-cognitive function without compromising overall survival by omitting WBRT though with the understanding that higher rates of new distant BM may be observed, necessitating more frequent salvage treatment.<sup>6,22</sup>

**Multiple (> 4) brain metastases**

Whole brain radiation therapy is still considered to be the standard of treatment in the majority of patients with a life expectancy > 3 months based on their performance status and systemic disease. According to recent evidence, SRS may prove to be successful in up to 10 brain metastases; if they are small in size and not exceeding a collective tumour volume of 10-15cc. and favourable tumour velocity. Since there is no consensus about stereotactic RT clinical application in multiple brain metastases (> 4) hence can be considered carefully in highly selected patients after thorough discussion in neuro-oncology MDT.<sup>12</sup>

**Management of recurrent brain metastasis:**

Management of recurrent brain metastasis is highly controversial. Since no consensus guideline is available for guidance hence requires MDT input based upon histopathology, patient performance status, details of



**Figure-1:** Management of Intra cranial Metastases algorithm.

**Table-3:** Summary of recommendations for Metastasis.

<b>Radiology</b>	<ul style="list-style-type: none"> <li>• MRI brain with and without contrast.</li> <li>• 'Minimum required' MRI protocol:               <ul style="list-style-type: none"> <li>o Imaging on at least 0.5T.</li> <li>o Sequences: Axial T2 and coronal or axial FLAIR sequence; pre-contrast T1 and contrast enhanced T1.</li> </ul> </li> <li>• Tumor location, tumour margins, enhancement pattern, tumour size, oedema, number of lesions, volume and presence of haemorrhage/mineralisation must be included.</li> <li>• DWI and ADC: Helpful to rule out differential diagnoses such as abscess, if needed.</li> <li>• CT with contrast (chest, abdomen, and pelvis) with bone scan/ PET Scan: to see the status of the primary lesion.*</li> <li>• Considering the high prevalence of breast cancer, clinical examination of the breast is advised.</li> <li>• Postoperative MRI is recommended within 72 hours of surgery. If delayed, then an MRI should be performed after 6 weeks.               <ul style="list-style-type: none"> <li>o To identify the extent of resection.</li> <li>o To have a baseline to compare successive imaging.</li> <li>o Not required after biopsy.</li> </ul> </li> </ul>
<b>Neurosurgery</b>	<ul style="list-style-type: none"> <li>• GTR: Excision of all contrast-enhancing parts.</li> <li>• STR: In eloquent areas where GTR is not possible.</li> <li>• Biopsy: Extensive disease or locations with high surgical risks.</li> <li>• Palliative surgical interventions: Ventriculoperitoneal shunt or Endoscopic third ventriculostomy, Ommaya reservoir insertion and Intraventricular/Intrathecal delivery of the drug, procedures for patients with CSF obstruction or the ones with metastasis to the mesencephalic aqueduct, cerebellum or brainstem resulting in acute hydrocephalus.</li> </ul>
<b>Neuropathology</b>	<ul style="list-style-type: none"> <li>• Haematoxylin and eosin (H&amp;E) preparation for histological typing.</li> <li>• Intraoperative consultation to rule out gliomas and metastatic tumours is crucial.</li> <li>• Immunohistochemical stain panel including GFAP, Olig-2, pan-cytokeratins and site-specific immunostains are required for definite characterisation.</li> </ul>
<b>Radiation Oncology</b>	<ul style="list-style-type: none"> <li>• Patients suffering from leptomeningeal disease, a high brain metastasis velocity or multiple brain metastases (&gt; 4 lesions), WBRT is considered as a preferred treatment approach.</li> <li>• The common dose fractionation schedule of WBRT is 30 Gy delivered in 10 fractions or 20 Gy in 5 fractions.</li> <li>• Stereotactic radiation is considered a preferred</li> </ul>

Continued on next column...

approach in patients with a limited number of brain metastases < 4 and small volume.

- It can be used as a single fraction SRS or hypofractionated SRS depending upon the size and volume of brain metastasis or resection cavity.
- For SRS common radiation dose is 18–24 Gy. For fractionated SRS 27–30 Gy in 3–5 fractions can be considered.
- Peer review of radiation treatment plans by site-specific specialists is an integral and essential component of quality assurance and should be a part of stereotactic radiation therapy services to improve patient care.

**Medical Oncology** • Tailored approach for each pathology after discussing in NOTB.

**Follow-up** • First follow-up at post-op day 10 for wound assessment, stitch removal, discussion related to histopathology, and NOTB recommendations.

- Clinical follow-up with MRI brain and systemic imaging at 3 monthly intervals or earlier if indicated.

MRI: Magnetic resonance imaging, FLAIR: Fluid-attenuated inversion recovery, DWI: Diffusion-weighted imaging, ADC: Apparent diffusion coefficient, CT: Computed tomography, PET: Positron Emission Tomography, GTR: Gross total resection, STR: Subtotal resection, CSF: Cerebrospinal fluid, GFAP: Glial fibrillary acidic protein, WBRT: Whole brain radiation therapy, Gy: Gray, SRS: Stereotactic radiosurgery, NOTB: Neuro-Oncology tumor board.

\*In case of financial constraints, chest X-ray and ultrasound abdomen can be used as an alternative option to screen before surgery.

previous treatment received, disease-free interval, number of lesions, and possible re-treatment options available such as surgery, chemotherapy, or radiation.<sup>9,23</sup>

### Role of Steroids

Steroids are not indicated for asymptomatic patients without mass effect but are recommended for providing temporary symptomatic relief due to raised intracranial pressure and oedema. For such patients, it is recommended to start a dose of 4–8 mg of dexamethasone per day. If patients have serious symptoms consistent with raised ICP, higher doses i.e.<sup>17</sup> mg/day or more should be given. According to the available evidence, the best drug choice is dexamethasone. Corticosteroids, if given, should be tapered off rapidly but not faster than the patient's clinical tolerance, based upon a personalised treatment plan and a thorough understanding of the long-term harmful effects of corticosteroid therapy.<sup>24</sup>

## Role of AEDs

For individuals with brain metastasis who didn't undergo surgery and are seizure free, prophylactic antiepileptic drugs (AEDs) are not recommended. Routine usage of anti-epileptic drugs post-craniotomy in patients with BM who are seizure-free is also not advised.<sup>25</sup>

## Emerging and investigational therapies

There is not enough proof to advise regarding the usage of high-intensity focused ultrasound (HIFU), laser interstitial thermal therapy (LITT), interstitial chemotherapy, immune therapy, brachytherapy, the daily usage of radiation sensitizers, such as temozolomide, motexafin-gadolinium, chloroquine or sodium nitrite in other clinical settings for patients suffering from BM.

There is inadequate data to recommend epidermal growth factor receptor inhibitors like gefitinib and erlotinib in individuals with BM due to NSCLC; the role of BRAF inhibitors like vemurafenib and dabrafenib in the management of patients with BM due to metastatic melanoma; the role of HER2 agents like lapatinib and trastuzumab to manage patients with BM due to metastatic breast carcinoma; the role of vascular endothelial growth factor agents like bevacizumab, sorafenib and sunitinib, in the management of patients with solid tumour BM.<sup>26</sup>

## Prognosis

The mean survival is approximately 7 months.<sup>1</sup> If left untreated, death occurs from progressive neurologic worsening in about 4 to 6 weeks.<sup>16</sup> Despite progress in its management, the prognosis remains poor for patients with BM. Specialist palliative care involvement has a role in the treatment of rapidly progressive and highly aggressive brain neoplasm.<sup>27</sup>

## Conclusion

These guidelines provide a practical roadmap informed by valuable expertise (as indicated in Table 3 and Figure 1) and are intended for use by physicians working in areas with limited resources. By following these guidelines, there is a substantial opportunity to enhance specific outcomes and promote a greater focus on multidisciplinary healthcare in low- and middle-income countries like Pakistan.

**Disclaimer:** None.

**Conflict of Interest:** None.

**Funding Disclosure:** None.

## References

1. Jenkinson MD, Haylock B, Shenoy A, Husband D, Javdipour M.

- Management of cerebral metastasis: evidence-based approach for surgery, stereotactic radiosurgery and radiotherapy. *Eur J Cancer* 2011;47:649-55. doi: 10.1016/j.ejca.2010.11.033.
2. Enam SA, Shah MM, Bajwa MH, Khalid MU, Bakhshi SK, Baig E, et al. The Pakistan Brain Tumour Epidemiology Study. *J Pak Med Assoc* 2022;72(Suppl 4):s4-11. doi: 10.47391/JPMA.11-S4-AKUB01.
  3. Proescholdt MA, Schödel P, Doenitz C, Pukrop T, Höhne J, Schmidt NO, et al. The Management of Brain Metastases-Systematic Review of Neurosurgical Aspects. *Cancers (Basel)* 2021;13:1616. doi: 10.3390/cancers13071616.
  4. Bajwa MH, Shah MM, Mustansir F, Gauhar F, Baig E, Zafar SN, et al. A Guideline On Guidelines – Neuro-Oncology Guideline Standards For Low And Middle-Income Countries. *J Pak Med Assoc* 2024;74(Suppl 3):s87-92. Doi: 10.47391/JPMA.S3.GNO-10.
  5. Fink KR, Fink JR. Imaging of brain metastases. *Surg Neurol Int* 2013;4:S209-1. doi: 10.4103/2152-7806.111298.
  6. Arvold ND, Lee EQ, Mehta MP, Margolin K, Alexander BM, Lin NU, et al. Updates in the management of brain metastases. *Neuro Oncol* 2016;18:1043-65. doi: 10.1093/neuonc/now127.
  7. Singh K, Saxena S, Khosla AA, McDermott MW, Kotecha RR, Ahluwalia MS. Update on the Management of Brain Metastasis. *Neurotherapeutics* 2022;19:1772-81. doi: 10.1007/s13311-022-01312-w.
  8. Brastianos PK, Curry WT, Oh KS. Clinical discussion and review of the management of brain metastases. *J Natl Compr Canc Netw* 2013;11:1153-64. doi: 10.6004/jnccn.2013.0133.
  9. Nahed BV, Alvarez-Breckenridge C, Brastianos PK, Shih H, Sloan A, Ammirati M, et al. Congress of Neurological Surgeons Systematic Review and Evidence-Based Guidelines on the Role of Surgery in the Management of Adults With Metastatic Brain Tumors. *Neurosurgery* 2019;84:E152-5. doi: 10.1093/neuros/nyy542.
  10. Schebesch KM, Hoehne J, Hohenberger C, Proescholdt M, Riemenschneider MJ, Wendl C, et al. Fluorescein sodium-guided resection of cerebral metastases—experience with the first 30 patients. *Acta Neurochir* 2015;157:899–904. Doi: 10.1007/s00701-015-2395-7.
  11. Mut M. Surgical treatment of brain metastasis: a review. *Clin Neurol Neurosurg* 2012;114:1-8. doi: 10.1016/j.clineuro.2011.10.013.
  12. Gaspar LE, Prabhu RS, Hdeib A, McCracken DJ, Lasker GF, McDermott MW, et al. Congress of Neurological Surgeons Systematic Review and Evidence-Based Guidelines on the Role of Whole Brain Radiation Therapy in Adults With Newly Diagnosed Metastatic Brain Tumors. *Neurosurgery* 2019;84:E159-62. doi: 10.1093/neuros/nyy541
  13. Chen JC, Girvigian MR. Stereotactic radiosurgery: instrumentation and theoretical aspects-part 1. *Perm J* 2005;9:23-6. doi: 10.7812/TPP/04-075.
  14. Buatti JM, Friedman WA, Meeks SL, Bova FJ. RTOG 90-05: the real conclusion. *Int J Radiat Oncol Biol Phys* 2000;47:269-71. doi: 10.1016/s0360-3016(99)00506-4
  15. Rosner D, Lane WW, Nemoto T. Differential response to chemotherapy in metastatic breast cancer in relation to estrogen receptor level. Results of a prospective randomized study. *Cancer* 1989;64:6-15. doi: 10.1002/1097-0142(19890701)64:1<6::aid-cnrcr2820640103>3.0.co;2-I.
  16. Bazan F, Dobi E, Royer B, Curtit E, Mansi L, Menneveau N, et al. Systemic high-dose intravenous methotrexate in patients with central nervous system metastatic breast cancer. *BMC Cancer* 2019;19:1029. doi: 10.1186/s12885-019-6228-6.
  17. Wang N, Bertalan MS, Brastianos PK. Leptomeningeal metastasis from systemic cancer: Review and update on management. *Cancer* 2018;124:21-35. doi: 10.1002/cncr.30911.
  18. Sherman JH, Lo SS, Harrod T, Hdeib A, Li Y, Ryken T, et al. Congress of Neurological Surgeons Systematic Review and Evidence-Based

- Guidelines on the Role of Chemotherapy in the Management of Adults With Newly Diagnosed Metastatic Brain Tumors. *Neurosurgery* 2019;84:e175-7. doi: 10.1093/neuros/nyy544.
19. Patchell RA, Tibbs PA, Walsh JW, Dempsey RJ, Maruyama Y, Kryscio RJ, et al. A randomized trial of surgery in the treatment of single metastases to the brain. *N Engl J Med* 1990;322:494-500. doi: 10.1056/NEJM199002223220802.
  20. Hardesty DA, Nakaji P. The Current and Future Treatment of Brain Metastases. *Front Surg* 2016;3:30. doi: 10.3389/fsurg.2016.00030.
  21. Graber JJ, Cobbs CS, Olson JJ. Congress of Neurological Surgeons Systematic Review and Evidence-Based Guidelines on the Use of Stereotactic Radiosurgery in the Treatment of Adults With Metastatic Brain Tumors. *Neurosurgery* 2019;84:E168-70. doi: 10.1093/neuros/nyy543
  22. Ammirati M, Nahed BV, Andrews D, Chen CC, Olson JJ. Congress of Neurological Surgeons Systematic Review and Evidence-Based Guidelines on Treatment Options for Adults With Multiple Metastatic Brain Tumors. *Neurosurgery* 2019;84:E180-2. doi: 10.1093/neuros/nyy548.
  23. Schackert G, Schmiedel K, Lindner C, Leimert M, Kirsch M. Surgery of recurrent brain metastases: retrospective analysis of 67 patients. *Acta Neurochir (Wien)* 2013;155:1823-32. doi: 10.1007/s00701-013-1821-y.
  24. Ryken TC, Kuo JS, Prabhu RS, Sherman JH, Kalkanis SN, Olson JJ. Congress of Neurological Surgeons Systematic Review and Evidence-Based Guidelines on the Role of Steroids in the Treatment of Adults With Metastatic Brain Tumors. *Neurosurgery* 2019;84:E189-91. doi: 10.1093/neuros/nyy546.
  25. Chen CC, Rennert RC, Olson JJ. Congress of Neurological Surgeons Systematic Review and Evidence-Based Guidelines on the Role of Prophylactic Anticonvulsants in the Treatment of Adults with Metastatic Brain Tumors. *Neurosurgery* 2019;84:E195-7. doi: 10.1093/neuros/nyy545
  26. Elder JB, Nahed BV, Linskey ME, Olson JJ. Congress of Neurological Surgeons Systematic Review and Evidence-Based Guidelines on the Role of Emerging and Investigational Therapies for the Treatment of Adults With Metastatic Brain Tumors. *Neurosurgery* 2019;84:E201-3. doi: 10.1093/neuros/nyy547.
  27. Gofton TE, Graber J, Carver A. Identifying the palliative care needs of patients living with cerebral tumors and metastases: a retrospective analysis. *J Neurooncol* 2012;108:527-34. doi: 10.1007/s11060-012-0855-y

---

**DISCLAIMER**

Articles published in JPMA and Supplements of JPMA do not represent the views of the editor or editorial Board. Authors are solely responsible for the opinions expressed and the accuracy of the data.

The contribution of each author towards the published research included in this supplement is the responsibility of the authors and their institutions. It is expected to be in accordance and compliance with the ICMJE Guidelines.

Any questions/queries raised by readers should be directed to the corresponding author.

## NARRATIVE REVIEW

## Consensus guidelines for the management of posterior fossa tumour for low and middle-income countries

Hafiza Fatima Aziz<sup>1</sup>, Mohammad Hamza Bajwa<sup>2</sup>, Naureen Mushtaq<sup>3</sup>, Saqib Kamran Bakhshi<sup>4</sup>, Kaynat Siddiqui<sup>5</sup>, Saad Akhtar Khan<sup>6</sup>, Rabeet Tariq<sup>7</sup>, Muhammad Shakir<sup>8</sup>, Mehar Masroor<sup>9</sup>, Fatima Suleman<sup>10</sup>

**Pakistan Brain Tumour Consortium:** (Authors list at the end of the supplement), Syed Ather Enam<sup>11</sup>.

### Abstract

The posterior fossa is a limited compartment therefore lesions compressing its structures can result in devastating outcomes. It can cause significant neurological deficit due to mass effect on critical structures and hydrocephalus. Due to the nature of the infratentorial region, urgent surgical intervention is often the first-line option. Surgical neuro-oncologists guide patients and caregivers through the course of this disease and to inform them about the various options for management and long-term outcome optimisation. There is currently conflicting data; however, institutional experiences can guide us towards achieving improvements in surgical outcomes and quality of life. Advances in molecular classifications coupled with high-dose radiation treatment improve our capacity for improving overall survival in these patients. Common childhood tumours are ependymomas, medulloblastomas, and juvenile pilocytic astrocytomas, while adults often present with metastases, and less commonly, cerebellar haemangioblastomas and gliomas. This paper outlines management strategies with consideration for multidisciplinary care and resource-limited settings.

**Keywords:** Cerebellar neoplasms, medulloblastoma, caregivers, hemangioblastoma, astrocytoma, ependymoma, hydrocephalus, neuro-oncology, neurosurgery, brain tumour, posterior fossa.

**DOI:** <https://doi.org/10.47391/JPMA.S3.GNO-22>

### Introduction

Posterior fossa brain tumours (PFBT) pose challenges for neuro-oncologists in balancing interventions for achieving long-term oncological control with quality of life and functional durability. Paediatric PFBT commonly present with obstructive hydrocephalus and gait

instability; these are mainly medulloblastoma, ependymomas, and juvenile pilocytic astrocytomas.<sup>1</sup> The most common adult malignancy within the posterior fossa is metastasis, as the prior pathologies are relatively rare in adults.<sup>2</sup> Cerebellar haemangioblastomas may also be present, particularly within Von-Hippel Lindau syndrome – necessitating a thorough examination for other stigmata.

Generally, standard care for PFBT includes surgery followed by adjuvant radiation or chemotherapy, depending on pathology. Controversies exist with regards to persistent hydrocephalus despite surgical resection, reported in almost 1/3<sup>rd</sup> of patients; this necessitates diversion either through VP shunt or ETV procedure, each of which has its own complications and failure rates.<sup>3</sup> While VP shunts are associated with more complications such as infection and requiring redo-shunt procedures, ETV were shown to have earlier time-to-failure however with longer durability. Long-term quality of life after PFBT surgery has shown to be affected by socioeconomic status and hydrocephalus.<sup>4</sup> Other issues such as posterior fossa syndrome (cerebellar mutism syndrome), impaired swallowing, and cognitive impairment following radiation treatment also pose long-term challenges.<sup>5-7</sup>

### Methodology

The literature search of the high-quality data on posterior fossa tumours was done in July 2022 on different databases including PubMed, Google Scholar, Scopus, and Embase. The most relevant and high-quality studies were analyzed to develop the evidence-based recommendations. An expert panel was convened consisting of specialists and leading experts within the field of neuro-oncology to identify the gaps in diagnosis and management of posterior fossa tumours within Pakistan. This group was tasked with identifying best-practice recommendations and their application within the context of Pakistan as an LMIC. Recommendations were collated, reviewed and debated regarding utility and evidence-based practices, in a process that has been previously detailed.<sup>8</sup>

<sup>1,2,4,5,8-11</sup>Department of Neurosurgery, The Aga Khan University, <sup>3</sup>Department of Paediatric Oncology, The Aga Khan University, <sup>7</sup>Jumma Research Laboratories, The Aga Khan University, Karachi, Pakistan

**Correspondence:** Syed Ather Enam **Email:** [ather.enam@aku.edu](mailto:ather.enam@aku.edu)



## Importance of surgical clearance

Patients presenting with neurological signs suggestive of obstructive hydrocephalus and posterior fossa signs should have a complete radiological workup. MRI brain study with contrast allows characterisation of these lesions, degree of hydrocephalus, and assessment of nearby critical structures. For paediatric patients, MRI spine with contrast should ideally also be performed within the same setting as PFBT may present with drop metastases to the spine, further complicating management. Here, the role of an experienced radiologist or fellowship-trained neuroradiologist is crucial in effectively communicating the understanding of distinct imaging features on MRI and confidently determining the management pathway. For instance, in cases where a tumour exhibits benign features, resembling a haemangioma or juvenile pilocytic astrocytoma (JPA), extensive spine MR imaging may not be necessary. On the other hand, detecting likely malignant lesions on MRI can help plan for extensive surgery. Often, workup may be delayed due to patients presenting in obtunded conditions – in such cases, radiology can be obtained within 72 hours after surgery, and should ideally be performed when possible, as recommended by international consensus guidelines.<sup>9</sup> Since adult patients commonly present with metastatic lesions, a CT chest, abdomen, and pelvis with IV contrast is recommended to rule out primary pathologies.

Surgical resection is guided on principles of achieving maximum safe resection, opening CSF pathways, and decompression of critical structures, often the midbrain. Degree of surgical resection in PFBT has a strong association with overall survival and avoidance of persistent hydrocephalus<sup>10</sup> thus reinforcing maximal safe resection. It is ideal to avoid a simple biopsy of the lesion or diverting with a VP shunt. In resource-limited settings, although a simple biopsy may initially falsely 'improve' symptoms; the patient will eventually require a second, more difficult, redo-procedure to achieve greater tumour reduction. As has been shown in many LMICs, many neuro-oncological patients are lost-to-follow-up, ultimately resulting in a worse outcome for these patients.<sup>11</sup> Lesions adherent to critical structures may be resected while leaving residual tumours in areas where not possible, such as critical vascular structures or the midbrain. This remnant tumour can be treated optimally later on with radiation therapy, particularly targeted, stereotactic radiosurgery. A postoperative scan to assess tumour resection and for any complications should be performed within 48 hours of surgery.

## Considerations for adjuvant therapy and follow-up

The posterior fossa is the most commonly irradiated intracranial compartment in the paediatric population despite the toxicity profile. Craniospinal irradiation to control microscopic disease has been linked to significant improvements within overall survival for PFBT, albeit with cognitive and endocrinological morbidity. This has been further improved with hyperfractionated regimens with tumour-bed radiation boost, to reduce radiation toxicity to surrounding normal neural tissue. Ideally, this is determined on assessment of risk of the patient, with a paediatric neuro-oncologist. Surgeons aiming for safe resection may find it useful to leave tumour adherent to critical structures and refer for radiation (stereotactic radiosurgery) to achieve good control with intact neurological function. In ependymoma particularly, routine neuroaxis radiation is not advised unless evidence of dissemination is seen.

Surgery remains the mainstay of treatment in many of PFBT patients, barring metastatic or unresectable disease. Advancements such as greater use of pre-resection ETV and targeted radiotherapy have expanded the safety profile of surgery for PFBT. Unfortunately, with ETV there still remain limitations and some patients will ultimately need VP shunt insertion for long-term control. There are promising results with endoscopic cauterization of the choroid plexus (CPC) combined with ETV to limit CSF production and improve overall success.<sup>12</sup> These options may be more viable in resource-limited settings, where avoiding another repeat surgery with shunt complications in the long-term may not be feasible for many patients.

Extent of resection remains a major predictor for survival in medulloblastoma, ependymoma, and JPA – high-dose radiation of the tumour bed has shown marked improvement in long-term survival as well. Unfortunately, we are still looking for better ways to approaching and treating DIPG and ATRT. Recurrent disease should be evaluated in multidisciplinary tumour boards in tandem with paediatric neuro-oncologists and other experts; especially with residual posterior fossa ependymoma, repeat surgery is a viable option.

EVD insertion can be a temporising procedure while planning definitive surgery particularly in cases of initial hydrocephalus – however, a recent systematic review has unfolded a unique perspective into the use of EVDs in asymptomatic hydrocephalus as well.<sup>13</sup> EVDs should ideally be removed within 48-72 hours – if hydrocephalus persists, a permanent VPS may be considered. This will

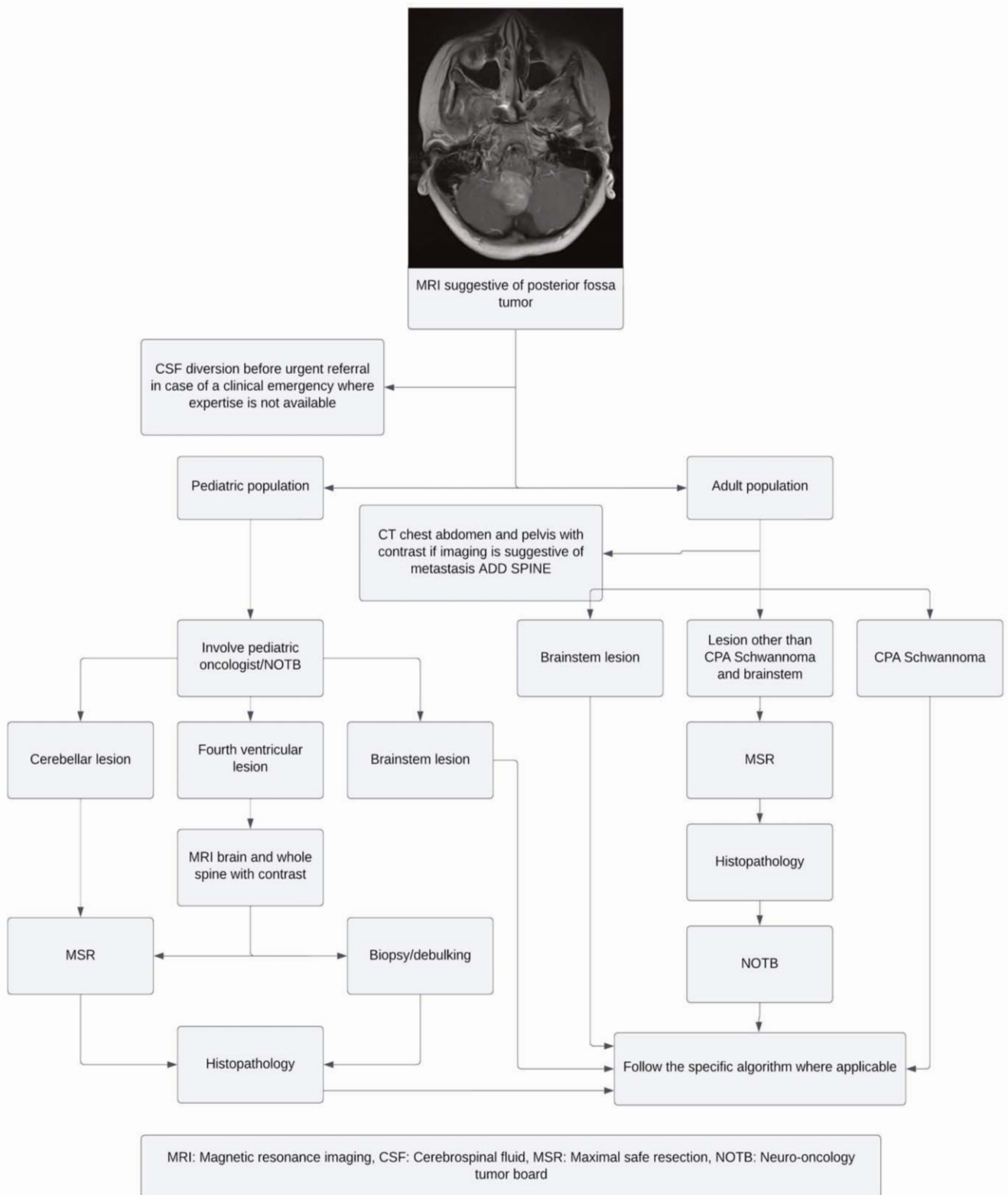


Figure-1: Management of Posterior fossa tumours algorithm.

**Table-1:** Summary of Recommendations for Posterior Fossa Neoplastic Lesions.

<b>Radiology</b>	<ul style="list-style-type: none"> <li>• MRI brain with and without contrast.</li> <li>• 'Minimum required' MRI protocol:               <ul style="list-style-type: none"> <li>o Imaging on at least 0.5T.</li> <li>o Sequences: Axial T2 and coronal or axial FLAIR sequence; pre-contrast T1 and contrast enhanced T1.</li> </ul> </li> <li>• Tumour location, size, margins, enhancement pattern, presence of hydrocephalous, haemorrhage/mineralisation, oedema, involvement of critical neurovascular structure.</li> <li>• If imaging is suggestive of the metastatic lesion, systemic imaging is required (CT CAP/PET).</li> <li>• For surgical planning, CTA is required to delineate vascular anatomy where needed.</li> <li>• Postoperative MRI is recommended and tailored to each pathology.               <ul style="list-style-type: none"> <li>o For intra-axial/fourth ventricular lesion a post-operative MRI is recommended within 72 hours of surgery or after 6 weeks if delayed. For extra-axial after 3 months.</li> <li>o To identify the extent of resection.</li> <li>o To have a baseline to compare successive imaging.</li> <li>o Not required after biopsy.</li> </ul> </li> </ul>
<b>Neurosurgery</b>	<ul style="list-style-type: none"> <li>• CSF diversion before urgent referral in case of a clinical emergency where expertise is not available.</li> <li>• Maximal safe resection with preservation of critical neurovascular structures.</li> </ul>
<b>Medical and Radiation Oncology</b>	<ul style="list-style-type: none"> <li>• Tailored approach for each pathology after discussing in NOTB.</li> </ul>
<b>Neuropathology</b>	<ul style="list-style-type: none"> <li>• Haematoxylin and Eosin (H&amp;E) preparation for histological typing.</li> <li>• Relevant immunohistochemical stains for definite characterisation based on the histology of the tumour.</li> </ul>
<b>Follow-up</b>	<ul style="list-style-type: none"> <li>• First follow-up at post-op day 10 for wound assessment, stitch removal, discussion related to histopathology and NOTB recommendations.</li> <li>• Clinical follow-up with MRI tailored to histopathological diagnosis.</li> </ul>

MRI: Magnetic resonance imaging, FLAIR: Fluid-attenuated inversion recovery, CT-CAP: Computed tomography of chest, abdomen and pelvis, PET: Positron Emission Tomography, CTA: Computed tomography angiography, CSF: Cerebrospinal fluid, NOTB: Neuro-Oncology tumour board.

require extensive counselling of the family regarding warning signs of shunt malfunction, need for life-long care, and potential re-do procedures. Clinical tools for

predicting postoperative hydrocephalus in PFBT may have a role in selecting high-risk patients; the modified Canadian Preoperative Prediction Rule for Hydrocephalus (mCPPRH) uses age, degree of hydrocephalus, tumour metastasis, pathology type, and trans-ependymal oedema as co-factors for prediction.<sup>14</sup> A recent study from China in 2022 expanded this clinical tool within their own institution, finding key risk factors to include higher grade tumours, metastatic disease, and postoperative ventricular blood predicting need for postoperative shunt requirement.<sup>15</sup> Further utilisation of these tools and validation at other centres may be clinically useful, warranting closer follow-ups and caregiver education in patients with PFBT.

### Diagnostic pearls

In summary, patients presenting with posterior fossa lesions should be worked up in a methodological fashion as shown in Table 1 and Figure 1.

### Conclusion

Long-term improvement of outcomes in PFBT patients requires careful surgical planning and maximising our ability to resect the tumour. For specific disease subtypes, it is beneficial to use multidisciplinary care plans for postoperative radiotherapy and chemotherapy.

**Disclaimer:** None.

**Conflict of Interest:** None.

**Funding Disclosure:** None.

### References

1. Muzumdar D, Ventureyra EC. Treatment of posterior fossa tumors in children. *Expert Rev Neurother* 2010;10:525-46. doi: 10.1586/ern.10.28.
2. Grossman R, Ram Z. Posterior Fossa Intra-Axial Tumors in Adults. *World Neurosurg* 2016;88:140-5. doi: 10.1016/j.wneu.2015.12.066.
3. Dewan MC, Lim J, Shannon CN, Wellons JC. The durability of endoscopic third ventriculostomy and ventriculoperitoneal shunts in children with hydrocephalus following posterior fossa tumor resection: a systematic review and time-to-failure analysis. *J Neurosurg Pediatr* 2017;19:578-84. doi: 10.3171/2017.1.PEDS16536.
4. Baqai MWS, Tariq R, Shah Z, Bajwa MH, Shamim MS. Quality of life in survivors of pediatric medulloblastoma: a systematic review and meta-analysis. *Childs Nerv Syst* 2023;39:1159-71. doi: 10.1007/s00381-023-05886-4.
5. Bakhshi SK, Mitha R, Mushtaq N, Shamim MS. Cerebellar Mutism Syndrome after surgical resection of posterior fossa neoplastic lesions. *J Pak Med Assoc* 2020;70:1667-8.
6. Kulkarni AV, Piscione J, Shams I, Bouffet E. Long-term quality of life in children treated for posterior fossa brain tumors. *J Neurosurg Pediatr* 2013;12:235-40. doi: 10.3171/2013.6.PEDS12535.
7. Panwala TF, Fox ME, Tucker TD, King TZ. The Effects of Radiation and Sex Differences on Adaptive Functioning in Adult Survivors of Pediatric Posterior Fossa Brain Tumors. *J Int Neuropsychol Soc* 2019;25:729-39. doi: 10.1017/S135561771900033X.
8. Bajwa MH, Shah MM, Mustansir F, Gauhar F, Baig E, Zafar SN, et al.

- A Guideline On Guidelines – Neuro-Oncology Guideline Standards For Low And Middle-Income Countries. *J Pak Med Assoc* 2024;74(Suppl 3):s87-92. Doi: 10.47391/JPMA.S3.GNO-10.
9. Leblond P, Massimino M, English M, Ritzmann TA, Gandola L, Calaminus G, et al. Toward improved diagnosis accuracy and treatment of children, adolescents, and young adults with ependymoma: the International SIOP Ependymoma II Protocol. *Front. Neurol.* 2022;13:887544. doi:10.3389/fneur.2022.887544.
  10. Zhang C, Zhang T, Ge L, Li Z, Chen J. Management of Posterior Fossa Tumors in Adults Based on the Predictors of Postoperative Hydrocephalus. *Front Surg* 2022;9:886438. doi: 10.3389/fsurg.2022.886438.
  11. Khalid MU, Bajwa MH, Shah MM, Zafar SN, Laghari AA, Akhuzada NZ, et al. Factors associated with lost to follow up in patients with brain tumours: A multi-centre study in Pakistan. *J Pak Med Assoc* 2022;72(Suppl 4):s16-24. doi: 10.47391/JPMA.11-S4-AKUB03.
  12. Cinalli G, Spennato P. Controversies in the Endoscopic Management of the Various Forms of Hydrocephalus. In: Sgouros S, eds. *Neuroendoscopy*. Heidelberg, Germany: Springer-Verlag Berlin Heidelberg, 2014; pp 47-56. doi: 10.1007/978-3-642-39085-2\_4
  13. Anania P, Battaglini D, Balestrino A, D'Andrea A, Prior A, Ceraudo M, et al. The role of external ventricular drainage for the management of posterior cranial fossa tumours: a systematic review. *Neurosurg Rev* 2021;44:1243-53. doi: 10.1007/s10143-020-01325-z.
  14. Foreman P, McClugage S, Naftel R, Griessenauer CJ, Ditty BJ, Agee BS, et al. Validation and modification of a predictive model of postresection hydrocephalus in pediatric patients with posterior fossa tumors. *J Neurosurg Pediatr* 2013;12:220-6. doi: 10.3171/2013.5.PEDS1371.
  15. Zhang N, Zhang D, Sun J, Sun H, Ge M. Contribution of tumor characteristics and surgery-related factors to symptomatic hydrocephalus after posterior fossa tumor resection: a single-institution experience. *J Neurosurg Pediatr* 2022;31:99-10. doi: 10.3171/2022.10.PEDS22281.

---

**DISCLAIMER**

Articles published in JPMA and Supplements of JPMA do not represent the views of the editor or editorial Board. Authors are solely responsible for the opinions expressed and the accuracy of the data.

The contribution of each author towards the published research included in this supplement is the responsibility of the authors and their institutions. It is expected to be in accordance and compliance with the ICMJE Guidelines.

Any questions/queries raised by readers should be directed to the corresponding author.

## Consensus guidelines for the management of primary supra-tentorial intraventricular tumour for low- and middle-income countries

Hafiza Fatima Aziz<sup>1</sup>, Saqib Kamran Bakhshi<sup>2</sup>, Rabeet Tariq<sup>3</sup>, Muhammad Waqas Saeed Baqai<sup>4</sup>, Mohammad Hamza Bajwa<sup>5</sup>, Kaynat Siddiqui<sup>6</sup>, Zanib Javed<sup>7</sup>, Ahsan Ali Khan<sup>8</sup>, Muhammad Shakir<sup>9</sup>

**Pakistan Brain Tumour Consortium:** (Authors list at the end of the supplement), Syed Ather Enam.

### Abstract

Almost any primary or metastatic brain tumour can manifest in intraventricular (IV) locations. These tumours may either originate within the ventricular system or extend into the IV space through growth. Such neoplasms represent a broad spectrum, with supratentorial IV tumours forming a heterogeneous group. This group includes primary ependymal tumours, central neurocytomas, choroid plexus tumours, and notably, meningiomas, as well as a variety of non-neoplastic, benign, glial, and metastatic lesions that can secondarily invade the IV compartment. Often presenting with non-specific symptoms, these tumours can lead to delayed medical attention. The diversity in potential diagnoses, combined with their deep and complex locations, poses significant management challenges. This paper aims to delineate optimal management strategies, underscoring the importance of multidisciplinary care, especially in settings with limited resources, to effectively navigate the complexities associated with treating intraventricular brain tumours.

**Keywords:** Meningeal neoplasms, meningioma, neurocytoma, choroid plexus, neoplasms, intraventricular tumour, supratentorial tumours.

**DOI:** <https://doi.org/10.47391/JPMA.S3.GNO-23>

### Introduction

Primary Intraventricular (IV) Tumours of the supratentorial compartment are a histologically heterogeneous group of tumours. They include ependymal tumours arising from ependymal cells and subependymal glial plate, central neurocytomas from the septum pellucidum, and choroid plexus papilloma (CPP) and carcinoma (CPC) from the choroid plexus.<sup>1</sup> Ependymal tumours including ependymomas, subependymomas, and subependymal

giant cell astrocytomas (SEGAs) account for about 1.6–1.8%, whereas choroid plexus tumours account for 0.2% of all primary tumours of the central nervous system (CNS).<sup>2</sup> Any intracranial tumour may have an intraventricular location. Some common IV lesions include colloid cysts, craniopharyngiomas, pituitary adenomas, and arachnoid cysts. Glial as well as metastatic tumours may secondarily involve ventricles. Intraventricular meningioma, although an uncommon form of intracranial meningiomas (0.5–3%), is one of the common IV tumours.<sup>3</sup>

The ventricular system is one of the most challenging territories for neurosurgery. Recent technical advancements and microsurgical expertise have revolutionised surgical corridors. However, dealing with intraventricular pathologies still poses substantial challenges, and surgical morbidity remains an added factor affecting patient outcomes.

In low- and middle-income countries (LMICs), where healthcare disparities are noticeable in managing brain tumours, the challenges of addressing intraventricular tumours are even more pronounced. Practicality and working dynamics in LMICs must be addressed separately to ensure a safe approach and standardized outcome. We proposed these guidelines by incorporating the most up-to-date evidence-based practices and reflecting the unique challenges faced by patients and healthcare providers in LMICs.

### Methodology

The literature search of the high-quality data on intraventricular tumours was done on different databases including PubMed, Google Scholar, Scopus, and Embase in October 2023. The most relevant and high-quality studies were analyzed to develop the evidence-based recommendations. An expert panel was convened consisting of specialists and leading experts within the field of neuro-oncology to identify the gaps in diagnosis and management of intraventricular tumours within Pakistan. This group was tasked with identifying best-practice recommendations and their application within

.....  
<sup>1,2,4-10</sup>Department of Neurosurgery, The Aga Khan University, Karachi, Pakistan. <sup>3</sup>Jumma Research Laboratories, The Aga Khan University, Karachi, Pakistan.

**Correspondence:** Syed Ather Enam **Email:** [ather.enam@aku.edu](mailto:ather.enam@aku.edu)

the context of Pakistan as an LMIC. Recommendations were collated, reviewed and debated regarding utility and evidence-based practices, in a process that has been previously detailed.<sup>4</sup>

### Initial evaluation

The clinical presentation of IV tumours is often nonspecific such as headache, gait abnormalities, and cognitive deficits; usually caused by hydrocephalus (HCP) and/or the tumour mass leading to increased intracranial pressure.

### Ependymal tumours

All ependymal tumours appear iso- to hypointense to white matter on T1, whereas on T2 they appear hyperintense to surroundings. Gadolinium contrast shows heterogeneous enhancement in ependymomas, no to mild enhancement in subependymomas (larger lesions may be heterogeneous), and marked enhancement in SEGAs. Ependymomas are also more common in paediatric populations, subependymomas may be seen in adults and older children. SEGAs are seen only in young patients following tuberous sclerosis.<sup>5-8</sup>

Ependymomas commonly occur in the fourth ventricle. However, 30% arise from the surfaces of the lateral ventricles or the septum pellucidum.<sup>9</sup> Grade II tumours have a greater incidence of calcification than Grade III ependymomas, and cystic components may be present in both.<sup>10</sup>

Subependymomas commonly occur in the lateral ventricles (44.5%), followed by the fourth ventricle (43.1%) foramen of Monro (6.2%), and rarely the third ventricle.<sup>11</sup> They typically have a diameter of less than 1-2 cm. If large they may also contain cystic or calcific components.<sup>11</sup>

SEGAs are differentiated from subependymomas predominantly based on size. Subependymal nodules transform into SEGAs over some time and are usually seen as an IV mass near the foramen of Monroe. Calcification, haemorrhage, and/or accompanying HCP may be present. Contrast often shows marked enhancement.<sup>7</sup> Subependymal nodules and SEGAs are distinguished based on the potential for growth and mass effect.<sup>5</sup>

Ependymomas can manifest as either a cohesive mass or a combination of solid and cystic growth patterns. Magnetic resonance (MR) spectroscopy typically shows increased choline levels and diminished N-acetyl aspartate levels in ependymomas, while subependymomas show a regular choline peak and reduced N-acetyl aspartate peak.<sup>7, 9</sup> Grade 3 ependymomas show

restricted diffusion on DWI/ADC.<sup>6, 9</sup>

### Central neurocytomas

Central neurocytomas are common around the foramen of Monro (50%), followed by lateral and 3rd ventricles (15% each), and 3rd ventricle (5%).<sup>5</sup> On CT scan they are hyperattenuating compared to white matter. Cystic region and /or calcification are frequently present. Contrast enhancement is usually mild to moderate.<sup>5, 6</sup>

On T1-weighted imaging, the lesion displays an uneven isointense lesion, while on T2/FLAIR sequences, it appears either similar or brighter in intensity. T2-weighted images may also reveal cystic regions, giving rise to a bubbly or Swiss cheese-like appearance, with some of these areas showing reduced intensity on FLAIR images. Diffusion-weighted imaging (DWI) indicates restricted diffusion in the solid portions of the lesion. Magnetic resonance spectroscopy (MR spectroscopy) could indicate a prominent choline peak. Angiography reveals a tumour blush supplied by choroidal vessels.<sup>12, 13</sup>

### Choroid plexus tumours

Choroid Plexus tumours including Choroid Plexus Papilloma (CPP) and Choroid Plexus Carcinoma (CPC) are vividly enhancing IV masses. They are common in the fourth ventricle, and in the lateral ventricles in children: with a predilection for the trigone. HCP is more likely with CPP than CPCs. They appear iso to hyperdense on non-contrast CT. On MRI sequences they appear iso to hypointense on T1, and iso to hyperintense on T2 MRI sequences.

CPPs present as clearly defined, lobulated masses that exhibit uniform enhancement upon contrast administration. They often display an irregular frond-like pattern (cauliflower-like appearance). In contrast, CPCs are tumours characterized by heterogeneous enhancement, often featuring distinct regions of necrosis and cystic formation. Around 25% of CPP cases show speckled calcification. Angiography reveals a pronounced vascular blush, with the tumour supplied by enlarged choroidal arteries.<sup>6, 14, 15</sup>

### Meningioma

IV meningioma originates from the stroma of the choroid plexus, a normal location for arachnoid cells that give rise to these tumours.<sup>16</sup> It arises from a region where arachnoid cells are found secondary to the embryonic origin of the choroid plexus. As with most intracranial meningiomas, those located in the ventricles are benign WHO-grade I tumours in 90% of cases.<sup>17</sup> They account for up to 5% of all IV tumours.<sup>17-18</sup> Their most common location is the atrium of the lateral ventricle, followed by

the trigone of the lateral ventricle.<sup>17</sup>

These are slow-growing lesions, typically found incidentally in radiology. The usual clinical presentations include headache or signs and symptoms of hydrocephalus or visual impairment. On MRI brain, they appear as well-circumscribed, mostly solid lesions, iso- or hypo-intense on T1 and T2 weighted images, and show homogenous contrast enhancement. CT angiogram or digital subtraction angiography (DSA) provides information about the blood supply, which can occasionally be embolised. IV meningiomas usually receive blood supply from the anterior choroidal artery, but larger lesions also receive supply from the posterior choroidal artery. The venous drainage is into deep ventricular veins.

### Differentials and diagnostic challenges in LMICs

Other than primary IV tumours, other differential diagnoses of IV lesions may be IV meningiomas (most common), medulloblastoma, teratomas, gliomas (oligodendroglioma, pilocytic astrocytoma) cystic lesions, and IV metastases. IV meningioma appears as a well-circumscribed mass (isodense and isointense to grey matter) with homogeneous contrast enhancement, most commonly in the trigone of the lateral ventricles.<sup>19</sup> In children, almost one-fifth of all meningiomas occur within the ventricular system. In these patients, Neurofibromatosis should be always suspected.<sup>19</sup> Astrocytomas are frequently observed in the paediatric population but have also been identified in young adults. They predominantly affect the cerebellar hemispheres, although involvement of the foramen of Monro is possible. On CT scans, they present as either cystic or hypodense solid masses. When viewed on MRI, they can be challenging to differentiate from an intraventricular meningioma.<sup>22</sup> Medulloblastomas, the most prevalent malignant brain tumours among children, originate from the midline and are typically situated in the posterior fossa. These tumours often occupy the fourth ventricle and are commonly found within the cerebellar vermis, with an occurrence rate of approximately 67%-93%.<sup>21</sup> IV teratomas manifest as heterogeneous masses with areas of both low attenuation (attributable to fat content) and high attenuation reflecting calcifications. On MRI, they manifest as irregular, lobulated masses with a hypointense signal. Metastatic lesions from various primary cancers such as renal cell carcinoma, lung carcinoma, melanoma, gastric carcinoma, colon carcinoma, and lymphoma can also occur within the atrium of the lateral ventricle.<sup>20</sup>

There are multiple factors attributing to delayed diagnosis of such tumours in LMIC. Late presentation to a tertiary care center or good clinicians leading to delay in seeking neurosurgical care, limited resources to be able to get a good quality contrast MRI, and lack of neuro-radiologists to accurately describe such lesions and narrow down the differentials are among few challenges faced in LMIC.

### Histopathology and molecular markers ependymal tumours

The WHO-CNS5 divides supratentorial ependymomas into ZFTA (RELA) fusion-positive and YAP1-MAMLD1 fusion. In 17-30% of cases, both these alterations are absent. In situations where different genetic mutations are identified, the term "NEC" (Not Elsewhere Classified) can be employed.<sup>22, 23</sup>

Subependymomas, classified as grade I tumours, arise from the subependymal glial layer with low cellularity and no mitoses, no necrosis, and are hypovascular. Loose perivascular pseudorosettes are occasionally seen.<sup>5</sup> Subependymoma cells express GFAP, whereas EMA is usually negative.<sup>24</sup>

SEGA cells that appear astrocytic, usually resemble with a lesser amount of ganglionic-appearing giant pyramidal-like cells. They are of a mixed neuronal and glial lineage arising from subependymal nodules in the ventricular wall of patients with tuberous sclerosis. SEGAs are S100 positive. GFAP, synaptophysin, class III beta-tubulin, NeuN, and SOX2 are variable. CD34 is negative.<sup>24</sup>

### Central neurocytomas

Central neurocytomas, categorized as grade II tumours, exhibit a delicate grey hue and a friable texture. They may display instances of calcification and haemorrhage. On microscopy, the cells appear uniform and round, with a chromatin pattern resembling salt and pepper, finely speckled.<sup>24</sup> Immunohistochemically, central neurocytomas typically exhibit positivity for synaptophysin, NeuN, neuron-specific enolase, and MAP2, as well as class III beta-tubulin, whereas GFAP, IDH-1, and R132H are absent.

### Choroid plexus tumours

CPPs, designated as WHO grade I lesions, are characterized by minimal mitotic activity (less than 2 mitoses per 10 high-power fields). Their appearance closely resembles normal choroid plexus tissue, taking on a cauliflower-like structure. Under a microscope, they showcase papillary formations with a delicate fibrovascular core. These papillae are lined by columnar or cuboidal epithelial cells featuring vesicular basal nuclei. In

terms of immunohistochemistry, cytokeratins (particularly CK7) and vimentin tend to be positive, while transthyretin is usually positive as well. The expression of S100 protein varies, and KIR7.1 is typically positive and specific.<sup>24</sup>

On the other hand, CPCs are categorized as grade III tumours that typically originate de novo, although there are rare instances where they can emerge as a malignant transformation of a CPP. CPCs appear as lobulated masses with areas of cyst formation and necrosis. Microscopically, the diagnosis of CPC is established when at least 4 out of 5 of the following features are present: an elevated mitotic rate (more than 5 per 10 high-power fields), heightened cellularity, nuclear pleomorphism, necrosis, and distorted papillary structure. The presence of microcalcifications and haemorrhage may also be noted. Distinguishing CPC from CPP involves identifying brain parenchymal invasion. The immunophenotype of carcinomas is akin to that of CPP, although S100 and transthyretin are more likely to be negative. The p53 protein is positive in individuals with a TP53 mutation.<sup>24</sup>

Most of the centers in LMIC are usually only equipped with basic neuro-pathological stains and lack molecular laboratories to assist in accurately diagnosing these tumours according to the recent WHO tumour classification<sup>24</sup> which is now largely dependent on molecular and genetic features of every CNS tumour.

### Meningioma

Among a wide range of histological appearances, the most common subtypes are meningothelial, fibroblastic, and transitional meningiomas. All of these tumours are positive for Vimentin, a non-specific marker. Other important stains include those for somatostatin receptor 2a, S100, Ki-67 and progesterone receptors.

### Management

Depending upon the clinical condition, the patient should be under the joint care of a neurologist and neurosurgeon at a tertiary care center with the availability of a neuro-intensivist along with respective medical and surgical suites. A lot of centers in LMIC lack such institutes.

### Surgical resection

The extent of resection (EOR) is the single most important prognostic factor for IV tumours. The aim is to achieve gross total resection (GTR), however, for patients with sub-total resection (STR) adjuvant therapy including radio- or/and chemotherapy may be beneficial. The choice of adjuvant therapy depends on the histologic diagnosis.

Surgical resection of IV tumours is particularly challenging as they are deep-seated lesions within the ventricles. The approaches to the ventricles might involve important fiber tracts and essential cortical areas. The surgical approach to IV tumours requires good anatomical precision to preserve the eloquent areas and white matter tracts. Several adjuncts have been used such as navigation systems, tractography, ultrasonic surgical aspirators, high-magnification microscopes, and endoscopes. In LMICs, the cost of these adjuncts limits their use. With deep anatomical knowledge of cortical, subcortical, and IV regions and thorough surgical planning comparable outcomes can be achieved.

The presence of symptomatic HCP may require CSF diversion either with endoscopic/external ventriculostomy or permanent ventriculoperitoneal shunt, before the surgical excision.<sup>25</sup> However, permanent CSF diversion should be deferred. CSF pathways in most of the patients after surgical clearance will be open and do not require CSF diversion. This can potentially avoid the list of complications and the cost related to shunts. Dilated ventricular systems also provide a flexible corridor for an endoscopic approach, thus necessitating restraint in performing CSF diversion for asymptomatic/non-urgent cases.

The learning curve for IV tumours is steep, emphasizing the importance for surgeons practicing in LMICs to carefully consider it. When deciding on the surgical approach, several factors such as tumour size and location, vascular supply, and dominance of the involved hemisphere are necessary to take into account.<sup>26, 27, 28</sup>

A variety of surgical approaches exist for such tumours. It largely depends upon the exact location of individual tumours and their radiological characteristics. Common approaches include the subtemporal route that serves as the primary lateral corridor for accessing the third ventricle, interhemispheric approaches to the lateral and third ventricles, and the transcortical route in cases of significant unilateral lesions located in the frontal horn, anterior lateral ventricular body, or the anterior upper region of the third ventricle. It is important to de-vascularize IV meningioma during early part of resection. Thus, a high parietal or low temporal transcortical approach is most appropriate for most tumours in the lateral ventricles. Because of the solid and firm tissue of meningioma, ultrasonic aspirator (CUSA) is beneficial for debulking/resection. A supracerebellar infratentorial approach of the velum interpositum can reach the posterior part of the third ventricle, while a trans-sylvian approach is more suitable for anterior lesions. For lesions in the medial and posterior part of the temporal horn, and



for lesions extending into the surrounding cisterns, the transcortical and trans-sulcal approaches offer a shorter trajectory and less temporal lobe retraction.<sup>26-29</sup>

Both rigid and flexible endoscopes enhance the visualization and navigation of ventricular anatomy, thus, minimizing cortical and subcortical disruption. Ventricular dilation caused by HCP ample space for endoscopic maneuvering. Endoscopic-assisted microsurgical techniques contribute to smaller craniotomies, less brain retraction, and a lower risk of white matter damage.<sup>30, 31</sup>

The potential complications include haemorrhage (IV, intraparenchymal, or epidural), meningitis and/or ventriculitis, memory disturbances, CSF leak, cranial nerve deficit, and hormonal disturbances.<sup>31</sup> The rate of complications varies from 0 to 25%.<sup>31-33</sup> The extent of resection is the most significant for the long-term prognosis of most tumours<sup>34, 35</sup>, therefore multiple surgical resections or 'second-look surgery' may be necessary in certain patients with incomplete resections and/or recurrent tumours.<sup>36,37</sup> The severity of complications dictates the post-operative course but may generally require hospital stay in high dependency or intensive care units which again is a significant problem in resource-constrained settings.

## Radiotherapy

The role of radiotherapy for primary IV tumours is still evolving. Each case needs to be reviewed on an individual basis in the neuro-oncology tumour board. Very few centers in LMIC specialize in craniospinal radiotherapy and the availability of appointment dates could be a significant issue in such patients. High-grade tumours with partial resection should get priority due to the aggressive course of the disease.

The role of adjuvant radiotherapy in primary IV tumours is established in ependymomas.<sup>38,39</sup> For subependymomas, routine postoperative irradiation is not recommended, however, it can be considered for cases with symptomatic residual or recurrent tumours.<sup>40, 41</sup> Incompletely resected SEGA tends to regrow, thus stereotactic laser interstitial thermal therapy can be offered to selected cases for optimal outcomes.<sup>42, 43</sup> Central Neurocytomas with greater than 2% residual tumour are at higher risk of local recurrence.<sup>44-46</sup> For central neurocytomas with STR, postoperative adjuvant has shown favorable outcomes for overall- and progression-free survival.<sup>46-50</sup>

While GTR can lead to a cure for the majority of patients with Choroid plexus tumours, it's important to note that outcomes can be adversely influenced by factors like young age, IV location, and high tumour vascularization,

irrespective of the histological grading.<sup>51-54</sup> SRS has proven beneficial for individuals dealing with small, deeply situated residual, and recurrent CPPs.<sup>55</sup>

Adjuvant radiation in paediatric patients with CPCs has been shown to improve survival in patients following STR, however, it is important to weigh the advantages of potential tumour control against the risks of delayed neurological consequences, especially in patients below the age of 3 years.<sup>56</sup> For individuals aged over 3 years and adults, the addition of adjuvant radiotherapy proves advantageous, particularly when craniospinal irradiation is indicated for cases involving drop metastases, leptomeningeal dissemination, and parenchymal infiltration. In the context of patients with CPCs where only STR was achieved, craniospinal radiation can contribute to improved overall survival (OS).<sup>56</sup>

## Chemotherapy

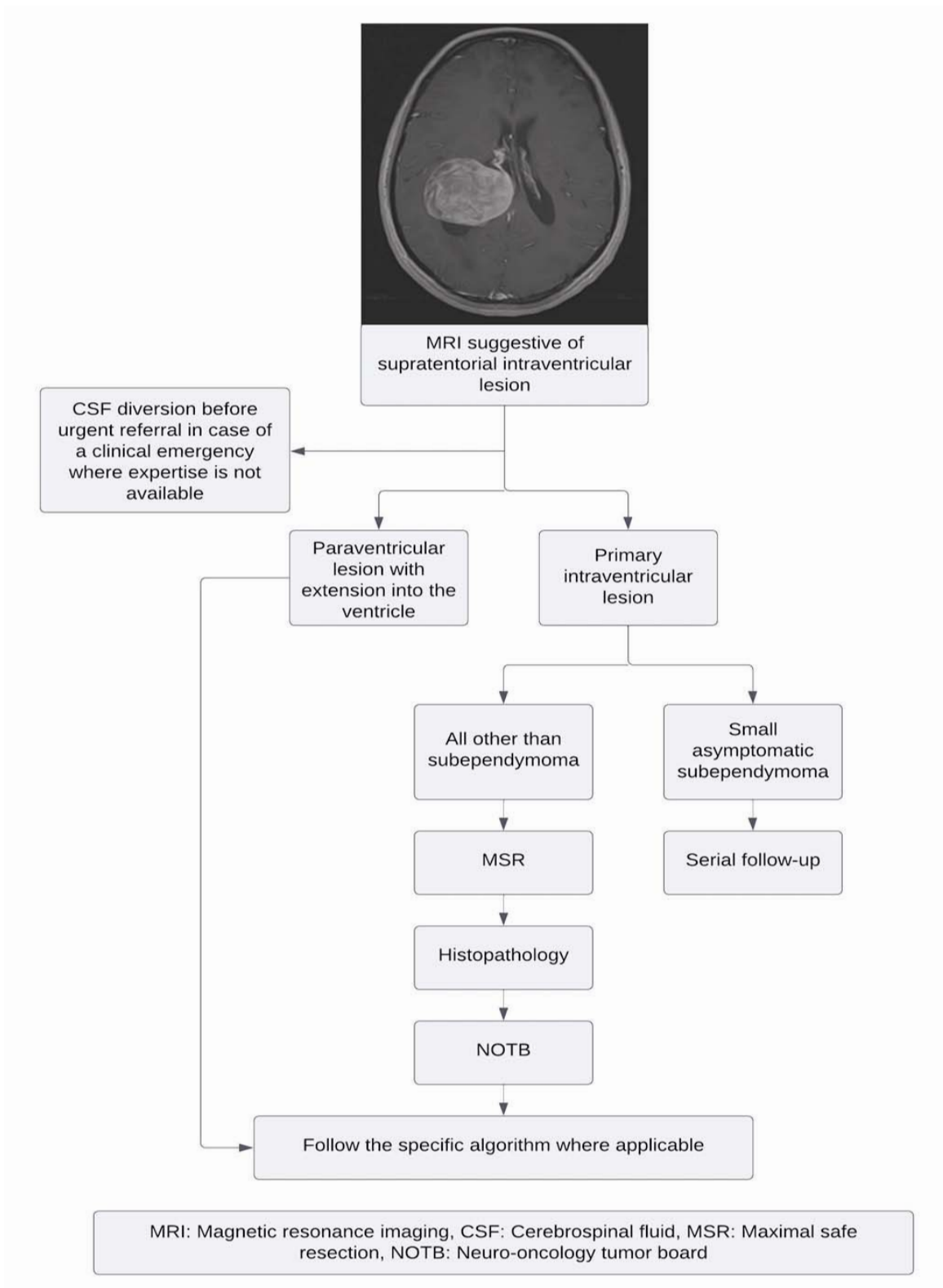
The definitive role of chemotherapy for ependymomas is under investigation and lack consensus guidelines for their use. Most of chemotherapeutic agents are very expensive and usually not easily available. Neuro-oncologists should undertake a detailed discussion with the patient or their caretakers regarding the possible duration, side effects, and cost before prescribing them.

mTOR pathways inhibitors (Everolimus) are effective in reducing SEGA volume and seizures, thus are offered especially for small and asymptomatic, or unresectable tumours.<sup>57-68</sup> In Central neurocytomas, few case studies have discussed chemotherapy as adjunctive therapy to surgery and radiation. Numerous chemotherapeutic agents, such as etoposide, cisplatin, cyclophosphamide, topotecan, carboplatin, and ifosfamide, have been explored for their efficacy. However, there is a lack of consensus on the most effective combination of these agents.<sup>69, 70</sup> In choroid plexus tumours, adjuvant chemotherapy, while its application is restricted, has the potential to deter recurrence and extend overall survival in CPPs.<sup>71, 72</sup>

## Follow-up and prognosis

EOR is the single most important predictor of prognosis and is confirmed by the postoperative MRI scan. Routine surveillance neuroimaging and close clinical follow-up are required in all cases, with shorter intervals between scans in cases of patients with STR undergoing radio- or chemotherapy. In LMICs after an initial post-operative MRI, the subsequent imaging may be with CT scans.

Supratentorial ependymomas have 5- and 10-year OS rates of about 57.1% ± 8.7% and 41.8% ± 9.9%, respectively. The 5- and 10-year PFS rates are about 33.8%



**Figure-1:** Management of Supratentorial Intraventricular Tumour algorithm.

**Table-1:** Summary of Recommendations for Supratentorial Intraventricular Neoplastic Lesion.

<b>Radiology</b>	<ul style="list-style-type: none"> <li>• MRI brain with and without contrast.</li> <li>• 'Minimum required' MRI protocol:               <ul style="list-style-type: none"> <li>o Imaging on at least 0.5T.</li> <li>o Sequences: Axial T2 and coronal or axial FLAIR sequence; pre-contrast T1 and contrast enhanced T1.</li> </ul> </li> <li>• Tumour location, size, margins, enhancement pattern, presence of hydrocephalous, hemorrhage/mineralization.</li> <li>• Postoperative MRI is recommended and tailored to each pathology. For high it is recommended within 72 hours of surgery or after 6 weeks if delayed. For low-grade tumours, after 3 months.               <ul style="list-style-type: none"> <li>o To identify the extent of resection.</li> <li>o To have a baseline to compare successive imaging.</li> <li>o Not required after biopsy.</li> </ul> </li> </ul>
<b>Neurosurgery</b>	<ul style="list-style-type: none"> <li>• CSF diversion before urgent referral in case of a clinical emergency where expertise is not available.</li> <li>• Maximal safe resection with preservation of critical neurovascular structures.</li> <li>• Intra-op EVD at the end of surgery is recommended.</li> </ul>
<b>Neuropathology</b>	<ul style="list-style-type: none"> <li>• Haematoxylin and eosin (H&amp;E) preparation for histological typing.</li> <li>• Relevant immunohistochemical stains for definite characterization based on the histology of the tumour.</li> </ul>
<b>Medical and Radiation Oncology</b>	<ul style="list-style-type: none"> <li>• Tailored approach for each pathology after discussing in NOTB.</li> </ul>
<b>Follow-up</b>	<ul style="list-style-type: none"> <li>• First follow-up at post-op day 10 for wound assessment, stitch removal, discussion related to histopathology and NOTB recommendations.</li> <li>• Clinical follow-up with MRI tailored to histopathological diagnosis.</li> </ul>

MRI: Magnetic resonance imaging, FLAIR: Fluid-attenuated inversion recovery, CSF: Cerebrospinal fluid, EVD: Extraventricular drain, NOTB: Neuro-Oncology tumour board.

± 8.1% and 25.4 ± 8%, respectively. Ages younger than 55, greater EOR, and lower histologic grade are associated with improved OS and PFS.<sup>73</sup>

Subependymomas have an overall 5-year survival rate of about 89.2% and a recurrence rate of 1.3% (follow-up ranging from 15.3 to 120.0 months).<sup>11</sup> Age, tumour size, and postoperative radiation therapy are not predictors of prognosis.<sup>11</sup> Female gender, GTR, and location within ventricles or near the brainstem are associated with improved prognosis.<sup>74</sup>

Central Neurocytomas have a 2-year PFS of 75 %, tumour volume ≥30 cm<sup>3</sup>, STR, and a high mitotic count (≥3 per 10 high-power fields) are risk factors for recurrence.<sup>75, 76</sup>

CPPs have 1-, 5-, and 10-year OS rates of 92 ± 1.5%, 87 ± 1.9%, and 82 ± 2.7%, respectively.<sup>77</sup> The OS can increase to 100% in patients with complete resection.<sup>78</sup> Following STR, 50% of CPP patients may require a subsequent resection for recurrence.<sup>79</sup> Increased mitotic activity is the sole atypical histological characteristic that is distinctly linked to recurrence. <sup>79</sup> CPC has OS of 51 ± 3%, 34 ± 4%, and 25 ± 4% after 1, 2, 5, and 10 years respectively. <sup>78</sup> GTR and adjuvant radiotherapy are associated with better prognosis in CPC, whereas chemotherapy can improve outcomes in both STR and non-irradiated tumours. <sup>78</sup>

## Conclusion

Designed to aid healthcare professionals working in regions with constrained resources, these recommendations provide a pragmatic structure drawn from valuable observations (see Table 1 and Figure 1). Implementing these recommendations has the significant potential to improve particular results and promote increased emphasis on cooperative healthcare in low- and middle-income countries (LMICs), such as Pakistan.

**Disclaimer:** None.

**Conflict of Interest:** None.

**Funding Disclosure:** None.

## References

1. Chong AW, McAdory LE, Low DCY, Lim EJ, Leong NWL, Ho CL. Primary intraventricular tumors - Imaging characteristics, post-treatment changes and relapses. *Clin Imaging* 2022;82:38-52. doi: 10.1016/j.clinimag.2021.10.008.
2. Ostrom QT, Price M, Neff C, Cioffi G, Waite KA, Kruchko C, et al. CBTRUS Statistical Report: Primary Brain and Other Central Nervous System Tumors Diagnosed in the United States in 2015-2019. *Neuro Oncol* 2022;24:v1-9. doi: 10.1093/neuonc/noac202.
3. McDermott MW. Intraventricular meningiomas. *Neurosurg Clin N Am* 2003;14:559-69. doi: 10.1016/s1042-3680(03)00055-x.
4. Bajwa MH, Shah MM, Mustansir F, Gauhar F, Baig E, Zafar SN, et al. A Guideline On Guidelines – Neuro-Oncology Guideline Standards For Low And Middle-Income Countries. *J Pak Med Assoc* 2024;74(Suppl 3):s87-92. Doi: 10.47391/JPMA.S3.GNO-10.
5. Smith AB, Smirniotopoulos JG, Horkanyne-Szakaly I. From the radiologic pathology archives: intraventricular neoplasms: radiologic-pathologic correlation. *Radiographics* 2013;33:21-43. doi: 10.1148/rg.331125192.
6. Agarwal A, Kanekar S. Intraventricular Tumors. *Semin Ultrasound CT MR* 2016;37:150-8. doi: 10.1053/j.sult.2015.12.003.
7. Ragel BT, Osborn AG, Whang K, Townsend JJ, Jensen RL, Couldwell WT. Subependymomas: an analysis of clinical and imaging features. *Neurosurgery* 2006;58:881-90. doi: 10.1227/01.NEU.0000209928.04532.09.
8. Bi Z, Ren X, Zhang J, Jia W. Clinical, radiological, and pathological

- features in 43 cases of intracranial subependymoma. *J Neurosurg* 2015;122:49-60. doi: 10.3171/2014.9.JNS14155.
9. Yuh EL, Barkovich AJ, Gupta N. Imaging of ependymomas: MRI and CT. *Childs Nerv Syst* 2009;25:1203-13. doi: 10.1007/s00381-009-0878-7.
  10. Mangalore S, Aryan S, Prasad C, Santosh V. Imaging characteristics of supratentorial ependymomas: Study on a large single institutional cohort with histopathological correlation. *Asian J Neurosurg* 2015;10:276-81. doi: 10.4103/1793-5482.162702.
  11. Kweh BTS, Rosenfeld JV, Hunn M, Tee JW. Tumor characteristics and surgical outcomes of intracranial subependymomas: a systematic review and meta-analysis. *J Neurosurg* 2021;136:736-48. doi: 10.3171/2021.2.JNS204052.
  12. Yang I. Central Neurocytomas. In: Kim DG, Yang I, eds. *Neurosurgery Clinics of North America*, 1st ed. Amsterdam, Netherlands: Elsevier Inc, 2015; pp 161. doi: 10.1016/S1042-3680(14)00128-4
  13. Kocaoglu M, Ors F, Bulakbasi N, Onguru O, Ulutin C, Secer HI. Central neurocytoma: proton MR spectroscopy and diffusion weighted MR imaging findings. *Magn Reson Imaging* 2009;27:434-40. doi: 10.1016/j.mri.2008.07.012.
  14. Jaiswal S, Vij M, Mehrotra A, Kumar B, Nair A, Jaiswal AK, et al. Choroid plexus tumors: A clinico-pathological and neuro-radiological study of 23 cases. *Asian J Neurosurg* 2013;8:29-35. doi: 10.4103/1793-5482.110277.
  15. Kornienko VN, Pronin IN. *Diagnostic Neuroradiology*. Moscow, Russia: Springer-Verlag Berlin Heidelberg, 2008; pp 1295. Doi: 10.1007/978-3-540-75653-8.
  16. Bhatoe HS, Singh P, Dutta V. Intraventricular meningiomas: a clinicopathological study and review. *Neurosurg Focus* 2006;20:E9. doi: 10.3171/foc.2006.20.3.10.
  17. Pereira BJA, de Almeida AN, Paiva WS, de Aguiar PHP, Teixeira MJ, Marie SKN. Natural history of intraventricular meningiomas: systematic review. *Neurosurg Rev* 2020;43:513-2. doi: 10.1007/s10143-018-1019-0.
  18. Lapras C, Deruty R, Bret P. Tumors of the lateral ventricles. *Adv Tech Stand Neurosurg* 1984;11:103-67. doi: 10.1007/978-3-7091-7015-1\_5.
  19. Fenchel M, Beschoner R, Naegele T, Korn A, Ernemann U, Horger M. Primarily solid intraventricular brain tumors. *Eur J Radiol* 2012;81:e688-96. doi: 10.1016/j.ejrad.2011.06.046.
  20. Shogan P, Banks KP, Brown S. AJR teaching file: Intraventricular mass. *AJR Am J Roentgenol* 2007;189 (Suppl 6):s55-7. doi: 10.2214/AJR.07.7027.
  21. de Castro FD, Reis F, Guerra JG. Intraventricular mass lesions at magnetic resonance imaging: iconographic essay - part 1. *Radiol Bras* 2014;47:176-81. doi: 10.1590/0100-3984.2013.1696.
  22. Louis DN, Perry A, Wesseling P, Brat DJ, Cree IA, Figarella-Branger D, et al. The 2021 WHO Classification of Tumors of the Central Nervous System: a summary. *Neuro Oncol* 2021;23:1231-5. doi: 10.1093/neuonc/noab106.
  23. Bertero L, Ricci AA, Tampieri C, Cassoni P, Modena P. Ependymomas. *Pathologica* 2022;114:436-46. doi: 10.32074/1591-951X-817.
  24. WHO Classification of Tumours Editorial Board. *Central Nervous System Tumours: WHO Classification of Tumours, 5th ed.* [Online] 2021 [Cited 2022 June 20]. Available from URL: <https://publications.iarc.fr/Book-And-Report-Series/Who-Classification-Of-Tumours/Central-Nervous-System-Tumours-2021>
  25. Toescu SM, Aquilina K. Current and Emerging Methods of Management of Ependymoma. *Curr Oncol Rep* 2019;21:78. doi: 10.1007/s11912-019-0826-y.
  26. Vigo V, Monroy-Sosa A, Rodriguez-Rubio R. Surgical Treatment of Intraventricular Tumors. In: Monroy-Sosa A, Chakravarthy SS, de la Garza-Salazar JG, Meneses Garcia A, Kassam AB, eds. *Principles of Neuro-Oncology*. Cham, Switzerland: Nature Switzerland AG; 2021. doi: 10.1007/978-3-030-54879-7\_28
  27. Yaşargil MG, Abdulrauf SI. Surgery of intraventricular tumors. *Neurosurgery* 2008;62:1029-40. doi: 10.1227/01.neu.0000333768.12951.9a.
  28. Anderson RC, Ghatan S, Feldstein NA. Surgical approaches to tumors of the lateral ventricle. *Neurosurg Clin N Am* 2003;14:509-25. doi: 10.1016/s1042-3680(03)00054-8.
  29. Mussi AC, Matushita H, Andrade FG, Rhoton AL. Surgical approaches to IV ventricle--anatomical study. *Childs Nerv Syst* 2015;31:1807-14. doi: 10.1007/s00381-015-2809-0.
  30. Schroeder HW. Intraventricular tumors. *World Neurosurg* 2013;79:S17.e15-9. doi: 10.1016/j.wneu.2012.02.023.
  31. Barber SM, Rangel-Castilla L, Baskin D. Neuroendoscopic resection of intraventricular tumors: a systematic outcomes analysis. *Minim Invasive Surg* 2013;2013:e898753. doi: 10.1155/2013/898753.
  32. Gaab MR, Schroeder HW. Neuroendoscopic approach to intraventricular lesions. *Neurosurg Focus* 1999;6:e5.
  33. Souweidane MM, Luther N. Endoscopic resection of solid intraventricular brain tumors. *J Neurosurg* 2006;105:271-8. doi: 10.3171/jns.2006.105.2.271.
  34. Reni M, Brandes AA, Vavassori V, Cavallo G, Casagrande F, Vastola F, et al. A multicenter study of the prognosis and treatment of adult brain ependymal tumors. *Cancer* 2004;100:1221-9. doi: 10.1002/cncr.20074.
  35. Metellus P, Barrie M, Figarella-Branger D, Chinot O, Giorgi R, Gouvernet J, et al. Multicentric French study on adult intracranial ependymomas: prognostic factors analysis and therapeutic considerations from a cohort of 152 patients. *Brain* 2007;130:1338-49. doi: 10.1093/brain/awm046.
  36. Massimino M, Solero CL, Garrè ML, Blassoni V, Cama A, Genitori L, et al. Second-look surgery for ependymoma: the Italian experience. *J Neurosurg Pediatr* 2011;8:246-50. doi: 10.3171/2011.6.PEDS1142.
  37. Kitchen WJ, Pizer B, Pettorini B, Husband D, Mallucci C, Jenkinson MD. Paediatric intracranial anaplastic ependymoma: the role of multiple surgical resections for disease relapse in maintaining quality of life and prolonged survival. *Pediatr Neurosurg* 2015;50:68-72. doi: 10.1159/000380856.
  38. Rudà R, Reifenberger G, Frappaz D, Pfister SM, Laprie A, Santarius T, et al. EANO guidelines for the diagnosis and treatment of ependymal tumors. *Neuro Oncol* 2018;20:445-56. doi: 10.1093/neuonc/nox166.
  39. Merchant TE, Boop FA, Kun LE, Sanford RA. A retrospective study of surgery and reirradiation for recurrent ependymoma. *Int J Radiat Oncol Biol Phys* 2008;71:87-9. doi: 10.1016/j.ijrobp.2007.09.037.
  40. Lombardi D, Scheithauer BW, Meyer FB, Forbes GS, Shaw EG, Gibney DJ, et al. Symptomatic subependymoma: a clinicopathological and flow cytometric study. *J Neurosurg* 1991;75:583-8. doi: 10.3171/jns.1991.75.4.0583.
  41. Ecker RD, Pollock BE. Recurrent subependymoma treated with radiosurgery. *Stereotact Funct Neurosurg* 2004;82:58-60. doi: 10.1159/000076662.
  42. Desai VR, Jensen AV, Hoverson E, Desai RM, Boghani Z, Lee MR. Stereotactic laser ablation for subependymal giant cell astrocytomas: personal experience and review of the literature. *Childs Nerv Syst* 2020;36:2685-91. doi: 10.1007/s00381-020-04638-y.
  43. Fayed I, Sacino MF, Gaillard WD, Keating RF, Oluigbo CO. MR-Guided Laser Interstitial Thermal Therapy for Medically Refractory Lesional Epilepsy in Pediatric Patients: Experience and Outcomes. *Pediatr Neurosurg* 2018;53:322-9. doi: 10.1159/000491823.
  44. Kane AJ, Sughrue ME, Rutkowski MJ, Aranda D, Mills SA, Lehil M, et

- al. Atypia predicting prognosis for intracranial extraventricular neurocytomas. *J Neurosurg* 2012;116:349-54. doi: 10.3171/2011.9.JNS10783.
45. Lubrano V, François P, Loundou A, Vasiljevic A, Roche PH. Outcomes after surgery for central neurocytoma: results of a French multicentre retrospective study. *Acta Neurochir (Wien)* 2013;155:1261-9. doi: 10.1007/s00701-013-1732-y.
  46. Rades D, Fehlaue F. Treatment options for central neurocytoma. *Neurology* 2002;59:1268-70. doi: 10.1212/wnl.59.8.1268.
  47. She L, Deng D, Su L, Liu C. Comparison of surgery with or without adjuvant radiotherapy in treating central neurocytoma: a single-center retrospective real-world study. *J Neurooncol* 2022;160:455-62. doi: 10.1007/s11060-022-04164-8.
  48. Chen YD, Li WB, Feng J, Qiu XG. Long-term outcomes of adjuvant radiotherapy after surgical resection of central neurocytoma. *Radiat Oncol* 2014;9:242. doi: 10.1186/s13014-014-0242-2.
  49. Mallick S, Benson R, Rath GK. Patterns of care and survival outcomes in patients with an extraventricular neurocytoma: An individual patient data analysis of 201 cases. *Neurol India* 2018;66:362-7. doi: 10.4103/0028-3886.227262.
  50. Patel DM, Schmidt RF, Liu JK. Update on the diagnosis, pathogenesis, and treatment strategies for central neurocytoma. *J Clin Neurosci* 2013;20:1193-9. doi: 10.1016/j.jocn.2013.01.001.
  51. Hosmann A, Hinker F, Dorfer C, Slavic I, Haberler C, Dieckmann K, et al. Management of choroid plexus tumors-an institutional experience. *Acta Neurochir (Wien)* 2019;161:745-54. doi: 10.1007/s00701-019-03832-5.
  52. McEvoy AW, Harding BN, Phipps KP, Ellison DW, Elsmore AJ, Thompson D, et al. Management of choroid plexus tumours in children: 20 years experience at a single neurosurgical centre. *Pediatr Neurosurg* 2000;32:192-9. doi: 10.1159/000028933.
  53. Siegfried A, Morin S, Munzer C, Delisle MB, Gambart M, Puget S, et al. A French retrospective study on clinical outcome in 102 choroid plexus tumors in children. *J Neurooncol* 2017;135:151-60. doi: 10.1007/s11060-017-2561-2.
  54. Koh EJ, Wang KC, Phi JH, Lee JY, Choi JW, Park SH, et al. Clinical outcome of pediatric choroid plexus tumors: retrospective analysis from a single institute. *Childs Nerv Syst* 2014;30:217-25. doi: 10.1007/s00381-013-2223-4.
  55. Kim IY, Niranjana A, Kondziolka D, Flickinger JC, Lunsford LD. Gamma knife radiosurgery for treatment resistant choroid plexus papillomas. *J Neurooncol* 2008;90:105-10. doi: 10.1007/s11060-008-9639-9.
  56. Sun MZ, Oh MC, Ivan ME, Kaur G, Safaee M, Kim JM, et al. Current management of choroid plexus carcinomas. *Neurosurg Rev* 2014;37:179-92. doi: 10.1007/s10143-013-0499-1.
  57. Jakacki RI, Foley MA, Horan J, Wang J, Kieran MW, Bowers DC, et al. Single-agent erlotinib versus oral etoposide in patients with recurrent or refractory pediatric ependymoma: a randomized open-label study. *J Neurooncol* 2016;129:131-8. doi: 10.1007/s11060-016-2155-4.
  58. Komori K, Yanagisawa R, Miyairi Y, Sakashita K, Shiohara M, Fujihara I, et al. Temozolomide Treatment for Pediatric Refractory Anaplastic Ependymoma with Low MGMT Protein Expression. *Pediatr Blood Cancer* 2016;63:152-5. doi: 10.1002/pbc.25696.
  59. Rudà R, Bruno F, Pellerino A, Soffietti R. Ependymoma: Evaluation and Management Updates. *Curr Oncol Rep* 2022;24:985-93. doi: 10.1007/s11912-022-01260-w.
  60. Giordano F, Moscheo C, Lenge M, Biagiotti R, Mari F, Sardi I, et al. Neurosurgical treatment of subependymal giant cell astrocytomas in tuberous sclerosis complex: a series of 44 surgical procedures in 31 patients. *Childs Nerv Syst* 2020;36:951-60. doi: 10.1007/s00381-019-04449-w.
  61. Di Rocco C, Iannelli A, Marchese E. On the treatment of subependymal giant cell astrocytomas and associated hydrocephalus in tuberous sclerosis. *Pediatr Neurosurg* 1995;23:115-21. doi: 10.1159/000120947.
  62. Ebrahimi-Fakhari D, Franz DN. Pharmacological treatment strategies for subependymal giant cell astrocytoma (SEGA). *Expert Opin Pharmacother* 2020;21:1329-36. doi: 10.1080/14656566.2020.1751124.
  63. Tomoto K, Fujimoto A, Inenaga C, Okanishi T, Imai S, Ogai M, et al. Experience using mTOR inhibitors for subependymal giant cell astrocytoma in tuberous sclerosis complex at a single facility. *BMC Neurol* 2021;21:139. doi: 10.1186/s12883-021-02160-5.
  64. Trelinska J, Dachowska I, Kotulska K, Baranska D, Fendler W, Jozwiak S, et al. Factors affecting response to everolimus therapy for subependymal giant cell astrocytomas associated with tuberous sclerosis. *Pediatr Blood Cancer* 2015;62:616-21. doi: 10.1002/pbc.25368.
  65. Gao C, Zabielska B, Jiao F, Mei D, Wang X, Kotulska K, et al. Subependymal Giant Cell Astrocytomas in Tuberous Sclerosis Complex-Current Views on Their Pathogenesis and Management. *J Clin Med* 2023;12:956. doi: 10.3390/jcm12030956.
  66. Franz DN, Belousova E, Sparagana S, Bebin EM, Frost M, Kuperman R, et al. Efficacy and safety of everolimus for subependymal giant cell astrocytomas associated with tuberous sclerosis complex (EXIST-1): a multicentre, randomised, placebo-controlled phase 3 trial. *Lancet* 2013;381:125-32. doi: 10.1016/S0140-6736(12)61134-9.
  67. Sadowski K, Kotulska K, Józwiak S. Management of side effects of mTOR inhibitors in tuberous sclerosis patients. *Pharmacol Rep* 2016;68:536-42. doi: 10.1016/j.pharep.2016.01.005.
  68. Frassanito P, Noya C, Tamburrini G. Current trends in the management of subependymal giant cell astrocytomas in tuberous sclerosis. *Childs Nerv Syst* 2020;36:2527-36. doi: 10.1007/s00381-020-04889-9.
  69. Buchbinder D, Danielpour M, Yong WH, Salamon N, Lasky J. Treatment of atypical central neurocytoma in a child with high dose chemotherapy and autologous stem cell rescue. *J Neurooncol* 2010;97:429-37. doi: 10.1007/s11060-009-0029-8.
  70. Brandes AA, Amistà P, Gardiman M, Volpin L, Danieli D, Guglielmi B, et al. Chemotherapy in patients with recurrent and progressive central neurocytoma. *Cancer* 2000;88:169-74. doi: 10.1002/(sici)1097-0142(20000101)88:1<169::aid-cnrc23>3.0.co;2-7.
  71. Turkoglu E, Kertmen H, Sanli AM, Onder E, Gunaydin A, Gurses L, et al. Clinical outcome of adult choroid plexus tumors: retrospective analysis of a single institute. *Acta Neurochir (Wien)* 2014;156:1461-8. doi: 10.1007/s00701-014-2138-1.
  72. Joseph JJ, M Das J. Choroid Plexus Papilloma. Treasure Island, FL: StatPearls Publishing; 2024.
  73. Metellus P, Figarella-Branger D, Guyotat J, Barrie M, Giorgi R, Jouve A, et al. Supratentorial ependymomas: prognostic factors and outcome analysis in a retrospective series of 46 adult patients. *Cancer* 2008;113:175-8. doi: 10.1002/cncr.23530.
  74. Nguyen HS, Doan N, Gelsomino M, Shabani S. Intracranial Subependymoma: A SEER Analysis 2004-2013. *World Neurosurg* 2017;101:599-605. doi: 10.1016/j.wneu.2017.02.019.
  75. Imber BS, Braunstein SE, Wu FY, Nabavizadeh N, Boehling N, Weinberg VK, et al. Clinical outcome and prognostic factors for central neurocytoma: twenty year institutional experience. *J Neurooncol* 2016;126:193-200. doi: 10.1007/s11060-015-1959-y.
  76. Vasiljevic A, François P, Loundou A, Fèvre-Montange M, Jouve A, Roche PH, et al. Prognostic factors in central neurocytomas: a multicenter study of 71 cases. *Am J Surg Pathol* 2012;36:220-7. doi: 10.1097/PAS.0b013e31823b8232.
  77. Colò F, Larrouquere L, Rivoirard R, Loiseau H, Mervoyer A, Lortholary A, et al. Bevacizumab in progressive disseminated atypical choroid plexus papilloma in adults. *Neuro Oncol*

- 2020;22:1046-7. doi: 10.1093/neuonc/noaa073.
78. Krishnan S, Brown PD, Scheithauer BW, Ebersold MJ, Hammack JE, Buckner JC. Choroid plexus papillomas: a single institutional experience. *J Neurooncol* 2004;68:49-55. doi: 10.1023/b:neon.0000024745.06073.07.
79. Jeibmann A, Hasselblatt M, Gerss J, Wrede B, Egensperger R, Beschorner R, et al. Prognostic implications of atypical histologic features in choroid plexus papilloma. *J Neuropathol Exp Neurol* 2006;65:1069-73. doi: 10.1097/01.jnen.0000240464.26005.90.
- 

**DISCLAIMER**

Articles published in JPMA and Supplements of JPMA do not represent the views of the editor or editorial Board. Authors are solely responsible for the opinions expressed and the accuracy of the data.

The contribution of each author towards the published research included in this supplement is the responsibility of the authors and their institutions. It is expected to be in accordance and compliance with the ICMJE Guidelines.

Any questions/queries raised by readers should be directed to the corresponding author.

## Judicious and evidence-based use of radiosurgery - recommendations for low-middle income countries

Syed Ather Enam<sup>1</sup>, Faiza Urooj<sup>2</sup>, Kaynat Siddiqui<sup>3</sup>, Mohammad Hamza Bajwa<sup>4</sup>, Hafiza Fatima Aziz<sup>5</sup>, Fatima Shaukat<sup>6</sup>, Muhammad Waqas Saeed Baqai<sup>7</sup>, Muhammad Shakir<sup>8</sup>, Ahsan Ali Khan<sup>9</sup>

**Pakistan Brain Tumour Consortium:** Authors list at the end of the supplement.

### Abstract

Surgical removal remains the primary treatment for most brain tumours. However, radiosurgery presents an effective, less invasive alternative or additional treatment for certain types. Our goal was to explore radiosurgery's roles in treating various brain tumours, focussing on its application in low- and middle-income countries (LMICs). We reviewed all relevant systematic reviews, meta-analyses, and guidelines to determine the most effective radiosurgical approaches. Additionally, we consulted a panel of experts with over ten years of experience in LMICs, such as Pakistan. For brain tumours, stereotactic radiosurgery should generally follow a confirmed histopathological diagnosis. Exceptions include tumours identified through Magnetic Resonance Imaging (MRI), like Vestibular Schwannoma (VS), pre-diagnosed Neurofibromatosis type 2 (NF2), multiple typical meningiomas, and metastases with a known histology from another site. While radiosurgery is gaining traction as a primary and adjunct treatment in some LMICs, the lack of regional guidelines, trained personnel, and collaboration among specialists hinders its wider adoption. Addressing these gaps is crucial for expanding radiosurgical care in these regions.

**Keywords:** Meningeal neoplasms, neurofibromatosis, neuroma, acoustic, meningioma,

Radiosurgery, brain neoplasms, magnetic resonance imaging, pituitary tumour, glioma, vestibular schwannoma.

**DOI:** <https://doi.org/10.47391/JPMA.S3.GNO-24>

### Introduction

Despite the progress in neuroimaging, advanced radiosurgery facilities, and microsurgical techniques in

<sup>1,3-5,7</sup>Department of Neurosurgery, The Aga Khan University, Karachi, Pakistan.

<sup>2</sup>The Aga Khan Medical College and University, Karachi, Pakistan. <sup>6</sup>CyberKnife and Tomotherapy Centre, Jinnah Post Graduate Medical Centre, Karachi, Pakistan. <sup>8-9</sup>Department of Neurosurgery, The Aga Khan University, Karachi, Pakistan.

**Correspondence:** Syed Ather Enam **Email:** [ather.enam@aku.edu](mailto:ather.enam@aku.edu)

recent decades, managing brain tumours remains a complex challenge. A multi-disciplinary, patient-centric approach is crucial. This approach involves collaboration between expert neurosurgeons, radiation and medical oncologists to improve outcomes such as local tumour control, progression-free and overall survival, minimal post-treatment complications, and enhanced quality of life. While surgical excision has been the standard for most primary brain tumours, stereotactic radiosurgery (SRS) using Gamma Knife (GK), CyberKnife (CK), or Linear Accelerator (LINAC) is increasingly favoured for specific tumours like pituitary adenomas (PA), vestibular schwannomas (VS), and gliomas (GM). Leksell's first SRS for VS in 1969 marked the beginning of evolving protocols for radiosurgery, now a preferred treatment for various brain tumours.<sup>1</sup>

SRS offers targeted cell death with submillimeter accuracy, reducing the impact on healthy brain tissue compared to conventional radiotherapy.<sup>2</sup> For PA, especially in cases of residual or recurrent tumours, or when surgical intervention is risky due to location or patient co-morbidities, SRS can be a primary treatment option.<sup>3</sup> Different radiosurgery types are tailored to specific tumour characteristics. However, potential complications like neurotoxicity, hearing loss, hypopituitarism, and cranial nerve deficits vary based on the tumour's type and location.<sup>4,5</sup> To mitigate these risks, recent studies have focussed on optimising fractionation, dosages, and target volumes for common brain tumours. The goal is to maximise efficacy while minimising post-SRS toxicity.<sup>6</sup> Continuous neuroimaging, vigilant monitoring, and long-term follow-up are vital for significant outcomes. International guidelines aim to standardise processes and minimise errors, ensuring more consistent and effective results.

In the Pakistan Brain Tumour Epidemiology Study (PBTES), among 2750 diagnosed brain tumour cases, the proportions of meningiomas, schwannomas, pituitary adenomas, and gliomas were 15.6%, 5.4%, 10%, and 28.4%, respectively.<sup>7-10</sup> Khalid MU et al. observed that out of 2750 cases, a significant percentage of 41.4% (n=1140)

lost to follow-up due to various reasons.<sup>11</sup> Moreover, a very small percentage of these cases went for adjuvant or primary radiation therapy.<sup>7-10</sup> Due to resource-limited settings, there is an all-encompassing dearth of trained staff, equipment, and capital, which greatly impacts the quality of care. Considering a different set of working dynamics and unique challenges concerning LMIC, the lack of consensus guidelines potentiates the gravity of the situation. We conducted a scoping review to summarise radiosurgery recommendations from systematic reviews, meta-analyses, and guidelines as a guide for practicable implementation in LMICs.

## Methods

A systematic search strategy comprising of a combination of search terms, ((guidelines) AND (radiosurgery)) [Mesh] OR (robotic radiosurgery) [Mesh] OR (stereotactic radiosurgery) [Mesh] OR (gammaknife) [Mesh] OR (cyberknife) [Mesh] OR (conventional radiosurgery) [Mesh] OR (fractionated radiosurgery)) [Mesh] AND ((brain tumours) [Mesh] OR (brain masses) [Mesh] OR (central nervous system tumours) OR (CNS tumours) OR (CNS malignancies) OR (intracranial tumours)) [Mesh] OR (brain malignancies) [Mesh] OR (pituitary tumour) [Mesh] OR (pituitary adenoma) [Mesh] OR (sellar tumour) [Mesh] OR (parasellar tumour) [Mesh] OR (acoustic neuroma) [Mesh] OR (vestibular schwannoma) [Mesh] OR (cerebellopontine angle lesion) [Mesh] OR (cerebellopontine angle tumour) [Mesh] OR (glioma) [Mesh] OR (oligodendroglioma) [Mesh] OR (astrocytoma) [Mesh] OR (medulloblastoma) [Mesh] OR (posterior fossa tumour) [Mesh] OR (glioblastoma) [Mesh] OR (brain mets) [Mesh] OR (brain metastasis) [Mesh] OR (secondary brain tumours))] AND ((LMIC OR low income country OR middle income country OR low to middle income country OR developing country)), and Boolean modifiers was applied on the PubMed (MEDLINE) database (Figure 1). Search was limited to studies published in English or with available English translations and selected guidelines, systematic reviews, and meta-analyses with specified recommendations for radiosurgery in brain tumour management. Single center studies, case series, case reports, opinion papers, and conference abstracts were excluded. In January 2023 Two reviewers independently screened the extracted database papers published till before December 2022 by titles and abstracts for eligibility. Full-text articles were obtained for those that matched the pre-specified criteria. Data were extracted from studies and categorised according to radiosurgery technology and tumour subtypes. We further discussed this review with experts from different expertise and backgrounds with more than ten years of experience in treating mainly brain tumours

and are regularly involved in neuro-oncology tumour board (NOTB) meetings in LMICs like Pakistan. Recommendations were summarised and tabulated.

## Results

A thorough literature review was undertaken and 372 articles related to radiosurgery guidelines for various brain tumours were identified. Following a detailed title and abstract evaluation conducted independently by two reviewers, 53 articles were shortlisted. One manuscript was inaccessible, and another was excluded for not being in English. Consequently, 21 articles were selected for this study after an in-depth full-text review (Figure 1). This review encompassed guidelines, systematic reviews, and meta-analyses, providing comprehensive recommendations for radiosurgery in different types of brain tumours. We meticulously analyzed 21 manuscripts, extracting and summarising the recommendations for skull base and meningiomas, pituitary adenomas, vestibular schwannomas, and gliomas shown in Tables 1 to 4. Furthermore, an implementation algorithm and summary of recommendations were developed, drawing on expert opinions from clinical specialists and the synthesized evidence (Table 5, Figure 2).

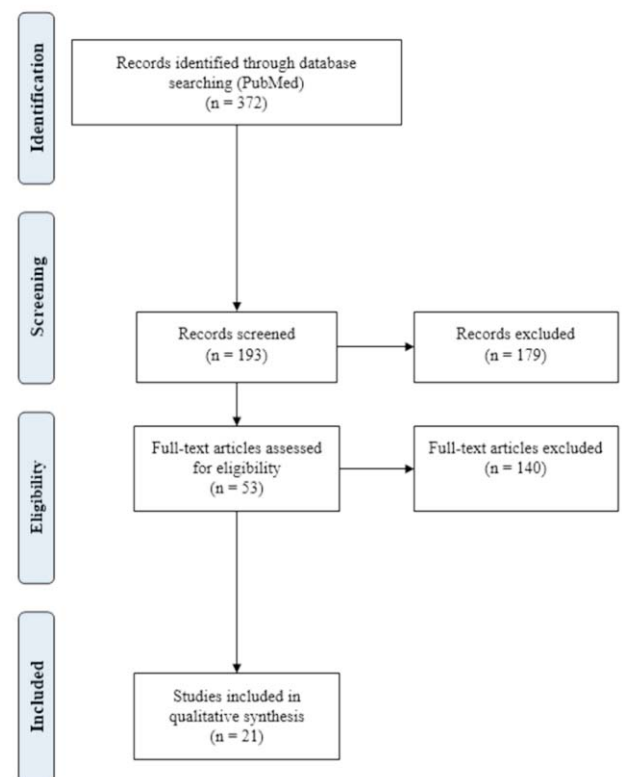


Figure-1: Workflow of Scoping Review.



**Table 1:** Skull Base Tumours and Meningiomas.

Author	Type of radiosurgery/ tumour	Recommendations
Minniti et al <sup>6</sup>	GK, LINAC, CK/skull base meningiomas	SRS is convenient, safe and has tumour control at 5 and 10 years comparable to fractionated radiotherapy (FRT). Both SRS and FSRT are effective for benign skull base meningiomas and the choice of stereotactic technique depends on tumour characteristics. SRS is reserved for tumours < 3 cm in size and > 3-5 mm away from the optic chiasm, whereas FSRT is employed for tumours not amenable to SRS. Reported toxicity of SRS is low when doses of 13-15 Gy are used. Although the risk of a second tumour after SRS is of concern. The maximum dose for optic chiasm is 8 Gy. the difference between tumour margin and optic apparatus should be 2-3mm to avoid visual deterioration.
Combs et al <sup>22</sup>	SRS, FSRT, IMRT/skull base tumours	For invasive frame-based SRS; 1–2 mm margin expansion is generally used and in patients receiving frameless SRS up to 3 mm. If IGRT techniques are not available, larger margins up to 5 mm should be employed. Single-fraction SRS, fractionated SRS (2–5 fractions) or conventionally fractionated SRT are commonly used, depending on tumour types, target volumes and involvement of critical structures. SRS doses of about 13–22 Gy in single fraction and 21–25 Gy in 3–5 fractions are typically utilized according to the different histology. Doses up to 74–76 Gy in 1.8–2.0 Gy fractions can be used for chordomas; lower doses for chondrosarcomas.
Combs et al <sup>23</sup>	Type of radiosurgery not specified/skull base meningioma	Independent of technique, radiosurgery approaches are comparable with respect to clinical outcome and toxicity. Radiosurgery is a safe alternative for skull-base meningioma, independent of location, however, limitations must be kept in mind with proximity to sensitive organs at risk as well as with increasing volumes. Thus, smaller volumes are preferred. Patients with asymptomatic lesion and typical imaging can be offered wait and scan policy with periodic neurological and radiological assessment. When the tumour reaches optimal size for irradiation, it can be ideal for radiosurgery/radiotherapy. If the tumour size reaches a resectable size, and patient prefers immediate treatment, surgery remains the best choice. However, in the lesions where treatment option via surgery or radiosurgery remains equivocal to each other, consider patient's preference. With the tumour invading critical areas. for example, cavernous sinus, radiosurgery remains a better choice.
Marchetti et al <sup>24</sup>	SRS and HSRT/meningioma (WHO grade 1)	SRS can be a primary treatment modality for an asymptomatic or mildly symptomatic meningioma and should be considered when a complete surgical excision is not possible. After surgery, when a residual tumour is not evident or is minimal, a wait-and-scan approach is reasonable with a regular radiological follow-up. At the time of recurrence or progression, SRS should be considered as a treatment modality. Recurrence/progression rate can be lower when SRS is delivered as the primary treatment as compared to adjuvant treatment. Single-fraction SRS with 12 to 15 Gy is sufficient to manage benign intracranial meningioma. A prescription dose of at least 14 Gy would be advisable. HSRT may be considered for the treatment of large or/and critically located meningioma. Optimal practice has yet to be defined; however, 25 Gy in 5 fractions is a common approach. SRS has a low risk of neurological deterioration and can lead to clinical improvement without tumour shrinkage.
Lee et al <sup>25</sup>	SRS (GK and LINAC)/cavernous sinus (CS) meningioma	SRS/SRT is recommended as a primary treatment option for an asymptomatic, or mildly symptomatic CS meningioma. The recurrence rate is not appreciably different between primary or adjuvant therapy for a CS meningioma and resection should be considered for the treatment of larger and symptomatic CS meningioma in patients for open surgery. CS meningioma treated with SRS/SRT have lower risk of complications. When no residual tumour is observed, or only a small tumour lining on the dura of the CS exists postoperatively, serial neuroimaging studies can be done. SRS/SRT should be considered for recurrence or

Continued on next page...

Continued from previous page...

		progression. For rapidly and substantially recurring tumours, after prior treatment, a subtotal surgical resection or biopsy may be considered. More aggressive features of the tumour should be ruled out. These tumours tend to progression and postoperative SRS/SRT with a higher dose is recommended. Technique for SRS or SRT delivery depends on tumour histology, volume and proximity to adjacent critical structures. SRS using single session marginal doses of 11 to 16 Gy offers a local tumour control rate of 90% or higher at 5 yr post-SRS.
Corniola et al <sup>26</sup>	SRS/cavernous sinus meningioma	SRS, SRT, or f-SRT, have similar rates of tumour control and improvement of pre-existing CN deficits as open surgery. The tumour control rate after SRS/RT using a median margin dose to the lesion of 13–15 Gy is up to 95%. SRS or SRT (either single-dose or fractionated) should be considered in the following cases, insofar as the distance to the ON is superior to 3 mm:- Asymptomatic, > 40 years old patients with a purely intracavernous CSMs <2.5 cm showing growth on serial imaging after initial conservative treatment- Asymptomatic patients with partly extracavernous CSMs showing growth on serial imaging after initial conservative treatment- Symptomatic patients with CSMs <2.5 cm, given that the symptoms are not related to optic nerve (ON) compression- Symptomatic patients with partly extracavernous CSMs in whom surgery is contraindicated. Fractionated RT should be considered in cases that require treatment if the distance to the ON is < 3 mm and ipsilateral visual function is good.

**Table-2:** Pituitary Adenomas.

Author	Type of radiosurgery/ tumour	Recommendations
Sheehan et al <sup>27</sup>	SRS/Non- Functional Pituitary Adenoma (NFPA)	Radiation therapy, including radiosurgery, is recommended to treat residual or recurrent NFPA for lowering the risk of tumour progression. Radiosurgery with single-session doses of 12 Gy or radiation therapy with fractionated doses of 45 to 54 Gy is recommended for a greater local tumour control rate of 90% at 5 years after treatment.
Heringer et al <sup>5</sup>	SRS/Pituitary Adenoma	SRS is recommended as a treatment for residual or relapsed pituitary tumours due to fewer side effects. The severity of a relapsed tumour in this meta-analysis revealed that at a mean marginal dose of 19.6 Gy, SRS was associated with a better tumour control rate (95%) and hormonal control rate (67%). However, hypopituitarism and visual deterioration were the two main post-SRS complications encountered.
Mathieu et al <sup>13</sup>	SRS/Secretory Pituitary Adenoma	Dose of SRS should safely protect surrounding structures (optic pathways, brainstem); higher margin doses can be used. Withdrawal of antiseecretory medications is preferred, typically for 4–12 weeks prior to radiosurgery, if safely possible considering endocrinologic status of patient. Timing of temporary cessation of medications and their reinstatement should be based on pharmacology of medication and patient's ability to tolerate brief withdrawal of medical management. SRS can be used as a primary therapy for medically unfit for surgical resection and as an alternative to surgical resection for medically refractory prolactinomas.
Gupta et al <sup>28</sup>	SRS/Pituitary adenoma	SRS is usually reserved for small adenomas (typically <2–3 cm) which are well defined and are located away from the optic chiasm ( $\geq 3$ mm). Medical management should be withheld temporarily prior to SRS/RT in functioning/secretory adenomas. The recommended dose of SRS given in a single fraction is 12–14Gy for nonfunctioning adenomas and 16–20Gy for secretory tumours. Late toxicity of pituitary RT includes hypopituitarism, neurocognitive impairment, neuropsychological dysfunction, optic neuropathy, cerebrovascular accidents, and second malignant neoplasms. Hence, RT in pituitary adenoma should be offered only to patients with residual, recurrent, progressive, or high-risk tumours with careful assessment of the benefit-risk ratio by an experienced multidisciplinary neuro-oncology team.

Continued on next page...

## Continued from previous page...

Lucas et al <sup>29</sup>	Type of radiosurgery not specified/Non-Functioning Pituitary Adenoma	Surgical resection is recommended as the primary treatment of symptomatic patients with NFPA. Limited class III evidence showed inconsistent benefits for observation alone, primary radiation-based treatment, or primary medical treatment (8 studies) for improving vision, headaches, hypopituitarism, or tumour volume for symptomatic NFPAs. There was insufficient evidence to make a recommendation regarding the primary treatment strategy for asymptomatic lesions.
---------------------------	--	--

**Table 3:** Vestibular Schwannomas.

Author	Type of radiosurgery/tumour	Recommendations
Kondziolka et al <sup>16</sup>	SRS mainly GK/ Vestibular Schwannoma (VS)	They suggested that in the absence of clinical symptoms of mass effect, newly diagnosed VS can be treated primarily with GKSRS, that in 98% of the cases do not require further treatment and as compared to surgery has similar or even better outcomes. Moreover, hearing is preserved in max 85% of such cases. However, wait and scan policy with no treatment is reserved for patients with medical co-morbidities and treating with SRS outweighed risk over benefit in the next 5 years. Matched cohort studies show that radiosurgery has either better or similar outcomes to resection, depending on the outcome measured.
Rotter et al <sup>30</sup>	SRS/Facial nerve schwannoma(FNS)	Unfavourable facial nerve function outcomes are associated with surgical treatment of intracranial FNS, whereas stable facial nerve function outcomes are associated with SRS. Therefore, SRS should be recommended to patients with FNS who require treatment, and surgery should be reserved for patients with another indication, such as decompression of the brainstem. Treatment-related morbidity, and complications are almost universally lower following radiosurgery.
Germano et al <sup>31</sup>	SRS/Vestibular schwannoma	For intracanalicular vestibular schwannomas and small tumours (<2 cm) without tinnitus can there is no negative impact on tumour growth or hearing preservation compared to non-radiosurgical treatment. There is no difference in radiographic control using different doses, it is recommended that for single fraction SRS doses, <13 Gy be used to facilitate hearing preservation and minimize new onset or worsening of preexisting cranial nerve deficits. Follow-up imaging should be obtained at intervals after SRS based on clinical indications, a patient's personal circumstances, or institutional protocols. Long-term surveillance with serial magnetic resonance imaging to look for recurrence is advised. SRS can be safely and effectively employed for retreatment in case of the progression of tumour after SRS. There is minimal risk of malignant transformation of vestibular schwannomas after SRS. Radiosurgery is a treatment option for patients with neurofibromatosis type 2 who's VS are enlarging and/or causing hearing loss.
Carlson et al <sup>32</sup>	SRS/Vestibular schwannoma	Greatest risk to hearing occurs with surgery, but if the hearing ability is initially preserved, the results tend to be durable. The risk of hearing loss increases with time during conservative management. The two strongest prognostic factors for the development of non-serviceable hearing are tumour growth and poorer hearing at the beginning of observation.
Starnoni et al <sup>17</sup>	SRS/Vestibular schwannoma	A combined approach of STR followed by SRS was shown to have excellent clinical and functional outcomes while still achieving a tumour control rate comparable to that obtained with a total resection. Longer-term follow-up and larger patient cohorts are necessary to fully evaluate the rate of tumour control achieved with this approach. Our pooled preserved serviceable hearing rate of 59.9% after the combined STR/SRS approach used for large VSs

**Discussion**

Stereotactic radiosurgery is a newer technique preferred over conventional radiation, delivering a large dose of

highly focused radiation to the target with sub-millimeter accuracy. This is achieved while sparing surrounding structures, thanks to stereotactic image guidance.<sup>2</sup>

**Table 4:** Gliomas, including GBM.

Author	Type of radiosurgery/tumour	Recommendations
Tsao et al. <sup>33</sup>	SRS or FSRT (boost after surgery and external beam radiotherapy)/High Grade Glioma	Use of radiosurgery boost followed by external beam radiotherapy and BCNU does not confer benefit in terms of overall survival, local brain control, or quality of life as compared with external beam radiotherapy and BCNU. The use of radiosurgery boost is associated with increased toxicity. For malignant gliomas, there is evidence regarding the benefits/harms of using radiosurgery at the time of progression or recurrence. There is insufficient evidence regarding the benefits/harms in the use of stereotactic fractionated radiation therapy for patients with newly diagnosed or progressive/recurrent malignant glioma.
Ziu et al. <sup>34</sup>	CRT, FSRS, SRS/ Progressive and recurrent GBM	Given the complex clinical nature of patients with progressive GBM, multidisciplinary assessment is vital to effective patient management. This paper has concluded class III evidence that re-irradiation can achieve tumour control, and improve PFS, neurological and functional status in <b>selected group of patients</b> . Prospective trials are required to systematically determine the advantage of re-irradiation
Ziu et al. <sup>19</sup>	SRS/Newly diagnosed GBM	RT is important for treatment of GBM with the standard dose of 60 Gy fractionated in 2 Gy per day for 5 days a week. SRS boost to external beam RT has not been shown to be beneficial and is not recommended in patients undergoing routine management of newly diagnosed malignant glioma.
Germano et al. <sup>18</sup>	SRS/Progressive GBM	Re irradiation can solely be used in elderly patients whereas, repeat cytoreductive surgery adds maximum survival benefit in patients with progressive glioblastoma.
Scoccianti et al. <sup>35</sup>	SRS/Recurrent GBM	Retreatment of recurrent glioma must be tailored to each single patient in order to have an acceptable risk of severe toxicity (< 3.5%). Prospective trials are required to further clarify the role of SRS or fractionated radiation in recurrent gliomas. Due to scarcity of literature, two local modalities i.e. redo surgery and re-radiation comparison is not available limiting the use of SRS in recurrent disease.

Radiosurgery is traditionally delivered in a single session but can be delivered in three or five sessions or fractions, to mitigate radiation-induced toxicity to the normal vital structures. There are several types of radiosurgeries, including the GK, LINAC-based, CK, or proton beam units.

Compared to traditional radiotherapy, stereotactic procedures offer a more localised radiation dose, potentially reducing the risk of long-term radiation-induced morbidity. SRS lowers the dangers associated with open surgical procedures, maintains cranial nerve function in most patients, and halts the progression of tumours. Larger tumours may be effectively managed with adjuvant gamma knife radiosurgery for long-term tumour growth control.<sup>12</sup> To reduce the long-term late effects of radiation, proton irradiation could be considered for younger individuals or patients with large and complex-shaped tumours, such as extensive meningiomas. However, proton beam therapy is not widely available globally.

Skull base tumours are operated using advanced techniques derived from a comprehensive understanding of the challenging skull base anatomy. Yet, total resection of these tumours can often be difficult, with significant risks related to critical neurovascular structures, especially

in areas such as the cavernous sinus, the petrous apex, and the jugular bulb.<sup>12</sup> For skull base tumours such as meningioma, radiation therapy is highly effective, with long-term statistics showing that after 10 years, over 80% of patients have tumour control with a manageable rate of sequelae.<sup>6</sup>

Our review shows that pituitary adenomas can be safely and maximally treated with SRS with results comparable to surgery. They can also be a primary treatment option in many tumours, provided the extension of the tumour does not invade critical surrounding areas. SRS has also been an established treatment option for residual or recurrent pituitary tumours with a significant tumour control rate, better clinical and hormonal outcomes, and progression-free survival.<sup>5</sup> Additionally, dose fractionation enables the safe delivery of radiation doses near critical areas without harming normal tissue. The usual recommended dose to the optic nerve varies from 8 Gy to 10 Gy, achievable safely through fractionation.<sup>13</sup> However, treatment with SRS requires planning with a CT scan, MRI brain with contrast, complete hormonal profile, and assessment of visual parameters.<sup>14</sup> Due to this extensive set of investigations, SRS remains a secondary treatment option in LMICs, where neuroimaging and basic medical investigations are scarce.

**Table 5:** Summary of radiosurgery recommendations for LMICs.

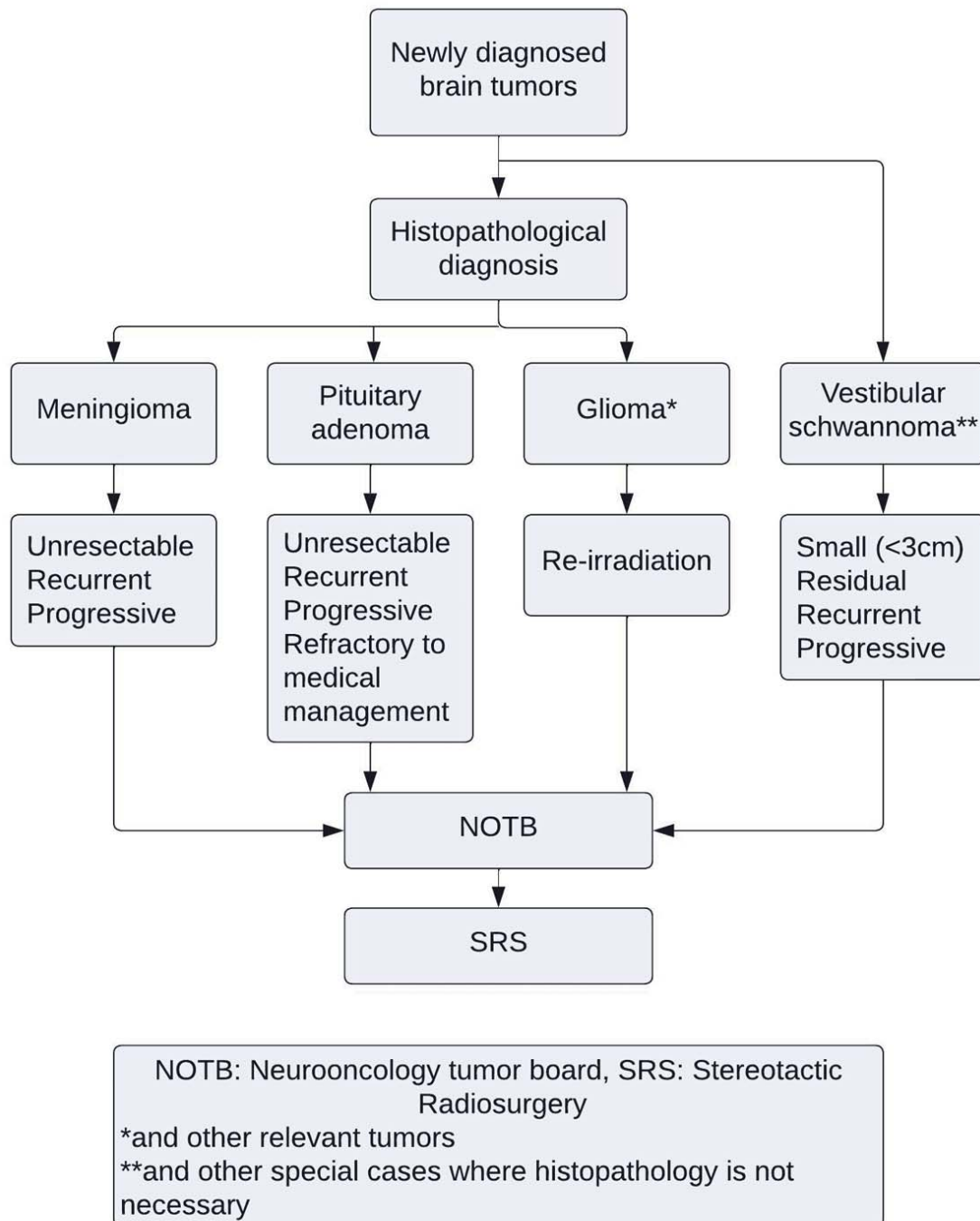
- Management of CNS tumours requires a multidisciplinary approach therefore decision for radiation therapy should be made by or in consultation with NOTB.
- Histopathological diagnosis is essential for decision making about specific treatment plans in cancer care therefore it is mandatory to take every measure to establish histological diagnosis before embarking on any treatment including radiation therapy. Upfront radiation therapy has no role in brain tumours except for a few cases. These include:
  1. small vestibular schwannoma (<3 cm)
  2. Typical shape of VS
  3. pre-diagnosed NF2
  4. multiple meningiomas
  5. metastasis with proven histology from some other site.
- Peer review of radiation treatment plans by site-specific specialists is an integral and essential component of quality assurance and should be a part of radiation therapy services to improve patient care.

Type of tumour	Recommendations
Meningioma	<ul style="list-style-type: none"> <li>• Standard of care is surgery as first line of treatment regardless of the grade, with mandatory histopathology.</li> <li>• SRS for skull base meningioma's can be used for recurrence or progression after proven histopathology if:               <ul style="list-style-type: none"> <li>o The tumour is invading critical areas such as cavernous sinus and complete surgical resection is not possible.</li> <li>o Tumour size is &lt;3 cm.</li> <li>o The difference between tumour margin and optic apparatus, brain stem or other sensitive areas is between 2-3 mm to avoid radiation toxicity.</li> </ul> </li> <li>• Single session marginal doses of 12-20 Gy depending on size &amp; grade.</li> <li>• Fractionated radiotherapy should be the treatment option when the distance between tumour and optic apparatus is &lt; 3mm and visual function is good.</li> </ul>
Pituitary adenoma	<ul style="list-style-type: none"> <li>• Surgery should be the first line of treatment for every symptomatic pituitary adenoma except prolactinomas (first line medical management).</li> <li>• SRS is second-line therapy for residual after surgery, unresectable, recurrence after surgery, or refractory to medical management.</li> <li>• The common dose of single fraction SRS is 12-14 Gy for non-functional adenomas and 16-25 Gy for functional adenomas.</li> <li>• Fractionated SRS dose is 25-30 Gy in 5 fractions.</li> <li>• Fractionated conventional radiation therapy is indicated if tumour &gt;3 cm or &lt;3-5 mm from chiasm due to risk of visual deficits.</li> </ul>
Vestibular schwannoma	<ul style="list-style-type: none"> <li>• SRS alone is appropriate for patients in whom the tumour is &lt;3 cm in size.</li> <li>• Single fraction SRS dose of &lt;13 Gy can help preserve hearing due to minimal toxicity.</li> <li>• For residual and recurrent VS, along with surgical resection, SRS single fraction or fractionated may be the safe alternative to surgery.</li> </ul>
Glioma & GBM	<ul style="list-style-type: none"> <li>• SRS is not recommended primarily for newly diagnosed malignant glioma.</li> <li>• Recommendations of SRS for gliomas:               <ul style="list-style-type: none"> <li>o First line of treatment: never</li> <li>o Adjuvant: no</li> <li>o Recurrence and &lt;3cm in size: yes</li> <li>o Recurrence and &gt;3cm in size: yes, but only after surgical resection of recurrence.</li> <li>o SRS is not recommended as first line of treatment or adjuvant therapy.</li> </ul> </li> <li>• SRS can be considered at recurrence along with CCRT.</li> <li>• Peer review treatment planning, previous radiation treatment details and current disease volume are essential components required for re-irradiation decision making process.</li> <li>• Standard doses to be decided by subject expertise.</li> </ul>

LMIC: Low-middle income countries, NOTB: Neuro-Oncology tumour board, VS: Vestibular schwannoma, NF2: Neurofibromatosis type 2, SRS: Stereotactic radiosurgery, Gy: Gray, 3DCRT: 3-dimensional conformal radiation therapy, IMRT: Intensity-modulated radiation therapy, VMAT: Volumetric modulated arc therapy, SRS: Stereotactic radiosurgery, SRT: Stereotactic radiotherapy, GBM: Glioblastoma multiforme, CCRT: Concurrent chemo radiation therapy.

In this scoping review, we observed that the treatment results of vestibular schwannomas with SRS are comparable to, if not better than, surgical resection for

smaller lesions. In their retrospective study, Tatagiba et al. analyzed the effectiveness of SRS and microsurgical resection for sporadic VS across two specialized



**Figure-2:** Management of brain tumours via radiosurgery algorithm.

neurosurgical centres, using data from 901 patients between 2005 and 2011.<sup>15</sup>

They employed the Koos classification, finding that microsurgery was more effective overall, particularly for larger tumours (Koos III and IV), with a lower recurrence rate, and better long-term control, compared to SRS. Both

treatments were similarly effective for smaller tumours (Koos I and II). Not all lesions require immediate surgical decompression and can be considered for primary treatment with SRS for serviceable hearing preservation if treated early.<sup>16</sup> VS, similar to Pituitary adenoma, requires a complete set of investigations for SRS planning and

treatment. Moreover, the longer follow-up along with the neuroimaging and investigations is absolutely necessary to compare the tumour and hearing control and achieve a tumour control rate comparable to gross total surgical resection.<sup>17</sup> However, this is a major concern in resource-limited settings and should be stressed to diagnose post-SRS radionecrosis and follow a better course of management.

Since gliomas are infiltrative lesions, safe surgical resection has always been the primary treatment for them. However, for progressive and recurrent GBMs, re-irradiation adds greater benefit in elderly patients, whereas cytoreductive surgery offers the maximum survival benefit in progressive glioblastoma, preserving neurological status and improving quality of life.<sup>18</sup> However, there has been no significant benefit of SRS for newly diagnosed malignant gliomas.<sup>19</sup> Moreover, re-irradiation and higher radio-surgical doses are associated with greater risks of radiation-induced toxicity.<sup>18</sup> A complete set of recommendations has been summarized in Table 4.

Our review shows that radiosurgery is a highly safe and effective method capable of treating a wide range of brain tumours. Although the technique is becoming more widely available globally, limited access to CNS imaging and insufficient treatment equipment restricts the availability of radiosurgery as a therapeutic option in various parts of the world.<sup>20</sup> Epidemiologic data on CNS cancers in low-income countries are scant and significantly less thorough than in more developed nations, thus underestimating the need for radiosurgery. In PBTES, it was observed that among the treatment-receiving group, only 14 patients with VS, 26 patients with PA, and 27 cases of gliomas received radiation therapy.<sup>8–10</sup> Moreover, PBTES identified meningioma as the second largest group of brain tumours found in Pakistan. Among those with the low-grade type (WHO grade 1), only a small percentage, 6.29% (n=27), received radiation therapy as part of their treatment.<sup>7</sup> This limited use may be attributed to the high financial burden, lack of proper knowledge, and increased waiting times at cost-effective centers.<sup>11</sup>

Moreover, it can be costly to construct ample radio-surgical centres, and properly trained staff is required to operate safely. Access to care is limited by socioeconomic and political dynamics.<sup>20</sup> There is a lack of procedures to implement novel medicines, and a failure to adhere to well-established international norms. The focus should be on developing and implementing adequate obligatory procedures to guarantee correct equipment use. LMICs and their healthcare facilities must adopt and deploy new

technology in a manner suitable for their institutions. Adhering to international protocols, which often require the infrastructure and resources of a HIC, can lead to higher costs and inefficient use of limited resources.<sup>21</sup>

## Conclusion

Radiosurgery has become a significant alternative to surgical intervention for various brain tumours, offering a noninvasive approach that circumvents the risks and expenses typically associated with traditional surgeries. This method is particularly valuable in LMICs due to its cost-effectiveness and reduced invasiveness. However, its application should be approached with caution and a full understanding of international standards rather than relying solely on anecdotal evidence. In most cases, a histopathological diagnosis is essential before employing radiosurgery to ensure accurate treatment planning, patient safety, and choosing the right adjuvant treatment based on histopathology. Despite its increasing use in some LMICs, there is a pressing need for structured training, patient-centric care, and education, coupled with a multidisciplinary team approach, to optimize the management of brain tumours. This comprehensive approach will enhance the effectiveness of radiosurgery and ensure it aligns with global best practices in oncological care.

**Disclaimer:** None.

**Conflict of Interest:** None.

**Funding Disclosure:** None.

## References

1. Lunsford LD. The development of the international stereotactic radiosurgery society. *J Radiosurg SBRT* 2011;1:77-83.
2. Bassim MK, Berliner KI, Fisher LM, Brackmann DE, Friedman RA. Radiation therapy for the treatment of vestibular schwannoma: a critical evaluation of the state of the literature. *Otol Neurotol* 2010;31:567-73. doi: 10.1097/MAO.0b013e3181d8d3ad.
3. Lee WJ, Cho KR, Choi JW, Kong DS, Seol HJ, Nam DH, et al. Gamma Knife Radiosurgery as a Primary Treatment for Nonfunctioning Pituitary Adenoma Invading the Cavernous Sinus. *Stereotact Funct Neurosurg* 2020;98:371-7. doi: 10.1159/000508737.
4. Soltys SG, Milano MT, Xue J, Tomé WA, Yorke E, Sheehan J, et al. Stereotactic Radiosurgery for Vestibular Schwannomas: Tumor Control Probability Analyses and Recommended Reporting Standards. *Int J Radiat Oncol Biol Phys* 2021;110:100-11. doi: 10.1016/j.ijrobp.2020.11.019.
5. Heringer LC, de Lima MM, Rotta JM, Botelho RV. Effect of stereotactic radiosurgery on residual or relapsed pituitary adenoma: a systematic review and meta-analysis. *World Neurosurg* 2020;136:374-81.e4. doi: 10.1016/j.wneu.2019.11.041.
6. Minniti G, Amichetti M, Enrici RM. Radiotherapy and radiosurgery for benign skull base meningiomas. *Radiat Oncol* 2009;4:42. doi: 10.1186/1748-717X-4-42.
7. Shah MM, Khalid MU, Bajwa MH, Bakhshi SK, Anis SB, Akhuzada NZ, et al. Meningioma - defining characteristics of the affected Pakistani population. *J Pak Med Assoc* 2022;72(Suppl 4):s51-6. doi: 10.47391/JPMA.11-S4-AKUB08.

8. Khalid MU, Shah MM, Bajwa MH, Nathani KR, Laghari AA, Raghieb MF, et al. Schwannoma: A surgical epidemiology. *J Pak Med Assoc* 2022;72(Suppl 4):s40-51. doi: 10.47391/JPMA.11-S4-AKUB06.
9. Shah MM, Bajwa MH, Khalid MU, Jooma R, Anis SB, Laghari AA, et al. Prioritizing Pituitary Adenoma Care in Pakistan: Analysis from an Epidemiological Study. *J Pak Med Assoc* 2022;72(Suppl 4):s56-60. doi: 10.47391/JPMA.11-S4-AKUB09.
10. Bajwa MH, Khalid MU, Shah MM, Shamim MS, Laghari AA, Akhunzada NZ, et al. Treatment patterns of glioma in Pakistan: An epidemiological perspective. *J Pak Med Assoc* 2022;72(Suppl 4):s34-9. doi: 10.47391/JPMA.11-S4-AKUB05.
11. Khalid MU, Bajwa MH, Shah MM, Zafar SN, Laghari AA, Akhunzada NZ, et al. Factors associated with lost to follow up in patients with brain tumours: A multi-centre study in Pakistan. *J Pak Med Assoc* 2022;72(Suppl 4):s16-24. doi: 10.47391/JPMA.11-S4-AKUB03.
12. Lunsford LD, Niranjan A, Martin JJ, Sirin S, Kassam A, Kondziolka D, et al. Radiosurgery for Miscellaneous Skull Base Tumors. In: Szeifert GT, Kondziolka D, Levivier M, Lunsford LD, eds. *Progress in Neurological Surgery: Radiosurgery and Pathological Fundamentals*. Basel, Switzerland: S. Karger AG, 2007; pp 192-205. doi: 10.1159/000100114
13. Mathieu D, Kotecha R, Sahgal A, De Salles A, Fariselli L, Pollock BE, et al. Stereotactic radiosurgery for secretory pituitary adenomas: systematic review and International Stereotactic Radiosurgery Society practice recommendations. *J Neurosurg* 2021;136:801-12. doi: 10.3171/2021.2.JNS204440.
14. Becker G, Kocher M, Kortmann RD, Paulsen F, Jeremic B, Müller, et al. Radiation therapy in the multimodal treatment approach of pituitary adenoma. *Strahlenther Onkol* 2002;178:173-86. doi: 10.1007/s00066-002-0826-x.
15. Tatagiba M, Wang SS, Rizk A, Ebner F, van Eck ATCJ, Naros G, et al. A comparative study of microsurgery and gamma knife radiosurgery in vestibular schwannoma evaluating tumor control and functional outcome. *Neurooncol Adv* 2023;5:vdad146. doi: 10.1093/noonadv/vdad146.
16. Kondziolka D, Mousavi SH, Kano H, Flickinger JC, Lunsford LD. The newly diagnosed vestibular schwannoma: radiosurgery, resection, or observation? *Neurosurg Focus* 2012;33:e8. doi: 10.3171/2012.6.FOCUS12192.
17. Starnoni D, Daniel RT, Tuleasca C, George M, Levivier M, Messerer M. Systematic review and meta-analysis of the technique of subtotal resection and stereotactic radiosurgery for large vestibular schwannomas: a "nerve-centered" approach. *Neurosurg Focus* 2018;44:E4. doi: 10.3171/2017.12.FOCUS17669.
18. Germano IM, Johnson DR, Patrick HH, Goodman AL, Ziu M, Ormond DR, et al. Congress of Neurological Surgeons Systematic Review and Evidence-Based Guidelines on the Management of Progressive Glioblastoma in Adults: Update of the 2014 Guidelines. *Neurosurgery* 2022;90:e112-5. doi: 10.1227/neu.000000000001903.
19. Ziu M, Kim BYS, Jiang W, Ryken T, Olson JJ. The role of radiation therapy in treatment of adults with newly diagnosed glioblastoma multiforme: a systematic review and evidence-based clinical practice guideline update. *J Neurooncol* 2020;150:215-67. doi: 10.1007/s11060-020-03612-7.
20. Pannullo SC, Julie DAR, Chidambaram S, Balogun OD, Formenti SC, Apuzzo MLJ, et al. Worldwide Access to Stereotactic Radiosurgery. *World Neurosurg* 2019;130:608-14. doi: 10.1016/j.wneu.2019.04.031.
21. Ochoa P, Puente-Vallejo R, Loza F, Cueva F, Leon-Rojas JE. Technological Improvements in Low- and Middle-Income Countries (LMICs): A Review of the Literature and the "Sociedad de Lucha Contra el Cáncer" (SOLCA) Institutional Experience in Neuro-Radiosurgery During the Coronavirus Disease 2019 (COVID-19) Pandemic. *World Neurosurg* 2022;162:91-7. doi: 10.1016/j.wneu.2022.04.035.
22. Combs SE, Baumert BG, Bendszus M, Bozzao A, Brada M, Fariselli L, et al. ESTRO ACROP guideline for target volume delineation of skull base tumors. *Radiother Oncol* 2021;156:80-94. doi: 10.1016/j.radonc.2020.11.014.
23. Combs SE, Ganswindt U, Foote RL, Kondziolka D, Tonn JC. State-of-the-art treatment alternatives for base of skull meningiomas: complementing and controversial indications for neurosurgery, stereotactic and robotic based radiosurgery or modern fractionated radiation techniques. *Radiat Oncol* 2012;7:226. doi: 10.1186/1748-717X-7-226.
24. Marchetti M, Sahgal A, De Salles AAF, Levivier M, Ma L, Paddick I, et al. Stereotactic Radiosurgery for Intracranial Noncavernous Sinus Benign Meningioma: International Stereotactic Radiosurgery Society Systematic Review, Meta-Analysis and Practice Guideline. *Neurosurgery* 2020;87:879-90. doi: 10.1093/neuros/nyaa169.
25. Lee CC, Trifiletti DM, Sahgal A, DeSalles A, Fariselli L, Hayashi M, et al. Stereotactic Radiosurgery for Benign (World Health Organization Grade I) Cavernous Sinus Meningiomas-International Stereotactic Radiosurgery Society (ISRS) Practice Guideline: A Systematic Review. *Neurosurgery* 2018;83:1128-42. doi: 10.1093/neuros/nyy009.
26. Corniola MV, Roche PH, Bruneau M, Cavallo LM, Daniel RT, Messerer M, et al. Management of cavernous sinus meningiomas: Consensus statement on behalf of the EANS skull base section. *Brain Spine* 2022;2:100864. doi: 10.1016/j.bas.2022.100864.
27. Sheehan J, Lee CC, Bodach ME, Tumialan LM, Oyesiku NM, Patil CG, et al. Congress of Neurological Surgeons Systematic Review and Evidence-Based Guideline for the Management of Patients With Residual or Recurrent Nonfunctioning Pituitary Adenomas. *Neurosurgery* 2016;79:e539-40. doi: 10.1227/NEU.0000000000001385.
28. Gupta T, Chatterjee A. Modern Radiation Therapy for Pituitary Adenoma: Review of Techniques and Outcomes. *Neurol India* 2020;68:s113-22. doi: 10.4103/0028-3886.287678.
29. Lucas JW, Bodach ME, Tumialan LM, Oyesiku NM, Patil CG, Litvack Z, et al. Congress of Neurological Surgeons Systematic Review and Evidence-Based Guideline on Primary Management of Patients With Nonfunctioning Pituitary Adenomas. *Neurosurgery* 2016;79:E533-5. doi: 10.1227/NEU.0000000000001389.
30. Rotter J, Lu VM, Graffeo CS, Perry A, Driscoll CLW, Pollock BE, et al. Surgery versus radiosurgery for facial nerve schwannoma: a systematic review and meta-analysis of facial nerve function, postoperative complications, and progression. *J Neurosurg* 2020. doi: 10.3171/2020.6.JNS201548. [ahead of print]
31. Germano IM, Sheehan J, Parish J, Atkins T, Asher A, Hadjipanayis CG, et al. Congress of Neurological Surgeons Systematic Review and Evidence-Based Guidelines on the Role of Radiosurgery and Radiation Therapy in the Management of Patients With Vestibular Schwannomas. *Neurosurgery* 2018;82:E49-51. doi: 10.1093/neuros/nyx515.
32. Carlson ML, Vivas EX, McCracken DJ, Sweeney AD, Neff BA, Shepard NT, et al. Congress of Neurological Surgeons Systematic Review and Evidence-Based Guidelines on Hearing Preservation Outcomes in Patients With Sporadic Vestibular Schwannomas. *Neurosurgery* 2018;82:E35-9. doi: 10.1093/neuros/nyx511.
33. Tsao MN, Mehta MP, Whelan TJ, Morris DE, Hayman JA, Flickinger JC, et al. The American Society for Therapeutic Radiology and Oncology (ASTRO) evidence-based review of the role of radiosurgery for malignant glioma. *Int J Radiat Oncol Biol Phys* 2005;63:47-55. doi: 10.1016/j.ijrobp.2005.05.024.
34. Ziu M, Goyal S, Olson JJ. Congress of Neurological Surgeons systematic review and evidence-based guidelines update on the role of radiation therapy in the management of progressive and



- recurrent glioblastoma in adults. *J Neurooncol* 2022;158:255-64. doi: 10.1007/s11060-021-03857-w.
35. Scozzianti S, Francolini G, Carta GA, Greto D, Detti B, Simontacchi G, et al. Re-irradiation as salvage treatment in recurrent

glioblastoma: A comprehensive literature review to provide practical answers to frequently asked questions. *Crit Rev Oncol Hematol* 2018;126:80-91. doi: 10.1016/j.critrevonc.2018.03.024.

---

**DISCLAIMER**

Articles published in JPMA and Supplements of JPMA do not represent the views of the editor or editorial Board. Authors are solely responsible for the opinions expressed and the accuracy of the data.

The contribution of each author towards the published research included in this supplement is the responsibility of the authors and their institutions. It is expected to be in accordance and compliance with the ICMJE Guidelines.

Any questions/queries raised by readers should be directed to the corresponding author.

# Pakistan Brain Tumor Consortium (PBTC)

Names	Affiliation
1. Muhammad Abbas Khokhar	King Edward Medical University, Lahore
2. Muhammad Tariq	Khyber Teaching Hospital, Peshawar
3. Saqib Kamran Bakhshi	Aga Khan University, Karachi
4. Adeeba Zaki	Aga Khan University, Karachi
5. Amjad Ali Qureshi	Pir Abdul Qadir Shah Jeelani Institute of Medical Sciences, Gambat
6. Muhammad Tariq Khan	Northwest School of Medicine, Peshawar
7. M Shahzad Shamim	Aga Khan University, Karachi
8. Farrukh Javeed	Jinnah Postgraduate Medical Centre, Karachi
9. Riaz Ahmed Raja Memon	Liaquat University of Medical & Health Sciences, Jamshoro
10. Ahsan Ali Khan	Aga Khan University, Karachi
11. Faiqa Filza	Northwest General Hospital & Research Centre, Peshawar
12. Manzoor Ahmad	Retired as Professor of Neurosurgery
13. Muhammad Abid Saleem	Dow University of Health Sciences, Karachi
14. Muhammad Arshad	Quaid-E-Azam Medical College / Bahawal Victoria Hospital, Bahawalpur
15. Ahmed Nadeem Abbasi	Aga Khan University, Karachi
16. Muhammad Nadeem	Shifa International Hospital, Islamabad
17. Naveed Ashraf	National Hospital & Medical Centre, Lahore
18. Nasir Raza Awan	Sharif Medical & Dental College, Lahore
19. Asghar Hussain Asghar	KIRAN Hospital, Karachi
20. Rashid Jooma	Aga Khan University, Karachi
21. Maqsood Akram	PNS Shifa Hospital, Karachi
22. Asif Bashir	Punjab Institute of Neurosciences, Lahore
23. Naqib Ullah Achakzai	Bolan Medical College / Bolan University of Medical & Health Sciences, Quetta
24. Shahid Ayub	Khyber Girls Medical College, Peshawar
25. Muhammad Asim Khan Rehmani	National Medical Centre, Karachi
26. Kamran Saeed	Jinnah Postgraduate Medical Center, Karachi
27. Naveed Zaman Akhunzada	Rehman Medical Institute, Peshawar
28. Abdul Sattar M. Hashim	Neurospinal and Cancer Care Institute, Karachi
29. Muhammad Mehboob Alam	POF Hospital, Wah Cantt
30. Shahzad Shams	King Edward Medical University, Lahore
31. Talha Abbas	Fatima Jinnah Medical University / Sir Ganga Ram Hospital, Lahore
32. Ahmed Ali Shah	Aga Khan University, Karachi
33. Muhammad Arshad	Quaid-e-Azam Medical College, Bahawalpur
34. Sumera Butt	Shaukat Khanum Memorial Cancer Hospital, Lahore
35. Zaeem Sultan	DHQ Hospital, Jhang
36. Syed Ahmer Hamid	Indus Hospital & Health Network, Karachi
37. Nadeem Akhtar	Rawalpindi Medical University, Rawalpindi
38. Bilal Khan	Lady Reading Hospital, Peshawar
39. Altaf Ali Laghari	Aga Khan University, Karachi
40. Muhammad Usman	PAF Hospital / Fazaia Medical College, Islamabad
41. Khalid Mahmood	Punjab Institute of Neurosciences, Lahore
42. Saad Akhtar Khan	Aga Khan University and Liaquat National Hospital, Karachi

# Pakistan Brain Tumor Consortium (PBTC)

<b>Names</b>	<b>Affiliation</b>
44. Naila A Zahid	Liaquat National Hospital, Karachi
45. Mazhar Ali Shah	Shaukat Khanum Memorial Cancer Hospital, Lahore
46. Irfan Yousaf	Shaukat Khanum Memorial Cancer Hospital, Lahore
47. Salman Sharif	Liaquat National Hospital, Karachi
48. Arif Jamshed	Shaukat Khanum Memorial Cancer Hospital, Lahore
49. Tariq Mahmood	Jinnah Postgraduate Medical Center, Karachi
50. Mumtaz Ali	Ali Institute of Neurosciences, affiliated with Gandhara Institute of Health Sciences, Peshawar
51. Saad Bin Anis	Shaukat Khanum Memorial Cancer Hospital, Lahore
52. Qurat ul Ain Tariq	Shaukat Khanum Memorial Cancer Hospital, Lahore
53. Yaseen Rauf	Patel Hospital, Karachi
54. Tahir Shahab	Pir Abdul Qadir Shah Jeelani Institute of Medical Sciences, Gambat
55. Bushra Ahmad	Provincial Head Quarter Hospital, Gilgit
56. Manzar Hussain	Liaquat National Hospital, Karachi
57. Syed Sarmad Bukhari	Northwest School of Medicine, Peshawar
58. Muhammad Atif Mansha	Dow University of Health Sciences, Karachi
59. Muhammad Shakir	Aga Khan University, Karachi
60. Muhammad Ehsan Bari	Aga Khan University, Karachi
61. Gohar Javed	Aga Khan University, Karachi
62. Asim Hafiz	Aga Khan University, Karachi
63. Faizuddin Najmuddin	Sheikh Khalifah Bin Zayyad Hospital, Quetta

---

LEADING THE RACE

In Epilepsy Management

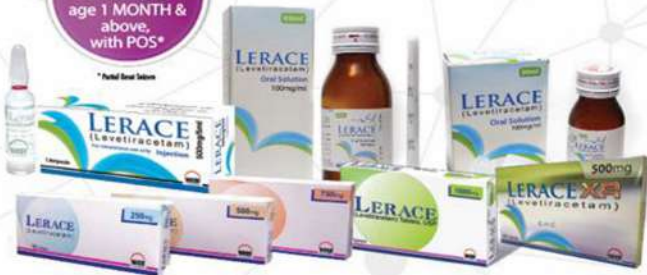# LERACE

**Levetiracetam** 250, 500, 750mg IR & 500mg XR Tablets,  
1000mg Tablets, 500mg/5ml I.V. Injection  
100mg/ml Oral Solution

FDA HAS APPROVED

In infants at  
age 1 MONTH &  
above,  
with POS\*

\*Partial Seizures



Filling  
the Gap  
In Epilepsy Management

# Brivace

(Brivaracetam) 10mg, 25mg, 50mg & 100mg



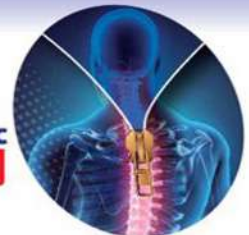Live  
Beyond  
Neuropathic  
Pain

# LACOLEP

**Lacosamide** 50, 100 & 150mg Tablets  
200mg/ 20ml I.V. Injection  
10mg/ml Oral Solution



ZIP  
the  
Neuropathic  
PAIN



# Zeegap

Pregabalin 25mg, 50mg, 75mg, 100mg  
& 150mg Capsules





A Promising Companion in

# NEUROPSYCHIATRY



**Xeticam**<sup>TM</sup>  
[Levetiracetam]  
250 mg, 500 mg, 750 mg Tabs | 100 mg/ml OS | 500mg/5ml Inj



**Dopacone**<sup>TM</sup>  
[Levodopa+Carbidopa+Entacapone]  
50mg+12.5mg+200mg | 75mg+18.75mg+200mg | 100mg+25mg+200mg  
150mg+37.5mg+300mg | 100mg+25.5mg+200mg | 200mg+50mg+200mg  
Tablets



**Lyta**<sup>TM</sup>  
(Duloxetine)  
20mg | 30mg | 60mg Capsules



**Gabica**<sup>TM</sup>  
(PREGABALIN)  
25mg | 50mg | 75mg | 100mg  
150mg | 300mg Capsules



**Voxver**<sup>TM</sup>  
[Vortioxetine]  
10mg | 20mg Tablets



**Zavget**<sup>TM</sup>  
(Escitalopram)  
5mg, 10mg & 20mg Tablets



**Olanzaget**<sup>TM</sup>  
[Olanzapine+Fluoxetine]  
3mg + 25mg, 6mg + 25mg, Capsules



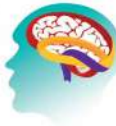**Risperiget**<sup>TM</sup>  
(Risperidone)  
1mg | 2mg | 3mg | 4mg Tablets

Getz Pharma's manufacturing facility is approved by member countries of Pharmaceutical Inspection Co-operation Scheme (PIC/S)

Follow us at:      [www.getzpharma.com](http://www.getzpharma.com)




**Vetrawin**<sup>®</sup>  
(Levetiracetam)



250mg & 500mg Tablets  
100mg/mL Oral Solution  
500mg/5mL IV Injection

**REGAB**<sup>®</sup>  
(Pregabalin)  
50mg 75mg 100mg Capsules

 **Ambalta**<sup>™</sup>  
(Duloxetine)  
20mg & 30mg Capsules

**Neoris**<sup>®</sup>  
(Risperidone)  
1mg, 2mg, 3mg & 4mg Tablets  
& 1mg/mL Oral Solution

**Fernor**<sup>®</sup>  
(Tizanidine)  
2mg Tablets & 6mg SR Tablets

**Amro**<sup>™</sup>  
(Rosuvastatin)  
5mg, 10mg & 20mg Tablets

**Cilosta**<sup>®</sup>  
(Cilostazol)  
100mg Tablets

 **Im-DZ**<sup>™</sup>  
(Methylcobalamin + Vitamin D3 + Zinc)

1500mcg/ 2000IU/ 11mg  
Tablets

